

Minimally invasive percutaneous endoscopic 2 levels adjacent lumbar discectomy through 1 portal skin incision: Preliminary study

Hyeun Sung Kim, Chang Il Ju¹, Seok Won Kim¹, Jong Gyue Kim¹, Seung Myung Lee¹, Byoung Wook Kim²

Department of Neurosurgery, Hurisarang Hospital, Daejeon, ¹Department of Neurosurgery, Chosun University, Gwangju, ²Department of Neurosurgery, Mokpo Christian Hospital, Mokpo, Korea

ABSTRACT

Background: Acute lumbar disc herniation can occur in every lumbar intervertebral disc space and in multiple levels simultaneously. In the cases of 2 levels adjacent lumbar disc herniations of severe unilateral radiculopathic leg pain caused by compression of the nerve roots, respectively, multiple incision or long incision is generally needed for simultaneous removal of disc fragment in 2 levels.

Objectives: We proposed the minimally invasive one portal skin incision endoscopic discectomy is effective and safe method to treat 2 levels adjacent lumbar disc herniation.

Materials and Methods: We have experimented total 8 cases of 2 levels adjacent lumbar disc herniation having unilateral radiculopathic pain respectively. All cases are 2 levels adjacent lumbar disc herniation. We have tried a percutaneous endoscopic transforaminal approach through minimal one portal skin incision and remove the two herniated disc materials in the adjacent levels.

Results: The L2-L3 level was involved in 2 patients, L3-L4 level in 6 patients, while the L4-L5 level was involved in 7 patients, L5-S1 level in 1 patient. The mean follow-up was 18.5 months. The mean visual analogue score (VAS) of the patients prior to surgery was 7.75, and the mean postoperative VAS was 2.375. According to Macnab's criteria, 3 patients had excellent results, 4 patients had good results, 1 patient had fair results, and no patient had a poor result; satisfactory results were obtained in 87.5% of the cases.

Conclusion: The percutaneous endoscopic transforaminal approach through 1 skin portal incision could be effective surgical method in unilateral adjacent 2 levels lumbar disc herniation.

Key words: Adjacent 2 levels disc herniation, one portal, percutaneous endoscopic lumbar discectomy, transforaminal approach

Introduction

Recently, a percutaneous endoscopic lumbar discectomy (PELD) has been becoming popular surgical treatment for

incapacitating sciatica from lumbar disc herniation. This procedure could be performed under local anesthesia and have many advantages such as preservation of normal paraspinal structures, minimizing the risk of postoperative scar formation and instability.

Especially, percutaneous endoscopic transforaminal approach is regarded as a useful and effective method in the higher than L4-L5 disc herniation. Usually, percutaneous endoscopic transforaminal discectomy need 1 small stab skin incision for entry portal. However, in case of multilevel disc herniation, multiple entry portal skin incision were usually needed separately.

At our hospital, in the cases of 2 levels lumbar disc herniations having severe unilateral radiculopathic leg pain caused by compression of the nerve roots, respectively, we have tried a percutaneous endoscopic discectomy through one portal

Access this article online	
Quick Response Code:	Website: www.asianjns.org
	DOI: 10.4103/1793-5482.154977

Address for correspondence:

Dr. Chang Il Ju, Department of Neurosurgery, School of Medicine, Chosun University, 365, Pilmun-daero, Dong-gu, Gwangju, 501-717, Korea.
E-mail: jchangil@chosun.ac.kr

skin incision and targeting the two herniated disc materials in the adjacent levels. We achieved satisfactory results with transforaminal approach. In this study, we discuss the percutaneous endoscopic transforaminal discectomy through 1 portal skin incision for the adjacent 2-level lumbar disc herniation.

Materials and Methods

The subjects

We have experimented 8 cases of 2 levels adjacent lumbar disc herniation having unilateral radiculopathic pain, respectively.

The patients included in this study met the following inclusion criteria: (1) The major symptom was unilateral radiating leg pain that was more prominent than back pain with a positive straight leg raising test; (2) radiologic investigations (computed tomographic [CT] and magnetic resonance imaging [MRI] scans) suggesting a 2 levels adjacent lumbar disc herniation; (3) L5-S1 disc herniation of far lateral and foraminal disc herniation type; (4) Nerve root compression is confirmed by both three dimensional CT scan and MRI, (5) failure of appropriate conservative treatment for 8 weeks, and (6) no calcified disc herniation.

Patients were excluded from this study based on the following criteria: (1) 2 levels disc herniation including L5-S1 disc herniation of central or posterolateral type, (2) bilateral symptoms were prominent according to different disc herniation, (3) severe disc space narrowing and facet hypertrophy with lateral recess stenosis, (4) calcified disc herniation; (5) patients with significant neurological deficits, and (6) associated spondylolisthesis or severe spinal stenosis.

Procedure

There is generally a trend in favor of a local anesthetic procedure for nerve root injury monitoring during surgery and for the early assessment of surgical results.^[1-7] At our hospital, epidural anesthesia was performed in all cases. Either 100 µg fentanyl and 0.5% pucain were diluted by 1/2 and prepared 0.25% solution and approximately 15-20 cc was injected to the epidural space or 15-20 cc 0.5% pucain stock solution was injected to the epidural space, anesthesia was assessed by checking the sensory level, and surgery was performed.^[2,3,8,9] During surgery, this procedure is not enough to block the nerve root completely, so we could detect the patient's sensory and motor changes.

The sequence of surgery was identical to the general, endoscopic posterolateral procedure.^[1,10,11,12] The skin entry point was approximately 8-12 cm off the midline and intermediate location between upper disc and lower disc space level. Prior to the procedure, regardless of order of upper and lower disc level, evocative chromodiscography was performed with indigo-carmin dye.^[1,13] A guide wire was inserted through the needle channel into the annulus;

then a 0.5-1 cm skin incision was made at the entry needle site. An operative sheath (YESS System; Wolf, Knittlingen, Germany) was introduced into the disc space through the transforaminal safety working zone [Figure 1]. In the cases of foraminal and far lateral (extraforaminal) types of herniation, the rigid endoscope does not need to enter into epidural space or disc space centrally because the disc material is located closer and behind and under the exiting nerve root. For the purpose of securing a safety zone, the angle of the endoscope accessing the ruptured disc material would be steeper (angle, 30-45°). Without a decompressive discectomy, fragments can be identified and removed easily in the intervertebral foraminal space. In the cases of extraforaminal or far lateral disc type herniations, the PELD can remove the disc material effectively and decompress the nerve root safely without fusion [Figure 2]. In the cases of posterolateral and central type lumbar disc herniation, the disc decompression was performed in a manner identical to the percutaneous endoscopic posterolateral transforaminal procedure and after completing the decompression, the cannula was removed carefully from the foraminal space and moved to the upper margin of the lower vertebral pedicle.^[2,8,14,15] The pedicle is surrounded by abundant soft tissues, fat, and blood vessels. The superior margin of the pedicle was secured by removing these structures completely using a high voltage bipolar probe (Ellman Innovation, New York, USA) and forceps.

In the case of inferior migrated disc herniation, the transverse nerve root may be protected by disc material. However, in the case of disc herniation centrally rather than posterolaterally, a less protective structures may expose the traversing nerve root to injury. Therefore, it is very important to identify the nerve root during the transforaminal suprapedicular approach (i.e. twitching of the involved leg by high voltage bipolar the probe stimulation).^[16]

If the pedicle and upper margin of the lower vertebra are prepared properly, sufficient space to perform the suprapedicular approach is obtained, the traversing nerve root can be visualized, and careful manipulation to decompress the space of the ventral and lateral parts of the nerve root can be attempted.

During the transforaminal suprapedicular approach, If the space of lateral recess was decompressed enough to free the nerve root by the transforaminal suprapedicular approach, additional decompression of the epidural space was performed from the direction of the lateral recess to the disc space.^[16]

Occasionally, due to the presence of spondylosis in the upper margin of the lower vertebra, the space may be not sufficient or covered to the level, thus impeding the surgery. In such cases, the upper margin of the lower vertebra was removed using a punch. During the performance of the procedure, the epidural space and the traversing root are exposed, and

occasionally, the ruptured disc material is exposed first and thus it can be readily removed. However, the inferior migrated ruptured disc material is present below the traversing nerve root in most cases, thus care must be exercised not to injure the traversing root. In the cases of including L5-S1 disc herniation. This endoscopic transforaminal approach to 2 levels disc space becomes more difficult. The entry point should be higher than the iliac crest not to be blocked, and an approaching trajectory angulation changed more vertical and caudal. The space between L5 transverse process and alar of sacrum should be secured. Insertion into the epidural space of L5-S1 by a transforaminal route is a difficult and dangerous approach.

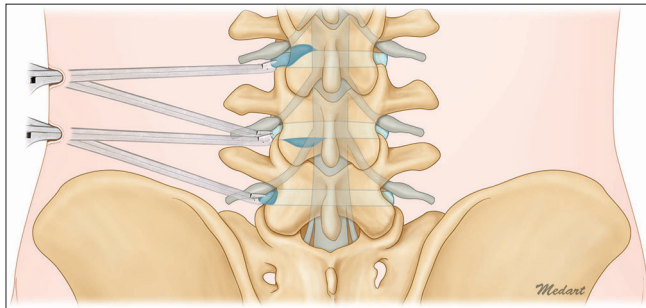


Figure 1: Schematic view of the percutaneous endoscopic 2 levels adjacent lumbar discectomy through 1 portal skin incision. Transforaminal endoscopic approach is easy in higher level rather than L4-L5. Entry point of transforaminal approach is at the midpoint of L3-L4 and L4-L5 disc space. The trajectory and angle is more steep and vertical in L5-S1 disc herniation. Without order of upper and lower lumbar disc level, an endoscopic device can access into the disc space through the transforaminal safety working zone

Therefore, in our cases, only far lateral disc or foraminal disc herniation was indicated in the endoscopic transforaminal approach [Figure 3].

Evaluation

Based on MRI and three dimensional CT with discogram images taken prior to surgery, disc level, herniated disc type and the relationship with adjacent anatomic structures were analyzed. Approximately 1-4 h after surgery, MRI was performed for assessment of the remnant disc. Approximately 1-week after surgery, the improvement of the patient was evaluated by the visual analogue pain score (VAS), Oswestry disability scores, and neurologic tests.

Outcomes were categorized using Macnab criteria, as follows: Excellent (no pain and no restriction of activity), good (occasional back or leg pain of sufficient severity to interfere with normal work or leisure activities), fair (handicapped by intermittent pain of sufficient severity to curtail work or leisure activities, but improved functional capacity), and poor (unimproved symptoms, insufficient improvement to allow increased activity, or requirement of reoperation at the same level). Data were collected by a registered nurse employed by the operating surgeon.

Results

Eight patients were operated on between October 2010 and July 2012 for multiple lumbar disc herniations with the transforaminal endoscopic technique. There were 3 male and

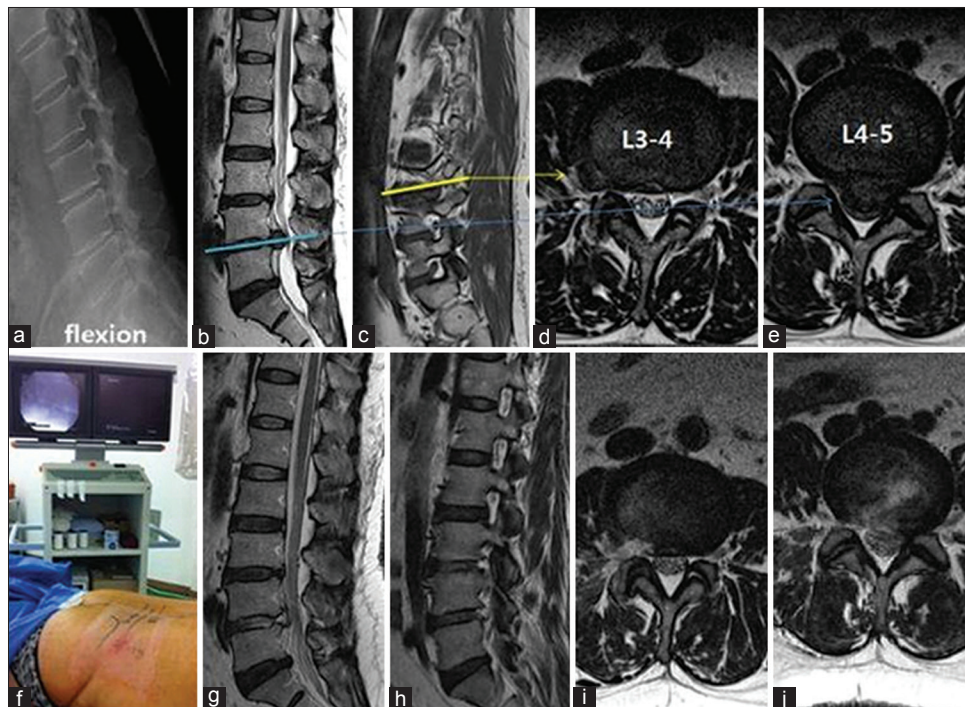


Figure 2: Preoperative magnetic resonance images (MRI) show left far lateral type L3-L4 disc herniation and high canal compromised type of L4-L5 lumbar disc herniation (a-e). Simultaneous endoscopically 2 adjacent level discectomy was performed by one portal skin incision (f). Postoperative MRI show herniated disc materials removed successfully in L3-L4 and L4-L5 (g-j)

5 female patients. The age distribution of patients was as follows: 20-29 years (2), 30-39 years (3), 40-49 years (2) and 50-59 years (1).

The L2-L3 level was involved in 2 patients, L3-L4 level in 6 patients, while the L4-L5 level was involved in 7 patients, L5-S1 level in 1 patient. The preoperative MRI and three dimensional CT with discogram images showed that 3 levels were non-contained type disc herniations and 13 levels were contained-type disc herniations. According to disc herniation types, 10 levels were posterolateral type, 3 levels of foraminal type, 2 levels of far lateral type and 1 level was high canal compromised type [Table 1].

There were no patients who required conversion to an open procedure after abandonment of the transforaminal endoscopic discectomy.

One patient (12.5%) developed lower extremity paresthesias in a dermatomal distribution that was different from the preoperative radiating pain, but the dysesthesias were

transient and improved over 4 weeks. There is no case of motor weakness and neurological deficit.

The mean follow-up was 18.5 months. The mean VAS of the patients prior to surgery was 8, and the mean postoperative VAS was 2.75. According to Macnab's criteria, 3 patients had excellent results, 4 patients had good results, 1 patient had fair results, and no patient had a poor result; satisfactory results were obtained in 87.5% of the cases.

There were no infections, discitis, paresis, dural tears, vascular injuries, or systemic complications. At the final follow-up, there were no patients with unsatisfactory outcomes requiring revision surgery.

Discussion

Increasing life expectancy has made spinal degenerative disease a common pathology in the elderly population. The lumbar disc degeneration is one of the most common phenomena in the spinal degenerative change. Acute lumbar disc herniation can occur in every lumbar intervertebral disc space and multiple levels simultaneously. However, the lumbar discs most often affected by degeneration that leads to herniation are L4-L5 and L5-S1, most probably because of a combination of longstanding degeneration and a subsequent change in the ability of the disc to resist applied stress. Multiple disc herniation may compress several nerve roots and increased neurologic symptoms and even neurological deficits, which is characterized by cauda equina syndromes when central or radiculopathic.^[14,17]

Generally, The choice of surgical treatments for lumbar disc diseases have been conventional laminectomies and discectomies and recently endoscopic discectomies have become a popular method.^[1,10-13,15,18-28]

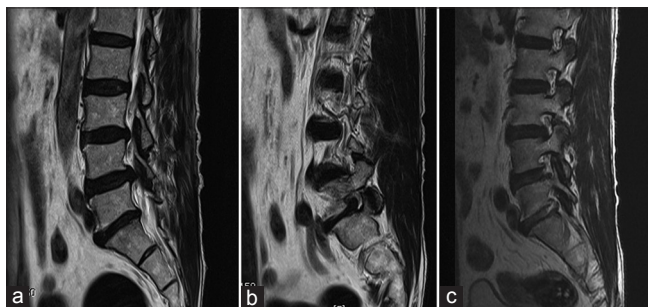


Figure 3: Preoperative magnetic resonance images (MRI) show posterolateral type L4-L5 disc herniation and foraminal type of L5-S1 disc herniation (a and b). Postoperative MRI show herniated disc materials removed simultaneously, and L5 exiting nerve root decompressed successfully (c)

Table 1: Surgical outcomes of PELD 2 levels adjacent lumbar disc herniation through 1 portal skin incision

Case	Age/sex	Level	C/C	Preoperative VAS	Postoperative VAS	Macnab's criteria	Complications
1	25/female	L3-L4 (posterolateral) L4-L5 (posterolateral)	LBP left leg pain	8	3	Good	
2	33/female	L3-L4 (far lateral) L4-L5 (high canal compromised)	Right leg pain	9	2	Excellent	
3	36/female	L2-L3 (foraminal) L3-L4 (posterolateral)	LBP, right leg pain	7	2	Good	
4	27/male	L4-L5 (posterolateral) L5-S1 (foraminal)	LBP left leg pain	8	3	Good	
5	44/male	L3-L4 (posterolateral) L4-L5 (posterolateral)	Left leg pain	7	1	Excellent	
6	55/female	L2-L3 (posterolateral) L3-L4 (far lateral)	LBP left leg pain	8	4	Fair	Transient paresthesia
7	43/female	L3-L4 (posterolateral) L4-L5 (posterolateral)	Right leg pain	7	3	Good	
8	32/male	L3-L4 (foraminal) L4-L5 (posterolateral)	Right leg pain	8	1	Excellent	
Total				7.75	2.375		

PELD - Percutaneous endoscopic lumbar discectomy; VAS - Visual analogue score; LBP - Low back pain

The success rates of discectomy for lumbar disc herniation have improved greatly and range from 80% to 96%. Generally, microscopic discectomy after laminotomy is still considered the gold standard but recently numerous studies involving endoscopic discectomy have been reported, and the outcomes have been improving gradually.^[1,10,18,19,29-30] However, due to anatomic barriers, such as the iliac wing, the lateral approach to endoscopic discectomy has many limitations. The height of the working disc space should be adequate, and the working disc space must be approached through the foraminal space, which is difficult.^[1] Therefore, due to anatomic reasons, the indications for endoscopic surgery are limited, and endoscopic surgery is relatively contraindicated for non-contained high-grade canal compromise or migration type cases.^[31,32]

The incidence of complications after endoscopic lumbar discectomies is low and it has many advantages over minimally invasive procedures; specifically, with endoscopic lumbar discectomies, the possibility of resection of bone and ligament is dispensed and by performing the selective evacuation of the intervertebral space, surgery-induced instability can be prevented.^[5,6,24,31-36] In addition, endoscopic lumbar discectomy is less traumatic, has a shorter operating time, less scarring, and conserves the intact intra-epidural lubricant structure, such as epidural fat and yellow ligaments. Post-discectomy syndrome or other surgery-associated deterioration does not develop, revision is not more difficult, and destabilization-induced by surgery does not readily develop. As general anesthesia is not required, not only are the complications developing in the elderly or the increase in morbidity less, but also the hospital stay is shortened, and rehabilitation is quicker. In comparison with microscopic discectomy, return to work or sports activities is more rapid, and thus it is accepted by patients more readily with a high patient acceptance.^[37,38] More important points are that epidural scarring develops in more than 10% of patients after conventional laminectomy and discectomy,^[7,39-42] and in posterolateral endoscopic discectomy, such scars have not been detected by MRI or during revision surgery.^[15] Therefore, subsequent endoscopic or conventional procedures are possible.^[43,44]

Despite such numerous advantages, endoscopic discectomy is not universally accepted because to acquire endoscopic procedural skills is difficult, and thus it has a flattened and lengthy learning curve, and in comparison with microscopic discectomy, surgical outcomes after endoscopic discectomy are not considered superior and its indications are limited. Due to anatomic limitations, endoscopic discectomy using a lateral approach has many restrictions; the approach is through the iliac wing, and thus the iliac wing and the height of the working disc space should be adequate.^[11] One has to approach the working disc space through the foraminal space, which is difficult, and because a rigid endoscope is used, the

approach in cases with high-grade migration and high canal compromise is difficult.^[24,26]

According to Ditsworth it has been reported that despite endoscopic transforaminal lumbar discectomy having numerous advantages and showing good surgical results,^[26] it has several shortcomings; surgical manipulation is not easy, and thus it is possible to remove only a portion of the extruded disc, resulting in a lower success rate (83%).

To overcome such limitations, it is important to understand the anatomic relationship of the lesion disc and adjacent structures prior to surgery.^[45-47]

Usually, because the higher the lumbar level is, the larger the foramen is, the transforaminal approach is a useful method in cases of lumbar disc herniation higher than L4-L5. Because the higher lumbar level is, the larger foramen is. Therefore, it is easy to perform targeting approach to 2 levels disc herniation simultaneously and to manipulate endoscopic inserting angle. However, in the L5-S1 lumbar disc herniation, the transforaminal approach is not good indication. Because the iliac wing frequently blocks the approach trajectory, these anatomical obstacles make the endoscope insertion angulation more steep and vertical. Furthermore, the L5 transverse process is more large, and it make foraminal space too narrowed to insert the endoscope into the safety zone. These uneasy hindrances make it very difficult and dangerous to manipulate the endoscope in the intervertebral disc space through the transforaminal route. Therefore, the endoscopic interlaminar approach is more frequently used and effective in L5-S1 disc herniation rather than transforaminal approach. However, in our cases, we have performed approach to L5-S1 disc space by the transforaminal route to remove the L4-L5 disc herniation simultaneously together. In L5-S1 disc herniation, it is very difficult and dangerous to enter into the L5-S1 epidural space transforaminal route, because the insertion angle is very steep and vertical, intervertebral foramen is narrow and endoscope manipulation is limited by anatomical structures. Therefore, the posterolateral disc herniation in L5-S1, most common type, is not good indication for transforaminal approach, but far lateral (extraforaminal), and foraminal type disc herniation are indicated. In these cases, Posterolateral endoscopic foraminal discectomy does not require entry into the spinal canal and, therefore, minimizes the occurrence of the traction on the dura and the nerve root. In our limited experience, percutaneous endoscopic access to the lateral recess of the lumbar spine for the decompression of the exiting root is a minimally invasive procedure that appears to be safe and effective.

In the cases of 2 adjacent levels, lumbar disc herniation, usually 2 portal skin incision endoscopic approaching was preferred. Because independent separated approaching on the different level is familiar to the operator, and it make him feel easier. However, although this endoscopic approach is minimal

invasive, two portal incisions and operative device insertion through different portal site can cause more paravertebral erector spinae muscular injury than one portal incision. It may cause postoperative paravertebral back pain. Furthermore, two portal skin incisions would take longer time to mark the initial skin incision again and repetitive approaching to another disc level, and this will make difficult to operator as well as patient, especially without general anesthesia. However, our technique need just to change approaching trajectory to another disc level through a portal incision site after one level lumbar discectomy.

Although the total number of cases were limited, a satisfactory outcome with resolution of sciatic pain was observed in 87.5% of patients. Of 8 self-employed patients, 3 patients had an excellent recovery and 4 patients had a good recovery and returned to their previous work and activities. We have not encountered any neurovascular complications following this operative procedure. Although the outcome in this limited group of 8 patients who underwent endoscopic 2 levels discectomy by 1 portal skin incision has been encouraging, a larger number of patients and a longer follow-up period are required to confirm these early results.

Conclusion

Multiple Lumbar disc herniation could occur in any lumbar disc level and have various symptoms from nerve roots compressed. This make it difficult to remove the disc materials properly by a PELD using a rigid endoscope. Nevertheless, if unilateral radiculopathy derived from 2 levels adjacent disc herniation higher than L4-L5 or extraforaminal type in L5-S1, it could be treated by percutaneous endoscopic transforaminal approach through a 1 skin portal incision and satisfactory results can be obtained.

References

- Fritsch EW, Heisel J, Rupp S. The failed back surgery syndrome: Reasons, intraoperative findings, and long-term results: A report of 182 operative treatments. *Spine (Phila Pa 1976)* 1996;21:626-33.
- Jang JS, An SH, Lee SH. Transforaminal percutaneous endoscopic discectomy in the treatment of foraminal and extraforaminal lumbar disc herniations. *J Spinal Disord Tech* 2006;19:338-43.
- Kambin P, NASS. Arthroscopic microdiscectomy. *Spine J* 2003;3:60S-4.
- Kotilainen E, Valtonen S. Clinical instability of the lumbar spine after microdiscectomy. *Acta Neurochir (Wien)* 1993;125:120-6.
- Mochida J, Toh E, Nomura T, Nishimura K. The risks and benefits of percutaneous nucleotomy for lumbar disc herniation. A 10-year longitudinal study. *J Bone Joint Surg Br* 2001;83:501-5.
- Onik G, Mooney V, Maroon JC, Wiltse L, Helms C, Schweigel J, *et al.* Automated percutaneous discectomy: A prospective multi-institutional study. *Neurosurgery* 1990;26:228-32.
- Papadopoulos EC, Girardi FP, Sama A, Pappou IP, Urban MK, Cammisia FP Jr. Lumbar microdiscectomy under epidural anesthesia: a comparison study. *Spine J* 2006;6:561-4.
- Hall S, Bartleson JD, Onofrio BM, Baker HL Jr, Okazaki H, O'Duffy JD. Lumbar spinal stenosis. Clinical features, diagnostic procedures, and results of surgical treatment in 68 patients. *Ann Intern Med* 1985;103:271-5.
- Kambin P, Cohen LF, Brooks M, Schaffer JL. Development of degenerative spondylosis of the lumbar spine after partial discectomy. Comparison of laminotomy, discectomy, and posterolateral discectomy. *Spine (Phila Pa 1976)* 1995;20:599-607.
- Donceel P, Du Bois M. Fitness for work after surgery for lumbar disc herniation: A retrospective study. *Eur Spine J* 1998;7:29-35.
- Gill K. Retroperitoneal bleeding after automated percutaneous discectomy. A case report. *Spine (Phila Pa 1976)* 1990;15:1376-7.
- Greenberg PE, Brown MD, Pallares VS, Tompkins JS, Mann NH. Epidural anesthesia for lumbar spine surgery. *J Spinal Disord* 1988;1:139-43.
- Demirel CB, Kalayci M, Ozkocak I, Altunkaya H, Ozer Y, Acikgoz B. A prospective randomized study comparing perioperative outcome variables after epidural or general anesthesia for lumbar disc surgery. *J Neurosurg Anesthesiol* 2003;15:185-92.
- Epstein JA, Epstein BS, Lavine LS, Carras R, Rosenthal AD, Sumner P. Lumbar nerve root compression at the intervertebral foramina caused by arthritis of the posterior facets. *J Neurosurg* 1973;39:362-9.
- Halldin K, Zoëga B, Lind B, Cederlund CG. Clinical application of a new three-dimensional radiological classification of lumbar disc herniations. *Ups J Med Sci* 2005;110:159-65.
- Chae KH, Ju CI, Lee SM, Kim BW, Kim SY, Kim HS. Strategies for noncontained lumbar disc herniation by an endoscopic approach: Transforaminal suprapedicular approach, semi-rigid flexible curved probe, and 3-dimensional reconstruction CT with discogram. *J Korean Neurosurg Soc* 2009;46:312-6.
- Verbiest H. Stenosis of the lumbar vertebral canal and sciatica. *Neurosurg Rev* 1980;3:75-89.
- Ahn Y, Lee SH, Park WM, Lee HY, Shin SW, Kang HY. Percutaneous endoscopic lumbar discectomy for recurrent disc herniation: Surgical technique, outcome, and prognostic factors of 43 consecutive cases. *Spine (Phila Pa 1976)* 2004;29:E326-32.
- Andrews DW, Lavigne MH. Retrospective analysis of microsurgical and standard lumbar discectomy. *Spine (Phila Pa 1976)* 1990;15:329-35.
- Asch HL, Lewis PJ, Moreland DB, Egnatchik JG, Yu YJ, Clabeaux DE, *et al.* Prospective multiple outcomes study of outpatient lumbar microdiscectomy: Should 75 to 80% success rates be the norm? *J Neurosurg* 2002;96:34-44.
- BenDebba M, Augustus van Alphen H, Long DM. Association between peridural scar and activity-related pain after lumbar discectomy. *Neurol Res* 1999;21 Suppl 1:S37-42.
- Calisanelle T, Ozdemir O, Karadeli E, Altinors N. Six months post-operative clinical and 24 hour post-operative MRI examinations after nucleoplasty with radiofrequency energy. *Acta Neurochir (Wien)* 2007;149:495-500.
- Choi G, Lee SH, Raiturker PP, Lee S, Chae YS. Percutaneous endoscopic interlaminar discectomy for intracanalicular disc herniations at L5-S1 using a rigid working channel endoscope. *Neurosurgery* 2006;58:ONS59-68.
- Choi G, Lee SH, Bhanot A, Raiturker PP, Chae YS. Percutaneous endoscopic discectomy for extraforaminal lumbar disc herniations: Extraforaminal targeted fragmentectomy technique using working channel endoscope. *Spine (Phila Pa 1976)* 2007;32:E93-9.
- Couto JM, Castilho EA, Menezes PR. Chemonucleolysis in lumbar disc herniation: A meta-analysis. *Clinics (Sao Paulo)* 2007;62:175-80.
- Ditsworth DA. Endoscopic transforaminal lumbar discectomy and reconfiguration: A postero-lateral approach into the spinal canal. *Surg Neurol* 1998;49:588-97.
- Eustacchio S, Flaschka G, Trummer M, Fuchs I, Unger F. Endoscopic percutaneous transforaminal treatment for herniated lumbar discs. *Acta Neurochir (Wien)* 2002;144:997-1004.
- Halldin K, Zoëga B, Kärrholm J, Lind BI, Nyberg P. Is increased segmental motion early after lumbar discectomy related to poor clinical outcome 5 years later? *Int Orthop* 2005;29:260-4.
- Lee SH, Kang BU, Ahn Y, Choi G, Choi YG, Ahn KU, *et al.* Operative failure of percutaneous endoscopic lumbar discectomy: A radiologic analysis of 55 cases. *Spine (Phila Pa 1976)* 2006;31:E285-90.
- Wu X, Zhuang S, Mao Z, Chen H. Microendoscopic discectomy for lumbar disc herniation: Surgical technique and outcome in 873

- consecutive cases. *Spine (Phila Pa 1976)* 2006;31:2689-94.
31. Mayer HM, Brock M. Percutaneous endoscopic discectomy: Surgical technique and preliminary results compared to microsurgical discectomy. *J Neurosurg* 1993;78:216-25.
 32. Mekhail N, Kapural L. Intradiscal thermal annuloplasty for discogenic pain: An outcome study. *Pain Pract* 2004;4:84-90.
 33. Lewis PJ, Weir BK, Broad RW, Grace MG. Long-term prospective study of lumbosacral discectomy. *J Neurosurg* 1987;67:49-53.
 34. Maroon JC, Abla A, Bost J. Association between peridural scar and persistent low back pain after lumbar discectomy. *Neurol Res* 1999;21 Suppl 1:S43-6.
 35. McLain RF, Kalfas I, Bell GR, Tetzlaff JE, Yoon HJ, Rana M. Comparison of spinal and general anesthesia in lumbar laminectomy surgery: A case-controlled analysis of 400 patients. *J Neurosurg Spine* 2005;2:17-22.
 36. Mochida J, Nishimura K, Nomura T, Toh E, Chiba M. The importance of preserving disc structure in surgical approaches to lumbar disc herniation. *Spine (Phila Pa 1976)* 1996;21:1556-63.
 37. Lee S, Kim SK, Lee SH, Kim WJ, Choi WC, Choi G, *et al.* Percutaneous endoscopic lumbar discectomy for migrated disc herniation: Classification of disc migration and surgical approaches. *Eur Spine J* 2007;16:431-7.
 38. Ozer AF, Oktenoglu T, Sasani M, Bozkus H, Canbulat N, Karaarslan E, *et al.* Preserving the ligamentum flavum in lumbar discectomy: A new technique that prevents scar tissue formation in the first 6 months postsurgery. *Neurosurgery* 2006;59:ONS126-33.
 39. Park YK, Kim JH, Chung HS. Outcome analysis of patients after ligament-sparing microdiscectomy for lumbar disc herniation. *Neurosurg Focus* 2002;13:E4.
 40. Ross JS, Robertson JT, Frederickson RC, Petrie JL, Obuchowski N, Modic MT, *et al.* Association between peridural scar and recurrent radicular pain after lumbar discectomy: Magnetic resonance evaluation. *ADCON-L European Study Group. Neurosurgery* 1996;38:855-61.
 41. Ruetten S, Komp M, Godolias G. An extreme lateral access for the surgery of lumbar disc herniations inside the spinal canal using the full-endoscopic uniportal transforaminal approach-technique and prospective results of 463 patients. *Spine (Phila Pa 1976)* 2005;30:2570-8.
 42. Ruetten S, Meyer O, Godolias G. Epiduroscopic diagnosis and treatment of epidural adhesions in chronic back pain syndrome of patients with previous surgical treatment: first results of 31 interventions. *Z Orthop Ihre Grenzgeb* 2002;140:171-5.
 43. Segnarbieux F, Van de Kelft E, Candon E, Bitoun J, Frèrebeau P. Disco-computed tomography in extraforaminal and foraminal lumbar disc herniation: Influence on surgical approaches. *Neurosurgery* 1994;34:643-7.
 44. Tomecek FJ, Anthony CS, Boxell C, Warren J. Discography interpretation and techniques in the lumbar spine. *Neurosurg Focus* 2002;13:E13.
 45. Tsou PM, Yeung AT. Transforaminal endoscopic decompression for radiculopathy secondary to intracanal noncontained lumbar disc herniations: outcome and technique. *Spine J* 2002;2:41-8.
 46. Tsou PM, Alan Yeung C, Yeung AT. Posterolateral transforaminal selective endoscopic discectomy and thermal annuloplasty for chronic lumbar discogenic pain: A minimal access visualized intradiscal surgical procedure. *Spine J* 2004;4:564-73.
 47. Williams RW. Microlumbar discectomy. A 12-year statistical review. *Spine* 1986;11:851-2.

How to cite this article: Kim HS, Ju CI, Kim SW, Kim JG, Lee SM, Kim BW. Minimally invasive percutaneous endoscopic 2 levels adjacent lumbar discectomy through 1 portal skin incision: Preliminary study. *Asian J Neurosurg* 2015;10:95-101.

Source of Support: Nil, **Conflict of Interest:** None declared.

Staying in touch with the journal

1) Table of Contents (TOC) email alert

Receive an email alert containing the TOC when a new complete issue of the journal is made available online. To register for TOC alerts go to www.asianjns.org/signup.asp.

2) RSS feeds

Really Simple Syndication (RSS) helps you to get alerts on new publication right on your desktop without going to the journal's website. You need a software (e.g. RSSReader, Feed Demon, FeedReader, My Yahoo!, NewsGator and NewzCrawler) to get advantage of this tool. RSS feeds can also be read through FireFox or Microsoft Outlook 2007. Once any of these small (and mostly free) software is installed, add www.asianjns.org/rssfeed.asp as one of the feeds.