

CASE REPORT

Malignant fibrous histiocytoma of the skull base: A neurosurgical nuance

Amit Mahore, Raghvendra Ramdasi, Nitin Dange, Sridhar Epari¹

Department of Neurosurgery, King Edward Memorial Hospital and Seth Gordhandas Sunderdas Medical College, ¹Department of Neuropathology, Tata Memorial Hospital, Parel, Mumbai, Maharashtra, India

ABSTRACT

A 69-year-old male, treated for colonic carcinoma 15 years back, presented to our services with status epilepticus. He had complaints of headache and vomiting for 7 days prior to presentation. Computed tomography and magnetic resonance imaging of the brain revealed heterogeneous, lobulated and osteolytic tumor involving middle and posterior cranial fossa. Excision of the tumor was planned in two stages. Middle fossa component was removed through right temporobasal approach. Histopathology was suggestive of malignant fibrous histiocytoma. Patient succumbed to pneumonia and septicemia in the postoperative period. Pathology, clinical features and therapeutic challenges of this clinical entity have been briefly reviewed.

Key words: Skull base, malignant fibrous histiocytoma, undifferentiated pleomorphic soft tissue sarcoma, metastasis, calvarial sarcoma

Introduction

Undifferentiated pleomorphic sarcoma is a new terminology for malignant fibrous histiocytoma (MFH). Its occurrence in head and neck is rare.^[1-3] We report a case of undifferentiated pleomorphic sarcoma of the skull base with the intradural extension.

Case Report

A 69-year-old male, who underwent surgery and chemotherapy for carcinoma of descending colon 15 years ago, was brought to our emergency department with status epilepticus. He had complaints of headache and vomiting for 7 days prior to presentation. The computed tomography scan of the brain showed an extensive osteolytic lesion of base of the skull in the right middle and posterior cranial fossa. It showed scattered calcification and mass effect on the brainstem [Figure 1a]. On magnetic resonance imaging, it

showed an intense enhancement of contrast and encasement of carotid artery [Figure 1b-d]. A provisional diagnosis of metastasis from carcinoma of the colon was considered. Excision of the tumor was planned in two stages. He was subjected to right temporobasal craniotomy for removal of the middle fossa component at initial stage. In the second stage, an excision of the posterior fossa extension was planned. Tumor was firm and highly vascular with foci of calcification. It was originating from the base of the skull and had destroyed basal and petrous parts of the temporal bone. It had infiltrated into the temporal dura and brain. The base of the skull was repaired using temporalis muscle, fat, and fascia lata. Unfortunately, the patient developed pneumonitis and septicemia in the postoperative period and expired after 2 days. On histopathological examination, tumor was composed of sheets of large pleomorphic cells with marked nuclear pleomorphism and frequent mitoses. The tumor cells were positive for vimentin and negative for S-100 protein, smooth muscle actin, epithelial membrane antigen, and CD34. Histopathology was suggestive of undifferentiated pleomorphic sarcoma [Figure 2a-h].

Discussion

Malignant fibrous histiocytoma is a synonym for the undifferentiated pleomorphic sarcoma as per the recent World Health Organization classification.^[1] These are commonly found in the extremities (68%) and in the retro-peritoneum (16%). These tumors in the head region have rarely been reported.^[2,3] The first report of the occurrence of MFH in central nervous system was given in 1976 by Gonzalez-Vitale *et al.*^[4] The cranial MFH can have either extracranial or intracranial origin.

Access this article online

Quick Response Code:



Website:

www.asianjns.org

DOI:

10.4103/1793-5482.154981

Address of correspondence:

Dr. Raghvendra Ramdasi, King Edward VII Memorial Hospital, Parel, Mumbai - 400 012, Maharashtra, India.
E-mail: drraghavr@gmail.com

Intracranially, these can arise from meninges, parenchyma or ventricle.^[5] Extra-cranially these can arise from the scalp or the bone.^[6-8] Bony origin can be either from the jaw bones or calvarium.^[6] The calvarium is least common site of origin of MFH. Till date, only 15 such cases have been reported.^[2-4,6,9-15] The bones affected in the head region are temporal, parietal, fronto-temporal, occipito-temporal, fronto-parieto-temporal and clivus [Table 1].^[4,6,12] It is the first case of an extensive

lesion occupying both middle and posterior cranial fossa and presenting with status epilepticus.

Malignant fibrous histiocytoma is known to occur in previously abnormal bone affected by radiation, infection, and trauma. It is also associated with Paget's disease and fibrous dysplasia.^[16] MFH presents with varying degrees of bone destruction and mimics meningioma.^[2,3]

Radiologically MFH is seen as large lobulated mass with hypo to isointense regions and has heterogeneous enhancement on giving contrast. Hypointense regions are suggestive of necrosis, hemorrhage or myxomatous changes. Radiological differential diagnosis of MFH includes meningioma, osteosarcoma, chondrosarcoma, osteochondroma, dedifferentiated chordoma, plasmacytoma, lymphoma, and metastasis.^[17]

Malignant fibrous histiocytoma histologically consists of atypical fibroblasts and histiocytes in variable proportions. The diagnosis of MFH requires exclusion of other dedifferentiated pleomorphic sarcoma. It can be done by immunohistochemistry. It is vimentin positive and CD18 negative.^[18] Four histological subtypes of MFH have been described. They are storiform-pleomorphic, myxoid, giant cell and inflammatory. The giant cell variant is associated with higher recurrence rate than storiform/pleomorphic MFH. It has a higher rate of metastasis than the inflammatory form.^[19]

There are various inherent problems involved in the management of MFH similar to the other malignancies of base of the skull. These are summarized below:

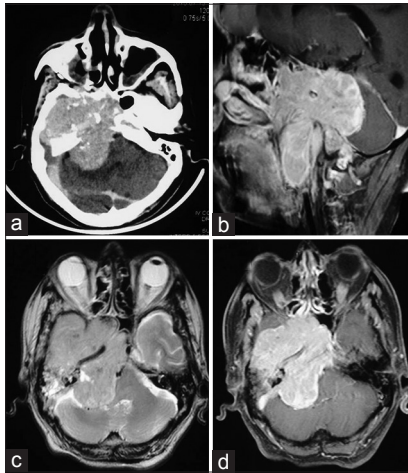


Figure 1: (a) Postcontrast computed tomography of the brain showing heterogeneous, lobulated and osteolytic lesion in the right middle and posterior cranial fossa with scattered calcification and mass effect on brainstem. (b) postcontrast sagittal image, (c) plain axial image and (d) (postcontrast Axial image)-magnetic resonance imaging brain showing intense contrast enhancement, encasement of carotid artery, extension into infratemporal fossa and mass effect on brainstem by the lesion

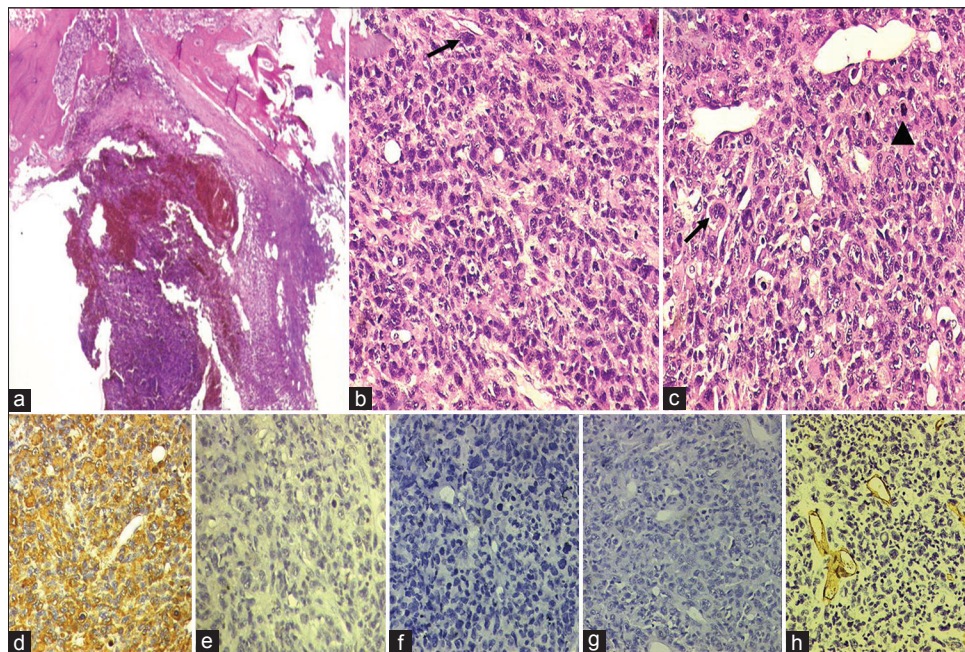


Figure 2: Photomicrograph showing a malignant tumor within the bone (a) (H and E, $\times 25$) composed of sheets of large pleomorphic cells with marked nuclear pleomorphism and frequent mitoses (b and c) (H and E, $\times 200$; arrow for tumor giant cells and arrow head for mitoses). The tumor cells are positive for vimentin (d) (immunohistochemistry [IHC], $\times 200$); while negative for S-100 protein (e) (IHC, $\times 200$), smooth muscle actin (f) (IHC, $\times 200$), epithelial membrane antigen (g) (IHC, $\times 200$) and CD34 (h) (IHC, $\times 200$)

Table 1: Cases of malignant fibrous histiocytoma arising from the bone

Author/year	Age/sex	Location	Treatment	Outcome
Gonzalez-Vitale <i>et al.</i> (1976) ^[4]	37/male	Skull base in region of sella	Ventriculo-peritoneal shunt	Died on 3 rd day of surgery
Chiatle <i>et al.</i> (1981) ^[9]	18/male	Temporal	S, R, C	Alive (1-year)
Dyck (1987) ^[6]	41/male	Frontal	S, R	Alive (8 months)
Cook <i>et al.</i> (1987) ^[6]	2.5/male	Clivus	S, R, C	Died (3.5 years)
Romero <i>et al.</i> (1989) ^[6]	32/female	Temporal	Surgery	Alive
Matuura <i>et al.</i> (1991) ^[40]	72/male	Occipital	Surgery	Died (6 months)
Hatashita <i>et al.</i> (1992) ^[2]	45/male	Frontal	Surgery	Alive (2 years)
Nakayama <i>et al.</i> (1997) ^[3]	19/female	Temporal	S, C	Died (4 days)
Yoshida <i>et al.</i> (1998) ^[6]	45/female	Parietal	S, R, C	Alive (2.5 years)
Asahi <i>et al.</i> (2002) ^[13]	69/female	Fronto-temporal	S	Died (22 months)
Ueda <i>et al.</i> (2003) ^[12]	18/female	Orbit, anterior skull base	S, R	Alive (1-year)
Joo <i>et al.</i> (2003) ^[11]	43/female	Parietal	S, R	Repeated recurrences, died (2 years)
Chhabra <i>et al.</i> (2004) ^[14]	25/female	Parieto-occipital	S	Lost follow-up
	22/male	Temporal	S, R	Recurrence at 1 month
Zhang <i>et al.</i> (2014) ^[15]	51/female	Occipital, postradiation	Surgery	Alive (6 months)
Present case	69/male	Middle and posterior fossa	S	Died after 2 days

S – Surgery; R – Radiotherapy; C – Chemotherapy

- The proximity to potentially infective spaces of paranasal sinuses
- Difficulty to achieve negative margins due to the presence of cranial nerve foramina, venous sinuses and major vessels of the brain in the vicinity
- Paucity of local tissues for transfers into the defect
- Need of multiple stages for surgical excision due to involvement of multiple compartments and
- Need of multiple blood transfusions due to rich vascularity.

Treatment of MFH consists of radical excision, postoperative radiation, and chemotherapy. However, most of the patients die within 1-year of surgery. MFH has 5 years survival rate of 34–50%.^[20] Lin *et al.* have published a retrospective clinical study of 28 cases of head and neck MFH. They have found a 3 years survival rate of 57.1%.^[21]

Our patient had status epilepticus due to invasion of temporal lobe by the tumor. The association between colonic cancer and MFH appears to be purely coincidental.

Conclusion

Pleomorphic undifferentiated sarcomas or MFHs arising from the skull base pose a therapeutic challenge to treating neurosurgeon. These should be considered in the differential diagnosis of aggressive, heterogeneous osteolytic lesions of the base of the skull.

References

1. Fletcher CDM, Unni KK, Mertens F. World Health Organization classification of tumors: Pathology and genetics of tumors of soft tissue and bone. Lyon: IARC press, 2002.
2. Hatashita S, Tajima A, Ueno H. Malignant fibrous histiocytoma in the skull. *Neurologia Medico Chirurgica* 1992;32:976-9.
3. Nakayama K, Nemoto Y, Inoue Y, Mochizuki T, Soares SB,

4. Ohata JK. *et al.* Malignant fibrous histiocytoma of the temporal bone with endocranial extension. *Am J of Neuroradiol* 1997;18:331-34.
5. Gonzalez-Vitale JC, Slavin RE, McQueen JD. Radiation-induced intracranial malignant fibrous histiocytoma. *Cancer* 1976;37:2960-3.
6. Mitsuhashi T, Watanabe M, Ohara Y, Hatashita S, Ueno H. Multifocal primary intracerebral malignant fibrous histiocytoma—Case report. *Neurol Med Chir (Tokyo)* 2004;44:249-54.
7. Yoshida D, Harashima K, Node Y, Kojima T, Shimura T, Teramoto A. Malignant fibrous histiocytoma in the parietal bone. *Neurol Med Chir (Tokyo)* 1998;38:359-62.
8. Krishnamurthy A. Malignant fibrous histiocytoma of the scalp: A rare differential with a dramatic clinical presentation. *J Indian Assoc Pediatr Surg* 2014;19:227-9.
9. Hayami J, Kurokawa I, Hashimoto K, Kusumoto K. Malignant fibrous histiocytoma of scalp with intracranial invasion 20 years after postoperative irradiation. *J Craniofac Surg* 2003;14:74-7.
10. Chitale VS, Sundaresan N, Helson L, Huvos AG. Malignant fibrous histiocytoma of the temporal bone with intracranial extension. *Acta Neurochir (Wien)* 1981;59:239-46.
11. Matsuura S, Takagi T, Tan EC, Mizuno S, Imagunbai N, Hasegawa R. Malignant fibrous histiocytoma of the occipital bone with intracranial extension—Case report. *Neurol Med Chir (Tokyo)* 1991;31:219-22.
12. Asahi T, Kurimoto M, Kawaguchi M, Yamamoto N, Sato S, Endo S. Malignant fibrous histiocytoma originating at the site of a previous fronto-temporal craniotomy. *J Clin Neurosci* 2002;9:704-8.
13. Ueda R, Hayashi T, Kameyama K, Yoshida K, Kawase T. Orbital malignant fibrous histiocytoma with extension to the base of the skull—Case report. *Neurol Med Chir (Tokyo)* 2003;43:263-6.
14. Joo M, Lee GJ, Koh YC, Kwon OK, Park YK. Primary intraosseous malignant fibrous histiocytoma of the skull: A case report. *J Korean Med Sci* 2003;18:609-13.
15. Chhabra R, Gupta SK, Manjunath Prasad KS, Gupta D, Vasishta RK, Sharma RK *et al.* Calvarial malignant fibrous histiocytoma. *Neurol India* 2004;52:387-90.
16. Zhang GB, Li J, Zhang PF, Han LJ, Zhang JT. Radiation-induced malignant fibrous histiocytoma of the occipital: A case report. *World J Surg Oncol* 2014;17:12:98.
17. Mirra JM, Picci P. Malignant fibrous histiocytoma. In: Mirra JM, ed. *Bone Tumors: Diagnosis and Treatment*. Philadelphia: Lea & Febiger 1989. p. 766-78.
18. Tateish U, Kusumoto M, Hasegawa T, Yokoyama R and Moriyama N. Primary malignant fibrous histiocytoma of the chest wall: CT and MR appearance. *J Comput Assist Tomogr* 2002;26:558-63.

18. Morris JS, McInnes EF, Bostock DE, Hoather TM, Dobson JM. Immunohistochemical and histopathologic features of 14 malignant fibrous histiocytomas from flat-coated retrievers. *Veterinary Pathology* 2002;39:473-479.
19. Weiss SW, Enzinger FM. Malignant fibrous histiocytoma: An analysis of 200 cases. *Cancer* 1978;41:2250-2266.
20. Cappana R, Bertoni F, Bacchini P, Bacci G, Guerra A, Campanacci M. Malignant fibrous histiocytoma of bone. *Cancer* 1984;54:177-87.
21. Lin X, Zeng S, Yang C, Li C, Yang D. Clinical analysis on 28 cases of head-neck malignant fibrous histiocytoma. *Lin Chung Er Bi Yan Hou Tou Jing Wai Ke Za Zhi* 2009;23:886-93.

How to cite this article: Mahore A, Ramdasi R, Dange N, Epari S. Malignant fibrous histiocytoma of the skull base: A neurosurgical nuance. *Asian J Neurosurg* 2015;10:135-8.

Source of Support: Nil, **Conflict of Interest:** None declared.