

## CASE REPORT

# Vasospasm after intraventricular hemorrhage caused by arteriovenous malformation

Wei-Lung Tseng, Yi-Hsin Tsai<sup>1,2,3</sup>

Department of Surgery, Division of Neurosurgery, National Taiwan University Hospital, <sup>1</sup>Institute of Biomedical Engineering, National Taiwan University, Taipei, <sup>2</sup>Department of Surgery, Division of Neurosurgery, Far Eastern Memorial Hospital, New Taipei City, <sup>3</sup>Department of Surgery, St. Joseph's Hospital, Huwei Township, Yunlin County, Taiwan

## ABSTRACT

Intraventricular hemorrhage (IVH) induced vasospasm is rare in clinical practice. We report a case with vasospasm 10 days after IVH due to thalamic bleeding from an arteriovenous malformation. The vasospasm was so severe that transarterial embolization failed. Follow-up angiography could not reveal the vascular lesion and spontaneous thrombosis was considered. The discussion includes literature review and possible mechanism of such phenomenon. IVH-related vasospasm is rare but should always be kept in mind. Early detection with proper treatment provides better clinical outcome in such cases.

**Key words:** Arteriovenous malformation, intraventricular hemorrhage, vasospasm

## Introduction

Intraventricular hemorrhage (IVH) is a common occurrence in neurosurgeons' regular practice. However, vasospasm following isolated IVH is unusual. There were less than ten cases reported in the literature and the vasospasm usually leads to poor neurological outcomes [Table 1].<sup>[1-6]</sup> We report a case with IVH due to left thalamic hemorrhage from a small arteriovenous malformation (AVM). Severe vasospasm developed 10 days after initial hemorrhage. The event caused prolonged neurological deficits and delayed his treatment of AVM. Relevant literature is reviewed. The Institutional Review Board was contacted regarding use of the case presented below as part of this case report, and it was excused from needing formal approval.

## Case Report

A 37-year-old man with alcoholism was found to have altered consciousness and right side weakness in the afternoon on the day of admission. His history excluded systemic

diseases such as hypertension, diabetes mellitus, and cardiac, pulmonary, hepatic or renal disease. He vomited for several times. Brain computed tomography (CT) at local hospital 4 h after the event showed a left thalamic hemorrhage, 5 ml in amount, and IVH filling all four ventricles with acute hydrocephalus [Figure 1]. He was intubated endotracheally there and transferred to the emergency room of our institute (National Taiwan University Hospital). The Glasgow coma scale upon arrival was E1M4-VT, right hemiplegia was detected. Bilateral pupils were isocoric, 2 mm/2 mm without obvious light reflex. Under the impression of left thalamic intracerebral hemorrhage (ICH) and IVH, external ventricular drainage (EVD) was performed to relieve the hydrocephalus. Urokinase 6000 IU was infused through external ventricular drain intra-operatively to dissolve blood clots. He was then admitted to Intensive Care Unit. The thrombolytic procedure was repeated once a day in the following 3 days, then twice a day for another 4 days. His consciousness returned gradually to partially responsive (E2M6VT). Intermittent fever developed on postevent day 2 and prophylactic antibiotics with ceftriaxone were started though central fever related to clot resolution was also likely. Lumbar drain was inserted on postevent day 7 for continuous drainage of cerebrospinal fluid (CSF) and EVD was removed a week after the insertion.

His consciousness became E2M5VT on day 10 and follow-up perfusion CT showed a small new ICH at left thalamus, residual IVH, marked vasospasm [Figure 2] and a suspicious vascular lesion in the ICH. AVM within the left thalamus was highly suspected. The new hemorrhage is considered being caused by the AVM. Further angiography on day 13 showed an AVM at left thalamus [Figure 3]. An attempt of transarterial embolization on day 14 failed because of the

### Access this article online

#### Quick Response Code:



#### Website:

www.asianjns.org

#### DOI:

10.4103/1793-5482.154984

### Address for correspondence:

Dr. Yi-Hsin Tsai, No. 74, Sinsheng Road, Huwei Township, Yunlin County 63241, Taiwan.  
 E-mail: yihshin1201@gmail.com

vasospasm. The AVM and tiny aneurysm in the left thalamus were no longer detected since opacification of the lesion was blocked by the vasospasm [Figure 4]. Nimodipine and increased hydration were administered for the vasospasm. Low dose norepinephrine was also used to keep systolic blood pressure between 140 and 160 mmHg. The perfusion CT on day 20 showed resolving hematoma in the left thalamus and persistent

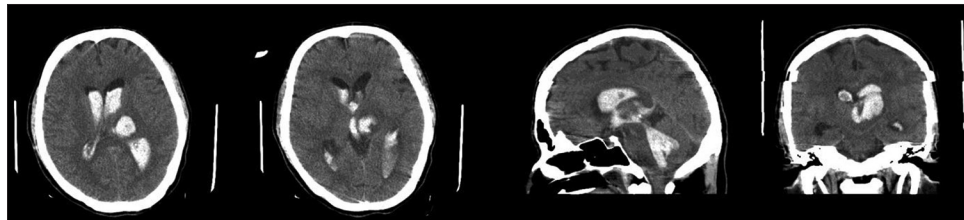
vasospasm, and the thalamic vascular lesion was still not seen. Norepinephrine was tapered off since day 20 and nimodipine was shifted to oral form. He was extubated smoothly 3 weeks after the event, and transferred to the general ward.

Follow-up CT angiography a month after the event still showed no vascular lesion, but the vasospasm improved [Figure 5].

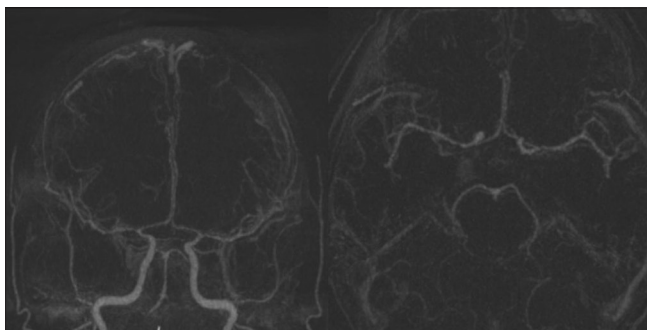
**Table 1: Cases of vasospasm after IVH related vasospasm in the literature review**

	Age/gender	SAH	IVH	Presence of AVM	AVM location	Spetzer-Martin grading	Duration between hemorrhage and vasospasm
Dull and Torbey 2005 <sup>[3]</sup>	44/female	(-)	(+)	(-)			3 days
Gerard <i>et al.</i> 2007 <sup>[2]</sup>	41/female	(-)	(+)	(-)			10 days
Park <i>et al.</i> 2009 <sup>[3]</sup>	40/female	(-)	(+)	(+)	Right thalamus	2	6 days
	14/female	(-)	(+)	(+)	Right basal ganglia	3	17 days
Maeda <i>et al.</i> 1997 <sup>[5]</sup>	31/female	(-)	(+)	(- (arteriovenous fistula))	Right inferior frontal gyrus		13 days
Yanaka <i>et al.</i> 1992 <sup>[5]</sup>	11/female	(-)	(+)	(+)	Left parietal-occipital lobe	2	3 days
Yokobori <i>et al.</i> 2010 <sup>[6]</sup>	33/female	(-)	(+)	(+)	Right parietal lobe	1	17 days

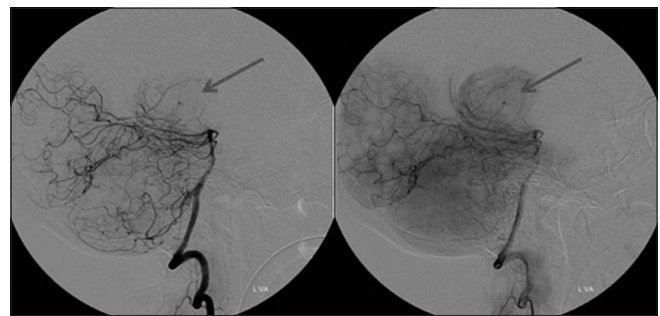
AVM – Arteriovenous malformation; SAH – Subarachnoid hemorrhage; IVH – Intraventricular hemorrhage



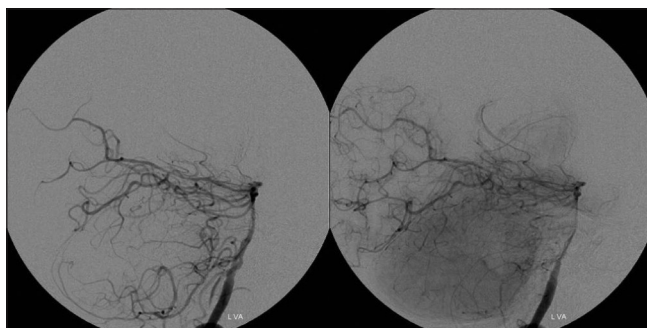
**Figure 1:** The initial brain non-enhanced CT image showing massive intraventricular hemorrhage and left thalamic hemorrhage



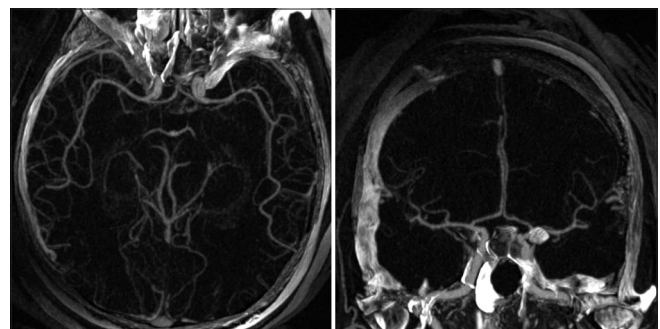
**Figure 2:** Angiography of post-operative day 10 showed diffuse vasospasm



**Figure 3:** Post-operative day 13 angiography showed a small arteriovenous malformation and vasospasm. The embolization was not performed due to vasospasm



**Figure 4:** Post-operative day 14 angiography showed no vascular lesion



**Figure 5:** The CT angiography showed no vascular abnormality or vasospasm a month after the event

Traditional angiography could not detect the vascular lesion either. Spontaneous thrombosis of the AVM was considered. With rehabilitation, his right hemiplegia and speech improved gradually. He led a normal life without any neurological deficit 1-year later.

## Discussion

Vasospasm is a prolonged, sometimes severe, but ultimately reversible narrowing of the cerebral arteries. It usually occurs after an aneurysm-related subarachnoid hemorrhage (SAH). SAH induced by trauma, vascular lesion or tumor bleeding causes vasospasm rarely. Cerebral vasospasm develops between 4 and 12 days after the SAH. When a delayed neurological deficit occurs in a patient with SAH, vasospasm should be considered. Some permanent focal neurological deficits occur after the vasospasm. Thus, early detection followed by proper treatment is crucial.

In the literature, only several case reports demonstrate that IVH related to a ruptured AVM causes vasospasm in the absence of SAH.<sup>[3,4,6,7]</sup> The vasospasm in SAH results from prolonged smooth muscle contraction, which is induced by heme products released from a blood clot.<sup>[8,9]</sup> The cause of IVH-related vasospasm is similar to SAH-induced vasospasm. The main concept is recirculation of heme products into the subarachnoid space after clots within the ventricles dissolve. The products are transported via the CSF and diffuse to the subarachnoid space.<sup>[1]</sup> Maeda *et al.*<sup>[3]</sup> observed delayed occurrence of vasospasm (>14 days after the event) in IVH case and considered it to result from stasis of potentially spasmogenic material due to the poor clearance of CSF. The blood clot within the ventricles may hinder the CSF circulation and lead to delayed fashion of vasospasm.<sup>[6]</sup> In our case, the vasospasm developed on the posthemorrhage day 10, which developed earlier than previous cases. The reason of earlier development of vasospasm in our case might be the thrombolytic therapy with urokinase that facilitated blood clot dissolution and patency of CSF circulation. Ramakrishna *et al.*<sup>[10]</sup> reported that intraventricular tissue plasminogen activator is helpful in the prevention of vasospasm and hydrocephalus after aneurysmal SAH. In our case, vasospasm still occurred even after we gave intraventricular thrombolysis. A proper protocol should be set up for urokinase or recombinant tissue plasminogen activator thrombolysis in IVH patients. Endoscopic evacuation of the intraventricular hematoma has been developed gradually, but the pros and cons of the procedure are not well understood yet.<sup>[11-13]</sup> Further investigation is necessary to define the role of endoscopic surgery in IVH cases. On the other hand, Spader *et al.*<sup>[14]</sup> reported that early fever might be a predictor of vasospasm in IVH cases. Fever occurred on the 2<sup>nd</sup> day after the event in our case, which might be a warning sign of vasospasm. In our case, the vasospasm involved bilateral intracranial internal

carotid artery, vertebral and basilar arteries, which supported the hypothesis of heme product circulating within the CSF.

## Conclusions

Our case emphasizes that vasospasm should always be considered while delayed neurological deficits occur in an IVH case. Early recognition of the vasospasm and close neurological function monitoring are crucial. Any procedures to facilitate the blood clot clearance and to keep heme products from circulating around the brain surface, such as external ventricular drainage or lumbar drainage, may reduce the risk of vasospasm.

## References

1. Dull C, Torbey MT. Cerebral vasospasm associated with intraventricular hemorrhage. *Neurocrit Care* 2005;3:150-2.
2. Gerard E, Frontera JA, Wright CB. Vasospasm and cerebral infarction following isolated intraventricular hemorrhage. *Neurocrit Care* 2007;7:257-9.
3. Maeda K, Kurita H, Nakamura T, Usui M, Tsutsumi K, Morimoto T, *et al.* Occurrence of severe vasospasm following intraventricular hemorrhage from an arteriovenous malformation. Report of two cases. *J Neurosurg* 1997;87:436-9.
4. Park BS, Won YS, Choi CS, Kim BM. Severe symptomatic vasospasm following intraventricular hemorrhage from arteriovenous fistula. *J Korean Neurosurg Soc* 2009;45:300-2.
5. Yanaka K, Hyodo A, Tsuchida Y, Yoshii Y, Nose T. Symptomatic cerebral vasospasm after intraventricular hemorrhage from ruptured arteriovenous malformation. *Surg Neurol* 1992;38:63-7.
6. Yokobori S, Watanabe A, Nakae R, Onda H, Fuse A, Kushimoto S, *et al.* Cerebral vasospasms after intraventricular hemorrhage from an arteriovenous malformation: Case report. *Neurol Med Chir (Tokyo)* 2010;50:320-3.
7. Kothbauer K, Schroth G, Seiler RW, Do DD. Severe symptomatic vasospasm after rupture of an arteriovenous malformation. *AJNR Am J Neuroradiol* 1995;16:1073-5.
8. Pluta RM. Delayed cerebral vasospasm and nitric oxide: Review, new hypothesis, and proposed treatment. *Pharmacol Ther* 2005;105:23-56.
9. Winn HR. *Youmans Neurological Surgery: Expert Consult*. 6<sup>th</sup> ed., Vol. 4. Philadelphia, PA: Saunders/Elsevier; 2011.
10. Ramakrishna R, Sekhar LN, Ramanathan D, Temkin N, Hallam D, Ghodke BV, *et al.* Intraventricular tissue plasminogen activator for the prevention of vasospasm and hydrocephalus after aneurysmal subarachnoid hemorrhage. *Neurosurgery* 2010;67:110-7.
11. Chen HC, Chuang CC, Tzaan WC, Hsu PW. Application of neuroendoscopy in the treatment of obstructive hydrocephalus secondary to hypertensive intraventricular hemorrhage. *Neurol India* 2011;59:861-6.
12. Horváth Z, Veto F, Balás I, Kövér F, Dóczi T. Biportal endoscopic removal of a primary intraventricular hematoma: Case report. *Minim Invasive Neurosurg* 2000;43:4-8.
13. Nishikawa T, Takehira N, Matsumoto A, Kanemoto M, Kang Y, Waga S. Delayed endoscopic intraventricular hemorrhage (IVH) removal and endoscopic third ventriculostomy may not prevent consecutive communicating hydrocephalus if IVH removal was insufficient. *Minim Invasive Neurosurg* 2007;50:209-11.
14. Spader HS, Doberstein CE, Rao AJ, Jayaraman MV. Central fever as an early predictor of vasospasm in a child with isolated intraventricular hemorrhage. *Clin Neurol Neurosurg* 2011;113:146-9.

**How to cite this article:** Tseng WL, Tsai YH. Vasospasm after intraventricular hemorrhage caused by arteriovenous malformation. *Asian J Neurosurg* 2015;10:114-6.

**Source of Support:** Nil, **Conflict of Interest:** None declared.