

The role of awake craniotomy in reducing intraoperative visual field deficits during tumor surgery

Racheal Wolfson, Neil Soni, Ashish H. Shah, Khadil Hosein, Ananth Sastry, Amade Bregy, Ricardo J. Komotar

Department of Neurological Surgery, University of Miami, Florida, USA

ABSTRACT

Objective: Homonymous hemianopia due to damage to the optic radiations or visual cortex is a possible consequence of tumor resection involving the temporal or occipital lobes. The purpose of this review is to present and analyze a series of studies regarding the use of awake craniotomy (AC) to decrease visual field deficits following neurosurgery.

Materials and Methods: A literature search was performed using the Medline and PubMed databases from 1970 and 2014 that compared various uses of AC other than intraoperative motor/somatosensory/language mapping with a focus on visual field mapping.

Results: For the 17 patients analyzed in this study, 14 surgeries resulted in quadrantanopia, 1 in hemianopia, and 2 without visual deficits. Overall, patient satisfaction with AC was high, and AC was a means to reduce surgery-related complications and cost related with the procedure.

Conclusion: AC is a safe and tolerable procedure that can be used effectively to map optic radiations and the visual cortices in order to preserve visual function during resection of tumors infiltrating the temporal and occipital lobes. In the majority of cases, a homonymous hemianopia was prevented and patients were left with a quadrantanopia that did not interfere with daily function.

Key words: Awake craniotomy, novel uses, review

Introduction

Modern awake craniotomy (AC) originated as a means of excising epileptogenic foci and more recently, resecting tumors in functional eloquent cortical regions. It is highly favored as a procedure of defining tumor margins in order to maximize resection while preserving cortical function. AC has been associated with decreased postoperative morbidity, decreased intensive care admissions, and overall length of hospital stay.^[1] Although there has been some concern over potential patient

discomfort and pain intraoperatively, recent studies suggest that AC is well tolerated by carefully selected patients in the proper setting.^[2] Complications during AC are rare but may include obstructive apnea, hypoventilation, nausea, vomiting, and seizures.^[3] In addition, the patient must be capable of understanding and performing the sensory tasks for mapping to be performed. Over the last few years, the technique of AC has been widely developed and studied as more physicians are starting to use this technique for a broader patient population.

A recent search of literature reveals an overwhelming number of articles describing cortical mapping of eloquent areas to elucidate language and motor functioning during AC. Kim *et al.*, studied the outcomes of 309 patients following AC to map the eloquent cortex and reported that negative mapping resulted in a safe margin for resection with a low incidence of neurological deficits.^[4] Similarly, Serletis and Bernstein documented 511 cases of intraoperative brain mapping in the eloquent cortex and concluded that AC is safe and effective for achieving maximum resection of the tumor while avoiding the complications of general anesthesia (GA) such as longer hospital stay, higher cost, and increased morbidity.^[1] However, studies documenting the use of AC to map other functional areas, including the visual cortex and optic radiations, are rare.

Access this article online	
Quick Response Code:	Website: www.asianjns.org
	DOI: 10.4103/1793-5482.161189

Address for correspondence:

Dr. Ricardo J. Komotar, Department of Neurological Surgery, 1321 NW 14th Street, University of Miami Hospital, West Building, Suite 306, Miami, FL 33125, USA.
E-mail: RKomotar@med.miami.edu

Due to the prevalence of postoperative visual field deficits after neurosurgical procedures, exploring the possibility of using intraoperative mapping during AC to preserve visual fields may substantially reduce poor functional outcomes. Several methods are available to measure the activity of the occipital region intraoperatively, which are described with the mapping procedure. The goal of this article is to assess the value of using AC in reduction of visual field deficits after resection of tumors in the temporal or occipital lobe.

Materials and Methods

Study selection

For our review, we searched the Medline database for literature between the years of 1970 and 2014. A combination of the following MeSH terms was used for the search: Craniotomy, brain neoplasms, cerebral neoplasms, supratentorial neoplasms, conscious sedation, brain mapping, electrical stimulation, local anesthesia, length of stay, neuronavigation, time factors, and focal neurological deficit. In addition, an expanded PubMed search including a combination of the following terms was performed: AC, extent of resection, and length of surgery. Only results that included the use of AC for sensory mapping were included for evaluation. The search was limited to studies published in English and humans as subjects.

Only studies that reported patient groups treated with either tumor surgery under GA or awake conditions were included. Articles describing deep brain stimulation as the therapy were excluded. The variables initially selected for analysis included the length of surgery, length of hospital stay, extent of resection, cost, mortality, and neurological morbidity. Cost was later removed from the studied variables because too few studies reported it. All forms of brain neoplasm pathology were included in our analysis to increase the total number of patients in the analysis. Case reports were included in this study as there is insufficient data from randomized control trials to date. No commentaries or reviews were included. The last search was performed October 7, 2014.

Results

Patient selection

Analysis of outcome following AC was done for 17 patients from 4 studies [Table 1]. Included were 13 males and 4 females ranging in age from 22 to 47 with a mean of 37 and a median of 38 years [Table 2].

Tumor characteristics

Fifteen of the patients presented with seizures as the main symptom and a diagnosis of oligodendroglioma, two of which were WHO grade III while the rest were grade II. The remaining two patients carried diagnoses of astrocytoma Grade III presenting with headaches and a low-grade glioma without a preoperative deficit. 10 of the patients had tumors in the right temporal region, and seven patients had tumors on the

left. Tumor deficits, diagnoses, and locations are displayed in Tables 3-5.

Technique

The procedure for mapping the visual cortex followed the same steps as eloquent mapping during craniotomy.^[5] Patients to be considered for the procedure included mentally sound adults without a language barrier or blindness who presented with supratentorial tumors in the visual cortex.^[6] The physician performed preoperative visual testing to assess the patient's function at baseline. In a visual evoked potential test, the patient viewed an alternating checkerboard pattern while electrical signals from the occipital lobe were

Table 1: Studies included for analysis

Study	Number of patients
Gras-Combe <i>et al.</i> 2012	14
Steno <i>et al.</i> 2012	1
Nguyen <i>et al.</i> 2011	1
Duffau <i>et al.</i> 2004	1

Table 2: Patient data

Patient data (n=17)	
Males	13
Females	4
Mean age	37±7
20-29	3
30-39	7
40-49	7

Table 3: Preoperative deficits

Preoperative deficit (n=17)	
Seizure	15
Headache	1
None	1

Table 4: Tumors by type

Tumor diagnosis (n=17)	
Low-grade glioma	14
High-grade glioma	3

Table 5: Tumors by location

Tumor location (n=17)*	
Temporal	8
Occipital	2
Parietal	1
TOJ	7
TPJ	1
TOPJ	3

*Tumors involving more than one location are listed under all associated areas. TOJ – Temporo-occipital junction; TPJ – Temporoparietal junction; TOPJ – Temporo-occipito-parietal junction

recorded [Figure 1]. To test peripheral vision, either a Goldmann visual field test or a Humphrey visual field test was used. In the Goldmann test, the patient focused on a target on a screen three feet away in the center of their visual field. The examiner moved an object toward the target, and the patient signaled




Figure 1: Visual evoked potential. The patient focuses on the target in the center while the checkerboard pattern alternates the black and white squares every half-second. Evoked potentials are recorded using electrodes placed on the scalp




Figure 2: Humphrey visual field test. The target viewed by the patient on the computer screen (a), and the target with a light flash in the peripheral field (b)

when they saw it in their periphery. The Humphrey test used a computer screen on which the patient viewed a central target, and they gave a signal whenever they saw a flash of light in the periphery [Figure 2]. Results of both Goldmann and Humphrey testing are plotted on a graphical representation of the visual field [Figures 3 and 4]. Preoperative imaging and craniotomy preparation were per hospital protocol.

Once the tumor was exposed, a bipolar electrode, such as an Ojemann stimulator, with 5 mm spaced tips and a biphasic current was applied to the brain surrounding the tumor of the awake individual. Previous reports described stimulation between 2 mA and 5 mA.^[7-9] The patient was instructed to note any loss of vision or blurriness during stimulation and the previously described visual field tests were performed. Any area of stimulation that elicited a deficit was marked as a border for the resection. Using this method, the surgeon mapped a safety border for the resection of the tumor. Patients had visual function tested postoperatively as well as at follow-up.

Outcomes

For the 17 patients included for analysis, 14 resulted in a postoperative quadrantanopia at least 3 months after surgery, 1 case resulted in a homonymous hemianopia, and 2 cases did not show any deficit at follow-up [Table 6 and Figure 5].

Discussion

Research into the use of AC for visual function preservation has been sparse. Duffau *et al.*, in 2004 reported the first case of preservation of optic radiations using direct intraoperative detection in a patient undergoing AC for resection of a diffuse invading glioma located at the temporo-occipital junction.^[7] Duffau decided to use intraoperative stimulation to map the subcortex when the patient complained of shadows in her

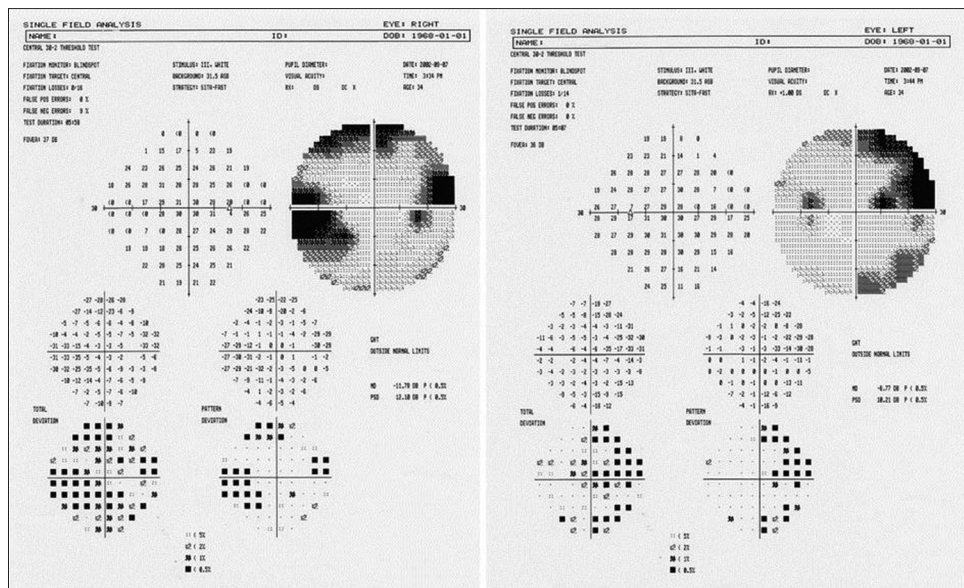


Figure 3: Results of a Humphrey visual field test. Shaded areas are locations of visual field deficit^[22]

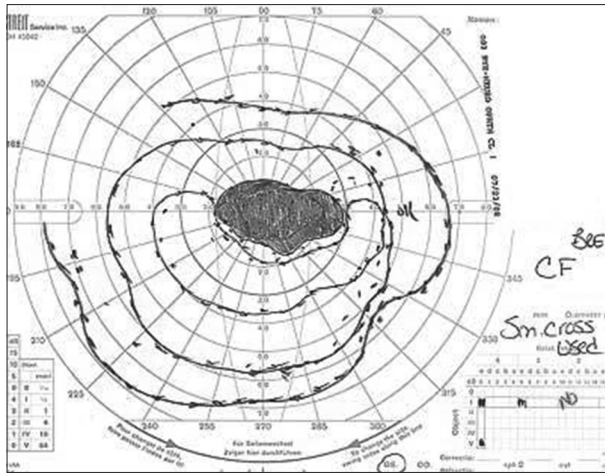


Figure 4: Results of a Goldmann perimetry test. The shading indicates the area of visual deficit^[23]

visual field during surgery. This technique was first performed incidentally, but demonstrated a new possibility for AC. Since then, very few reports have been made on this topic [Table 1].

Lesions involving the visual cortex

Nguyen *et al.*, described a technique to map the visual cortex during AC in a patient with a Grade III astrocytoma in the left medial occipital lobe.^[9] The surgeons decided AC with mapping of the visual cortex was necessary in order to preserve the patient’s vision, which was critical to his occupation as a farmer. In order to assess the visual field during surgery, a screen with a central fixation spot was erected facing the patient during surgery. Red targets on the right half of the screen were used to test the patient’s right hemianopic field, while green targets on the left half served as controls. Using an Ojemann stimulator at 4–5 mA, the neurosurgeons were able to elicit transient loss of vision when stimulating the calcarine cortex around the margin of the tumor and flashing lights in the patient’s right visual with subcortical stimulation. Immediately following surgery, the patient presented with a right inferior quadrantanopia, which resolved after 1-month.

Lesions involving the optic radiations

Based on the procedure described by Nguyen *et al.*,^[9] Šteňo *et al.*, performed resection of a low-grade glioma partially invading the optic radiation of an awake patient.^[10] Using a combination of intraoperative 3D ultrasound and direct electrical stimulation, the surgeons located the optic radiation and resected 97% of the macroscopic tumor. Similar to other cases, the patient presented with a postoperative partial quadrantanopia. The authors state that though they avoided a homonymous hemianopia, they were unable to completely avoid a visual field defect likely because the initial presentation of the defect during surgery may be unnoticed by the patient. They conclude that the result of this operation was satisfactory, as the patient did not report any change in visual function postoperatively and the quadrantanopia was only detectable through automated perimetry.

Table 6: Postoperative results

Postoperative deficit (n=17) ^a	
Left superior quadrantanopia	8
Left inferior quadrantanopia	2
Right superior quadrantanopia	4
Right hemianopia	1
None	2

^aAt 3+ months postsurgery

Another study in 2012 by Gras-Combe *et al.*, focused on subcortical stimulation in order to map optic radiations in 14 patients with gliomas involving visual pathways.^[8] They used a picture-naming task during subcortical stimulation with bipolar electrodes at a mean of 2.7 mA in order to localize the optic radiations. A disturbance caused by stimulation resulted in the inability to see and identify the picture in the affected quadrant. In this way, the surgeons were able to define the safe margin for resection. All patients experienced positive visual mapping symptoms during surgery. Quadrantanopia was observed in 13 of the 14 patients following surgical resection with 1 patient experiencing partial improvement of visual deficits.

Benefits of awake craniotomy

Studies on the use of AC for eloquent mapping have long argued that the procedure allows for maximal resection of these tumors.^[4,1,11,12] In addition, patients are comfortable with the idea of AC and generally perceive the experience as positive.^[13,2] The procedure is associated with reduced resource utilization by hospitals, low complications, low mortality rates, and decreased length of stay postoperatively and has the added benefit of avoiding the complications of GA.^[1,13] Because of the many benefits of AC, its use in noneloquent regions of the brain should be further explored.

Based on the articles reviewed, it is possible to map the visual cortex and optic radiations intraoperatively using electrical stimulation. For patients, this means that postoperative visual deficits may become less likely in the future. Surgeries involving the temporo-parieto-occipital junction have historically had a high risk of resulting in permanent homonymous hemianopsia, but recent reports demonstrate the ability to reduce the visual deficits to a quadrantanopia.^[7] This allows patients to maintain a normal lifestyle, as they are oftentimes unaware of the deficit and it is usually not considered disabling.^[14,8]

Nguyen *et al.*, conclude that intraoperative visual field mapping may be of limited use as many patients with tumors around the visual cortex present with visual deficits prior to surgery, but the prospect of preserving all visual function must be further researched.^[9] It is also likely that the quadrantanopias in previous reports were unavoidable due to the location of the tumors. In prior studies, positive cortical mapping has been associated with a higher risk of postoperative neurological

deficits.^[13,4] This is likely due to the fact that eliciting a positive response via electrical stimulation indicates the presence of a functional area in close proximity to the tumor margin.^[4] The conclusion drawn from previous studies is that negative mapping is associated with a decreased risk of postoperative deficits,^[13,4,5] and cortical mapping has proven to be statistically significant in predicting the neurological outcome.^[4]

Combining what is known about traditional cortical mapping of eloquent areas during AC with recent reports about mapping noneloquent areas, two conclusions come forward. First, electrical stimulation of the visual cortex and optic radiations during AC is an effective way of reducing postoperative neurological deficits and maintaining the patient's quality of life. Second, negative mapping may result in the elimination of visual deficits altogether. Because visual disturbances were elicited near the tumor margin during surgery, the risk of a visual deficit such as a quadrantanopia was high.^[7,9,8]

While it is important to preserve the patient's quality of life, Gras-Combe *et al.*, speculate that visual function mapping is neglected because the risk of leaving residual tumor outweighs the benefit of preventing homonymous hemianopia.^[8] The question of visual function preservation is especially important in younger patients, as the difference between a homonymous hemianopia and a quadrantanopia can be the difference between passing or failing a driving test depending on the country.^[14,8,15]

In addition to using cortical mapping to reduce visual deficits, AC could possibly prevent olfactory deficits such as anosmia and ageusia. Though such postoperative deficits are rare, they are associated with higher incidences of depression and decreased the quality of life.^[16] No studies have been done to date on the use of AC and electrical stimulation to functionally map the olfactory and gustatory systems. The majority of what is known about these functions is based on anatomical and neuroimaging studies.^[17] Because of the severe decrease in quality of life caused by olfactory deficits, this area warrants research into the functional anatomy of these systems during surgery in order to prevent such deficits in the future.

Recently, imaging techniques such as diffuse tensor imaging, functional magnetic resonance (MR) imaging, and conventional MR have widespread use during surgery, but they lack the ability to detect functionality intraoperatively.^[8,13,11] These imaging methods are useful in demonstrating the anatomy of the individual, but cannot be relied on to avoid functional deficits. In addition, it has been shown that conventional MR images underestimate the actual extent of low-grade gliomas.^[12] It is widely accepted that a greater extent of resection leads to better neuro-oncological outcomes, and this along with decreased morbidity can be achieved using a combination of individualized preoperative

imaging and intraoperative stimulation and awake functional mapping.^[18,11]

Despite the use of AC and functional mapping to prevent unnecessary neurological deficits, there are still reports of sporadic deficits arising postoperatively without positive findings during intraoperative stimulation.^[19] In fact, one report states that the frequency of deficits following procedures with language mapping is the same as procedures without mapping.^[20] However, because AC is a safe and well-tolerated procedure,^[2] its usefulness in identifying essential cortical and subcortical areas cannot should be further explored to include nonlanguage mapping.^[14]

Future applications

A case report by Ribas and Duffau details a different set of problems that can arise following glioma resection: Postoperative permanent anosmia and ageusia, an extremely rare complication.^[17] In a patient with no prior history of the chemosensory disorder, anosmia and ageusia developed following resection of a low-grade glioma invading the left temporo-insular region. During surgery, mapping of the cortex was performed for eloquent areas. The authors add that no olfactory or gustatory sensations were elicited, but as that was not the focus of their mapping, it is unlikely any sensations would have been noted had they occurred. In this case, the frontal lobe was not retracted during surgery and the olfactory tract was not visualized, so the deficits are likely due to damage to the cortex and central pathways involved in olfaction and gustation.

However rare such complications may be, anosmia and ageusia can have crippling effects on quality of life.^[21,16] While little attention has historically been paid to olfaction and gustation, it is worth exploring due to the detrimental consequences of olfactory disorders. The authors of the previous case report cite multiple neuroimaging studies, but the next step would be functional mapping during resection of tumors affecting the frontotemporal region.

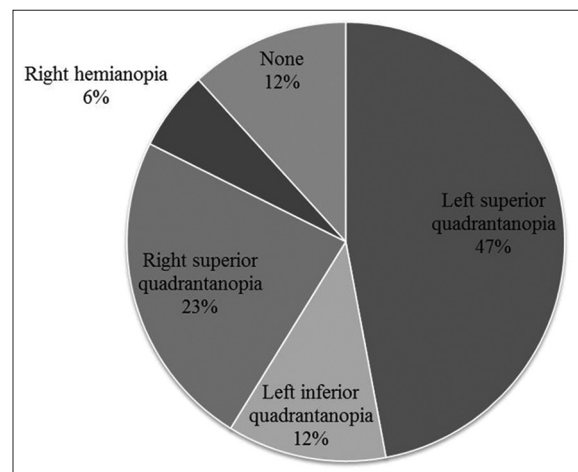


Figure 5: Postoperative results graph

Conclusion

Awake craniotomy has been used for many years in the mapping of language and motor areas, but its use has rarely been explored for visual and olfactory functions. Because deficits to such areas can have a large impact on the patient's quality of life, preservation of function should be a priority in resection of tumors invading olfactory, gustatory, and visual tracts. Despite the limited research involving such novel uses of AC, its use in preventing severe visual deficits is promising. Intraoperative mapping of visual function should be performed more often in order to develop a way to prevent visual deficits altogether.

References

- Serletis D, Bernstein M. Prospective study of awake craniotomy used routinely and nonselectively for supratentorial tumors. *J Neurosurg* 2007;107:1-6.
- Khu KJ, Doglietto F, Radovanovic I, Taleb F, Mendelsohn D, Zadeh G, *et al.* Patients' perceptions of awake and outpatient craniotomy for brain tumor: A qualitative study. *J Neurosurg* 2010;112:1056-60.
- Bonhomme V, Franssen C, Hans P. Awake craniotomy. *Eur J Anaesthesiol* 2009;26:906-12.
- Kim SS, McCutcheon IE, Suki D, Weinberg JS, Sawaya R, Lang FF, *et al.* Awake craniotomy for brain tumors near eloquent cortex: Correlation of intraoperative cortical mapping with neurological outcomes in 309 consecutive patients. *Neurosurgery* 2009;64:836-45.
- Brydges G, Atkinson R, Perry MJ, Hurst D, Laqua T, Wiemers J. Awake craniotomy: A practice overview. *AANA J* 2012;80:61-8.
- Dreier JD, Williams B, Mangar D, Camporesi EM. Patients selection for awake neurosurgery. *HSR Proc Intensive Care Cardiovasc Anesth* 2009;1:19-27.
- Duffau H, Velut S, Mitchell MC, Gatignol P, Capelle L. Intra-operative mapping of the subcortical visual pathways using direct electrical stimulations. *Acta Neurochir (Wien)* 2004;146:265-9.
- Gras-Combe G, Moritz-Gasser S, Herbet G, Duffau H. Intraoperative subcortical electrical mapping of optic radiations in awake surgery for glioma involving visual pathways. *J Neurosurg* 2012;117:466-73.
- Nguyen HS, Sundaram SV, Mosier KM, Cohen-Gadol AA. A method to map the visual cortex during an awake craniotomy. *J Neurosurg* 2011;114:922-6.
- Šteno A, Karlik M, Mendel P, Cik M, Šteno J. Navigated three-dimensional intraoperative ultrasound-guided awake resection of low-grade glioma partially infiltrating optic radiation. *Acta Neurochir (Wien)* 2012;154:1255-62.
- Wilden JA, Voorhies J, Mosier KM, O'Neill DP, Cohen-Gadol AA. Strategies to maximize resection of complex, or high surgical risk, low-grade gliomas. *Neurosurg Focus* 2013;34:E5.
- Yordanova YN, Moritz-Gasser S, Duffau H. Awake surgery for WHO Grade II gliomas within "noneloquent" areas in the left dominant hemisphere: Toward a "supratotal" resection. *Clinical article. J Neurosurg* 2011;115:232-9.
- Ilmberger J, Ruge M, Kreth FW, Briegel J, Reulen HJ, Tonn JC. Intraoperative mapping of language functions: A longitudinal neurolinguistic analysis. *J Neurosurg* 2008;109:583-92.
- Duffau H. Awake surgery for nonlanguage mapping. *Neurosurgery* 2010;66:523-8.
- Manji H, Plant GT. Epilepsy surgery, visual fields, and driving: A study of the visual field criteria for driving in patients after temporal lobe epilepsy surgery with a comparison of Goldmann and Esterman perimetry. *J Neurol Neurosurg Psychiatry* 2000;68:80-2.
- Miwa T, Furukawa M, Tsukatani T, Costanzo RM, DiNardo LJ, Reiter ER. Impact of olfactory impairment on quality of life and disability. *Arch Otolaryngol Head Neck Surg* 2001;127:497-503.
- Ribas ES, Duffau H. Permanent anosmia and ageusia after resection of a left temporoinsular low-grade glioma: Anatomofunctional considerations. *J Neurosurg* 2012;116:1007-13.
- De Benedictis A, Moritz-Gasser S, Duffau H. Awake mapping optimizes the extent of resection for low-grade gliomas in eloquent areas. *Neurosurgery* 2010;66:1074-84.
- Kurimoto M, Takaiwa A, Nagai S, Hayashi N, Endo S. Anomia for people's names after left anterior temporal lobe resection – Case report. *Neurol Med Chir (Tokyo)* 2010;50:36-40.
- Hermann BP, Wyler AR, Somes G, Clement L. Dysnomia after left anterior temporal lobectomy without functional mapping: Frequency and correlates. *Neurosurgery* 1994;35:52-6.
- Gopinath B, Anstey KJ, Sue CM, Kifley A, Mitchell P. Olfactory impairment in older adults is associated with depressive symptoms and poorer quality of life scores. *Am J Geriatr Psychiatry* 2011;19:830-4.
- Pham L, Lee A. Communicating with patients about alternative therapies: A case of optic nerve hypoplasia 2008. Available from <http://www.eyetounds.org/cases/88-professionalism-alternative-therapies.htm>. [Last accessed on 2015 May 21].
- Inoue K, Hashida S, Tajima Y, Wakakura M, Tomita G. Progression of visual field defect in a normal-tension glaucoma patient after laser in situ keratomileusis. *Eye* 2004;18:850-3.

How to cite this article: Wolfson R, Soni N, Shah AH, Hosein K, Sastry A, Bregy A, *et al.* The role of awake craniotomy in reducing intraoperative visual field deficits during tumor surgery. *Asian J Neurosurg* 2015;10:139-44.

Source of Support: Nil, **Conflict of Interest:** None declared.