

## CASE REPORT

# Shunt tube calcification as a late complication of ventriculoperitoneal shunting

Abubakr Darrag Salim, Mohammed Awad Elzain, Haddab Ahmed Mohamed, Baha Eldin Mohamed Ibrahim Zayan

Department of Neurosurgery, National Center of Neurological Sciences, Khartoum, Sudan

## ABSTRACT

Shunt calcification is a rare complication of ventriculoperitoneal shunting that occurs years later after the initial operation this condition is rarely reported in literature. Two patients with shunt calcifications were described. The first patient was 17-year-old lady who had congenital hydrocephalus and shunted in the early infancy, she was presented recently complaining of itching of the skin along the shunt track and limitation of neck movement. The patient was then operated with removal of the old peritoneal catheter and replacing it with a new one. The second patient was 17-year-old boy originally was a case of posterior fossa pilocytic astrocytoma associated with obstructive hydrocephalus, he was operated with both shunting for the hydrocephalus and tumor removal, 6 years later he presented with shunt exposure. Calcification of the shunt tube was discovered intraoperatively upon shunt removal. Shunt calcification has been observed mainly in barium-impregnated catheters. Introducing plain silicone-coated shunt tubing may reduce the rate of this condition. The usual complaints of the patients suffering from this condition are pain in the neck and chest wall along the shunt pathway and limitation of the neck movement due to shunt tube tethering, but features of shunt dysfunction and skin irritation above the shunt may be present. In this review, plain X-ray and operative findings showed that the most extensive calcification is present in the neck, where the catheters were subject to heavy mechanical stress. Disturbed calcium and phosphate metabolisms may be involved in this condition. Shunt calcification is a rare condition that occurs due to material aging presenting with features of shunt tethering, dysfunction or overlying skin irritation. Plain X-ray is needed to detect calcification while shunt removal, replacement or endoscopic third ventriculostomy may carry solution for this condition.

**Key words:** Barium-impregnated catheters, calcification, shunt complications

## Introduction

Ventriculoperitoneal (VP) shunting for hydrocephalus is one of the most commonly performed neurosurgical procedures that is used for the treatment of hydrocephalus. The complications of shunting procedures such as shunt infection, dysfunction or penetration are common and may lead to failure of the procedure necessitating shunt removal in most of the patients and instant or late reinsertion of a new device is usually indicated.

Calcification of the shunt tube has been recognized as one of the rare shunt complications. A study done in 1988 has reported the incidence of shunt tube calcification in 16-year-old boy who presented complaining of neck pain, chest pain and fever of unknown etiology. Both fever and pain subsided following removal of the shunt tube; the authors concluded that the use of silicone shunt tube may induce connective tissue proliferation.<sup>[1]</sup>

Stannard and Rollins, in 1995 reported three patients who developed dystrophic calcification of the shunt catheter at the thoracic inlet that was associated with shunt disconnection in two patients.<sup>[2]</sup>

In a published review of 64 cases with shunt calcification, Boch *et al.* in 1995 concluded that shunt calcification is a late complication and appears to be partly related to aging of the shunt tube material.<sup>[3]</sup>

Cakir *et al.* in 2004 reported 16-year-old girl presented with shunt malfunction due to calcification, he reported that the attempt of removal of the calcified catheter has resulted in shunt rupture and he recommended replacement of the calcified shunt with a new one and avoidance of aggressive surgical attempts to remove the calcified shunt.<sup>[4]</sup>

### Access this article online

#### Quick Response Code:



#### Website:

[www.asianjns.org](http://www.asianjns.org)

#### DOI:

10.4103/1793-5482.161321

### Address for correspondence:

Dr. Mohammed Awad Elzain, Department of Neurosurgery, National Center of Neurological Sciences, Khartoum, Sudan.  
 E-mail: [alkarsani@yahoo.com](mailto:alkarsani@yahoo.com), [dr.alkarsani@gmail.com](mailto:dr.alkarsani@gmail.com)

Sakai *et al.* in 2004 reported 53-year-old man with renal failure who developed dense calcifications at the proximal end of the ventricular catheter of the VP shunt and the ventricular wall, he concluded that disturbed calcium and phosphate metabolisms associated with renal failure may have been involved in this abnormal calcification of the ventricle wall.<sup>[5]</sup>

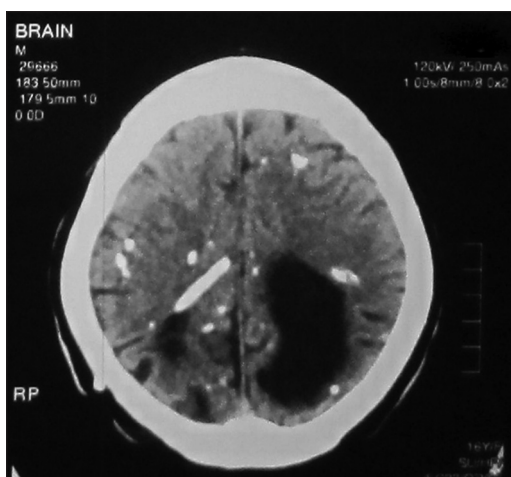
In a recent paper published in 2012, Kural *et al.* reported 10-year-old boy who had ventriculoperitoneal shunt operation when he was 10 days old, the patient presented later with shunt dysfunction due to shunt calcification and rupture. They reported that the shunt tube calcification can occur in spite of normal blood calcium and phosphorus levels; this is attributed mainly to the altered cellular metabolism and the quality of the shunt tube used.<sup>[6]</sup>

## Cases Reports

### Case no. 1

The first patient was 17-year-old lady who was known to have hydrocephalus since early childhood. She has undergone the operation of VP shunting and revisions many times; the last procedure was done in 2007. Since that time she was quite well, in the last 6 months she started to complain of headache, vertigo, skin changes over the shunt track mainly in a form of burning sensation and itching, neck pain, and abnormal eyes gaze. On examination, she was quite well, and she had no neurological deficits. Examination of her neck revealed solid, tender thickening of the soft tissues around shunt pathway, spanning the whole neck with marked skin thickening against the clavicle. The shunt tube was stuck to the surrounding tissues with some degree of tethering. Neck movement was limited by the pain, but the shunt was functioning.

Her CT scan of the brain [Figure 1] showed slightly dilated left lateral ventricle. The ventricular catheter was well placed inside the ventricle, but there were calcifications



**Figure 1:** Computed tomography of the first patient showing calcification scattered in the brain with properly sited ventricular catheter and slightly dilated left lateral ventricle

scattered in the cerebral matter. Her serum calcium was (11.1 mg/dL) and her serum phosphate was (4.3 mg/dL). Shunt view X-ray [Figure 2], showed some calcification around the shunt tube. Shunt revision was decided in fear of shunt penetration as the patient was continuously scratching the skin overlying the shunt track. A new abdominal catheter was inserted and was then fixed to the valve-ventricular catheter complex. Following the procedure, the patient was relieved from itching, pain and neck movement limitation [Figure 3].

### Case no. 2

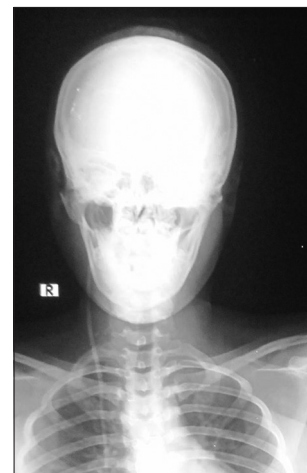The second patient was 17-year-old student from Western Sudan. He was a known case of posterior fossa tumor with secondary obstructive hydrocephalus. He has been initially operated with VP shunting followed by posterior fossa craniectomy and tumor resection.

The histopathology was pilocytic astrocytoma. He was followed-up for 4 years during which he was quite well without any complaints or neurological dysfunction. Follow-up was then neglected by the patient till he presented again 2 weeks prior to operation with shunt penetration through the scalp [Figure 4].

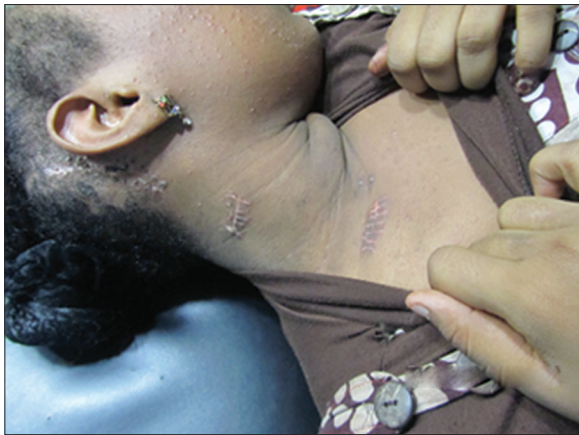MRI showed no tumor in the posterior fossa and no active hydrocephalus [Figure 5], so he was planned for shunt removal. His serum calcium was (6.8 mg/dL) and his serum phosphate was (3.7 mg/dL). During the operation, the shunt was found to be stuck to the subcutaneous tissue with calcified fibrous adhesions along the shunt tube track. Multiple transverse skin incisions and subcutaneous dissections were made to remove the shunt [Figures 6 and 7]. Both ventricular and abdominal catheters were removed without difficulty.

## Discussion

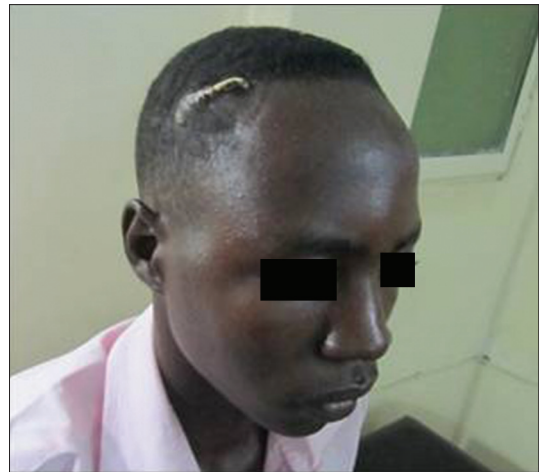Calcification of the shunt tube pathway and related dysfunction of VP shunts are rare events in neurosurgical practice. Very



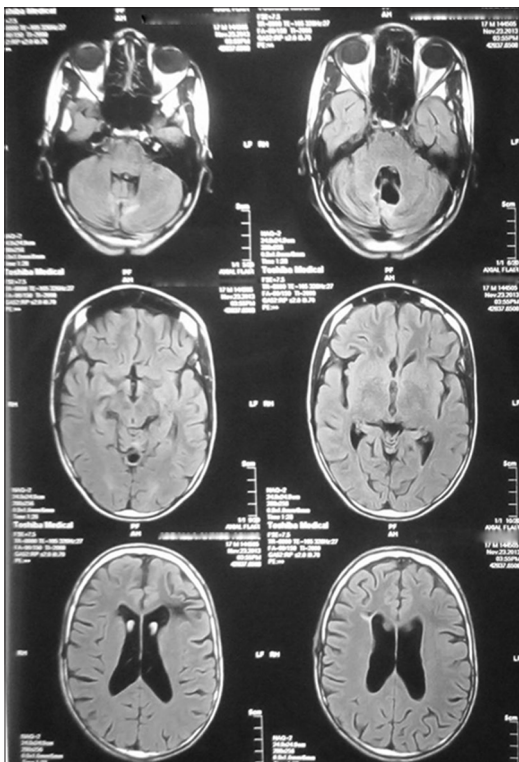
**Figure 2:** Plain X-ray of the first patient showing calcification around the shunt tube in the neck



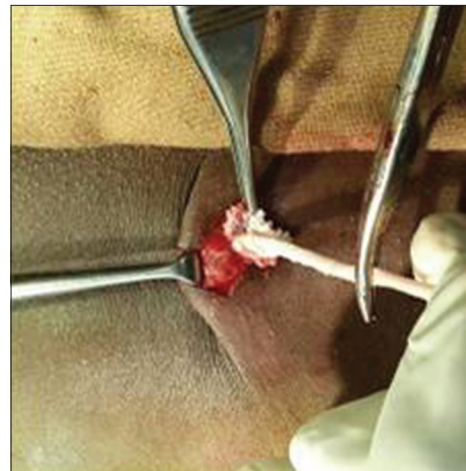**Figure 3:** The scars in the head and neck of the first patient following surgery



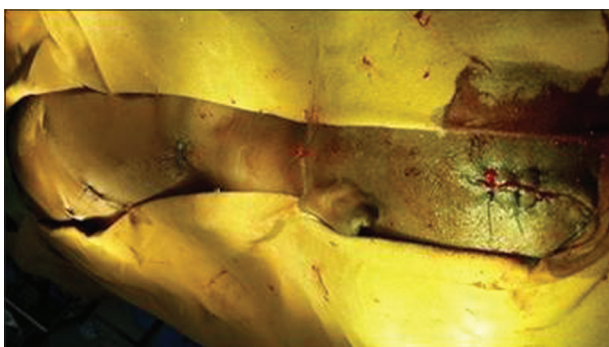**Figure 4:** The second patient, with the shunt penetrating through the scalp



**Figure 5:** Magnetic resonance imaging of the second patient, with no evidence of posterior fossa tumor or hydrocephalus



**Figure 6:** Calcification and fibrosis along shunt pathway during the surgery of shunt removal of the second patient



**Figure 7:** Multiple incisions closed after shunt removal of the second patient

few cases of shunt rupture and calcification were reported in literature, and these conditions usually occur as a long-term complication of VP shunting.

Catheter material degradation and mineral deposits of calcium and other minerals on the shunt catheters may lead to fracture or migration of the system. Shunt calcification may cause shunt dysfunction in two ways, either through disconnection or obstruction. These are mostly due to tethering of the shunt tube. Barium sulfate admixed with silicone during the manufacturing process of the shunt tube may accelerate late complications owing to the formation of cracks in the catheters and by enhancing the nucleation rate. Late complications appear to be partially related to aging of the shunt material.<sup>[2,3,7]</sup>

Calcification was observed mainly in barium-impregnated catheters. Introducing plain silicone-coated shunt tubing may reduce the rate of this condition.<sup>[3]</sup>



The usual complaints of the patients suffering from this condition are pain in the neck and chest wall along shunt track and limitation of neck movements as a result of shunt tube tethering. In addition, features of shunt dysfunction and skin irritation above the shunt may also be present.

Plain X-rays (shunt view X-rays) should be performed to detect any possible calcification around the shunt tube. Spectroscopy and conventional histology should also be performed.<sup>[7]</sup> In this report, plain X-ray and operative findings showed that the most extensive calcification was present in the neck, where the catheters were subject to heavy mechanical stress.

Disturbed calcium and phosphate metabolisms associated with renal failure may have been involved in this abnormal calcification.<sup>[5]</sup>

## Conclusion

Shunt calcification is a rare condition that occurs due to material aging. It may present with features of shunt tethering, dysfunction or irritation. Plain X-ray is needed to detect calcification while shunt removal, with subsequent shunt replacement or endoscopic third ventriculostomy, may be considered for the management of this condition.

## References

1. Shimotake K, Kondo A, Aoyama I, Nin K, Tashiro Y, Nishioka T. Calcification of a ventriculoperitoneal shunt tube. Case report. *Surg Neurol* 1988;30:156-8.
2. Stannard MW, Rollins NK. Subcutaneous catheter calcification in ventriculoperitoneal shunts. *AJNR Am J Neuroradiol* 1995;16:1276-8.
3. Boch AL, Hermelin E, Sainte-Rose C, Sgouros S. Mechanical dysfunction of ventriculoperitoneal shunts caused by calcification of the silicone rubber catheter. *J Neurosurg* 1998;88:975-82.
4. Cakir E, Kuzeyli K, Usul H, Peksoylu B, Karaarslan G, Yildiz K. Shunt dysfunction due to calcification of a ventriculo-peritoneal shunt: A case report. *J Clin Neurosci* 2004;11:210-1.
5. Sakai S, Akai T, Iida T, Iizuka H. Calcification on the ventricle wall associated with a shunt tube – case report. *Neurol Med Chir (Tokyo)* 2004;44:674-6.
6. Kural C, Kirik A, Pusat S, Senturk T, Izci Y. Late calcification and rupture: A rare complication of ventriculoperitoneal shunting. *Turk Neurosurg* 2012;22:779-82.
7. Yamamoto S, Ohno K, Aoyagi M, Ichinose S, Hirakawa K. Calcific deposits on degraded shunt catheters: Long-term follow-up of V-P shunts and late complications in three cases. *Childs Nerv Syst* 2002;18:19-25.

**How to cite this article:** Salim AD, Elzain MA, Mohamed HA, Ibrahim Zayan BE. Shunt tube calcification as a late complication of ventriculoperitoneal shunting. *Asian J Neurosurg* 2015;10:246-9.  
**Source of Support:** Nil, **Conflict of Interest:** None declared.