

## Single Stage Complete Removal of Dumbbell Trigeminal Schwannoma in a Child by Skull Base Approach

### Abstract

Trigeminal schwannomas (TSs) are extremely rare tumors in childhood, particularly in the absence of neurofibromatosis. Although multi-staged surgical strategies have been reported in the literature, safe and single stage microsurgical removal is possible. We report a rare case of dumbbell TS, in a 9-year-old girl in whom single stage complete removal was done using fronto-temporo-orbito-zygomatic craniotomy and sub temporal approach.

**Keywords:** Child, dumbbell tumor, skull base approach, trigeminal schwannoma

### Introduction

Trigeminal schwannomas (TSs) are rare tumors, accounting for between 0.07% and 0.36% of all intracranial tumors and 0.8% and 8% of intracranial schwannomas.<sup>[1-5]</sup> The trigeminal nerve (TN) is the second most common intracranial site of occurrence after vestibular nerve origin.<sup>[5]</sup> Frequently seen in the fourth–fifth decades of life, TS in childhood is extremely rare, even rarer is their occurrence in childhood, in the absence of neurofibromatosis (NF), only five such cases have been described in literature.<sup>[1-7]</sup> All literature that describes surgical approaches for these tumors is mostly confined to adults.<sup>[3-5]</sup> The rarity of these tumors in childhood and their multi-compartmental extensions pose a unique challenge that needs to be understood. Several authors have described staged surgery for such childhood tumors.<sup>[1,6,7]</sup> In this report, we highlight the clinical and radiological findings of this relatively rare pediatric tumor with a special attention on single staged skull base surgical approach and good outcome.

### Case Report

A 9-year-old female presented with drooling of saliva from the right angle of mouth for 2 months, associated with facial asymmetry. She often complained of intermittent mild headaches and blurring of vision. Neurological examination revealed right-sided involvement of V, VI, VII, and VIII cranial nerves, right-sided

cerebellar signs, and right hemi paresis of MRC grade 4/5. There were neither cutaneous markers nor any family history of NF (genetic testing not done). Magnetic resonance imaging brain showed a well-circumscribed dumbbell-shaped mass lesion centered over Meckel's cave and extending into the right middle and posterior fossa up to the seventh–eighth nerve complex. The tumor appeared isointense on T1-weighted images, hyperintense on T2-weighted images, and intensely enhancing on contrast administration. There was compression of left temporal lobe and the brainstem with mild ventriculomegaly [Figure 1].

### Surgical technique

A fronto-temporo-orbito-zygomatic (FTOZ) craniotomy was performed. Dura opened in a curvilinear fashion and tumor bulge was visible beneath the dura propria of the middle fossa base in the interdural plane, which was opened linearly in the anteroposterior direction. The tumor was extending medially toward the cavernous sinus without infiltration; hence, it could be easily peeled off from the lateral wall of the sinus. It was also eroding the petrous apex, thereby widening the porus trigeminus and extending into the posterior fossa until the internal acoustic meatus without actually involving these nerves. The TN was flattened and splayed by the tumor with the mandibular division suffering the maximum damage. Intracapsular debulking

**Ramesh  
Sharanappa  
Doddamani,  
Rajesh Kumar  
Meena,  
Selvam Murali  
Mohan,  
Neelam Krishnan  
Venkatramanaa**

*Department of Neurosurgery,  
BGS Global Institute of  
Neurosciences, Bengaluru,  
Karnataka, India*

### Address for correspondence:

*Dr. Neelam Krishnan  
Venkatramanaa,  
Department of Neurosurgery,  
BGS Global Institute of  
Neurosciences,  
Bengaluru - 560 060,  
Karnataka, India.  
E-mail: drnkvr@gmail.com*

### Access this article online

**Website:** www.asianjns.org

**DOI:** 10.4103/1793-5482.175633

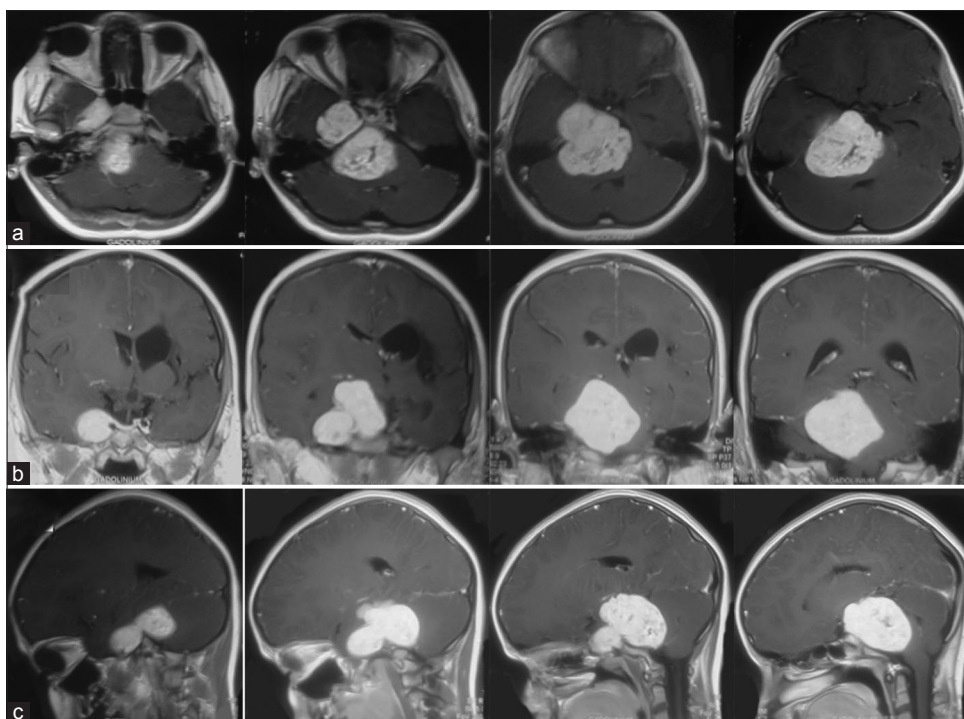
### Quick Response Code:



**How to cite this article:** Doddamani RS, Meena RK, Mohan SM, Venkatramanaa NK. Single stage complete removal of dumbbell trigeminal schwannoma in a child by skull base approach. Asian J Neurosurg 2018;13:136-9.

This is an open access article distributed under the terms of the Creative Commons Attribution-NonCommercial-ShareAlike 3.0 License, which allows others to remix, tweak, and build upon the work non-commercially, as long as the author is credited and the new creations are licensed under the identical terms.

**For reprints contact:** reprints@medknow.com



**Figure 1: Preoperative contrast-enhanced magnetic resonance imaging (a) axial (b) coronal (c) sagittal images demonstrating intensely contrast enhancing large tumor occupying the middle fossa, lateral wall of cavernous sinus, Meckel's cave, porus trigeminus, and posterior fossa**

of the middle fossa component was initially done. This was followed by complete removal of the tumor including the capsule by following it into the posterior fossa through the widened porus. Sectioning of the tentorium cerebelli was not required. The tumor was grayish, fleshy, suckable, and vascular. Watertight dural closure was achieved. Histopathology revealed whorls of spindle-shaped cells suggestive of a schwannoma. Postoperative period was uneventful without added deficits; postoperative noncontrast computerized tomography head showed complete removal of the tumor [Figure 2].

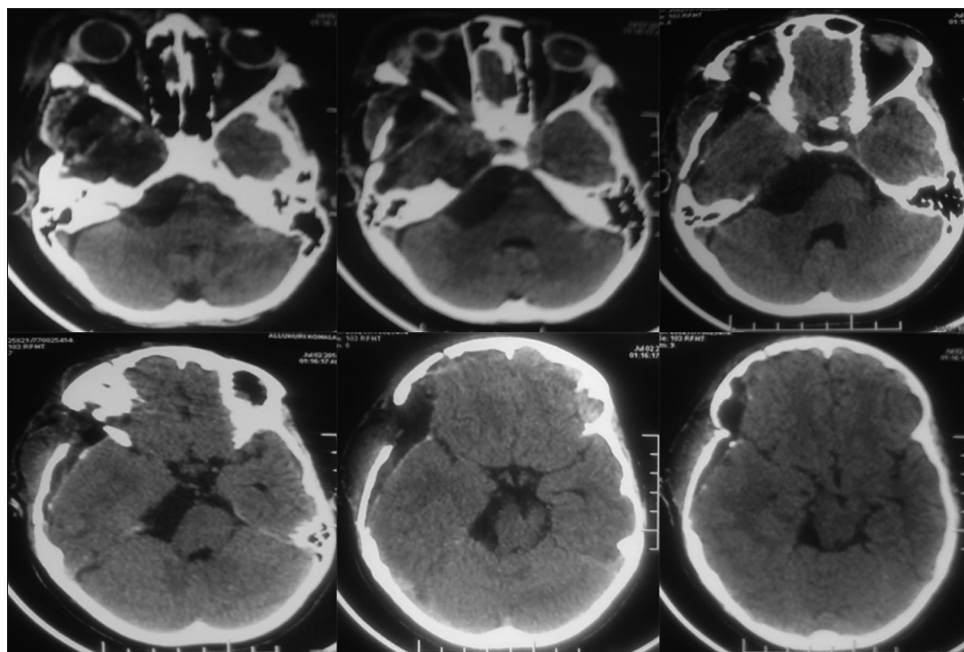
## Discussion

TSs are rare tumors in childhood particularly in the absence of NF.<sup>[1-7]</sup> These tumors arise and spread along the divisions of the nerve extending into multiple cranial compartments.<sup>[8-10]</sup> In 1955, Jefferson categorized these tumors into the following 3 types: Type A, tumors of the gasserian ganglion in the middle cranial fossa; type B, tumors of the roots of the TN in the posterior fossa; and type C, the so-called hourglass tumors occupying both the middle and posterior fossae. Some authors added a fourth classification, type D, for tumors with an extra cranial extension.<sup>[2-4]</sup>

Our patient evidently did have a type C dumbbell-shaped tumor, the complete excision of which is considered to be most difficult. Conventionally, TSs have been resected by pterional transsylvian, subtemporal interdural, frontotemporal interdural, subtemporal transtentorial, and frontotemporal

extradural approaches. These approaches though provide sufficient exposure for tumor resection, require significant brain retraction to expose the tumor and sacrifice of bridging veins.<sup>[10]</sup> A variety of approaches have evolved and refined over a time period with better understanding of anatomy and advances in microneurosurgery. These skull-based approaches include anterior transpetrosal interdural approach using orbitozygomatic osteotomy and subtemporal extradural corridor using zygomatic osteotomy. Cranial-orbital-zygomatic, petrosal, and combined petrosal approaches have been reported to result in satisfactory surgical results. However, combined approaches (e.g., cranial-orbital-zygomatic and anterior transpetrosal approaches or subtemporal and suboccipital approaches) carry the risk of venous injury and injury from excessive retraction.<sup>[10-13]</sup>

These dumbbell tumors can be approached, either by a single or staged surgery. Most authors do advocate two stage surgeries for safe and complete removal. In the two stage surgery, the middle fossa tumor is removed by either of the above-mentioned approaches followed by separate retromastoid retrosigmoid approach for the posterior fossa component. Dumbbell tumors extending beyond the seventh–eighth complex and reaching until the lower brainstem are difficult to remove in one stage and may require multiple sittings.<sup>[1,13,14]</sup> However, the total surgical removal of large, multi-compartmental tumor may be achieved through a surgical approach from a single cranial fossa aided by soft internal consistency of the tumor, expanded Meckel's cave and convenient cleavage planes.



**Figure 2:** Postoperative noncontrast computerized tomography head demonstrating complete removal of tumor after a single stage excision by fronto-temporo-orbito-zygomatic subtemporal approach

Although an anterior approach can provide excellent access to the posterior fossa through the enlarged Meckel cave, the reverse is not the case, and hence, a posterior fossa approach provides a limited access to the portion of tumor located in the middle fossa.<sup>[13-15]</sup>

Samii *et al.*<sup>[11]</sup> described the retrosigmoid intradural suprameatal approach (RISA) for dealing with dumbbell schwannomas (DS); this approach provides exposure and mobilization of the TN and visualization of the structures medial to the internal auditory canal, the petrous apex, Meckel's cave, and the posterior end of the cavernous sinus. Hence, it is suitable for lesions predominantly in the posterior fossa with extension into the middle fossa in the anterolateral direction as shown in the cadaveric specimen by Chanda and Nanda.<sup>[12]</sup> Goel *et al.* described their experience of 73 cases of TS at various locations. Among them 30 patients had DS, which were removed using lateral basal sub-temporal approach in a single sitting.<sup>[16]</sup>

Verstappen *et al.* have achieved complete removal of these tumors in children using the pterional approach in single stage. The tumor in this paper was extending till the caudal cranial nerves.<sup>[1]</sup> Al-Mefty *et al.* have also in fact removed small dumbbell-shaped extensions into the posterior fossa through the expanded Meckel's cave (or porus trigeminus) without sectioning the tentorium or drilling the petrous apex in middle fossa approach.<sup>[15]</sup> Complete removal is possible in lesions not infiltrating the cavernous sinus, the seventh–eighth nerves or the brainstem; hence, an attempt should be made to avoid recurrences in all such cases.

In this child, complete excision was possible using the FTOZ craniotomy fashioned in a single piece and

subtemporal intradural approach. The FTOZ craniotomy is a versatile procedure which helps in accessing the part of the tumor extending superiorly with minimal retraction of the temporal lobes aided by zygomatic osteotomy to obtain a more inferior view of angle. With this craniotomy, the tumor can be approached either via transsylvian or the subtemporal/combination of both the approaches based on the location of the vein of labbe, which is often vulnerable for injury while retracting the temporal lobe. The tumor had expanded the Meckel's cave spreading in the interdural space along the course of the TN eroding the petrous resection bone. Hence, there was no necessity for drilling of the petrous or sectioning the tentorium cerebelli.

## Conclusion

Dumbbell-shaped TSs are rare in childhood. Based on the extent of the tumor, the surgical strategy should be selected for complete and safe excision. FTOZ craniotomy gives better access to the lesion, reduces the need for temporal lobe retraction, and offers superior cosmesis when performed as a “single piece craniotomy.”

## Financial support and sponsorship

Nil.

## Conflicts of interest

There are no conflicts of interest.

## References

1. Verstappen CC, Beems T, Erasmus CE, van Lindert EJ. Dumbbell trigeminal schwannoma in a child: Complete removal by a one-stage pterional surgical approach. *Childs Nerv Syst* 2005;21:1008-11.

2. Wanibuchi M, Fukushima T, Zomordi AR, Nonaka Y, Friedman AH. Trigeminal schwannomas: Skull base approaches and operative results in 105 patients. *Neurosurgery* 2012;70:132-43.
3. Zhang L, Yang Y, Xu S, Wang J, Liu Y, Zhu S. Trigeminal schwannomas: A report of 42 cases and review of the relevant surgical approaches. *Clin Neurol Neurosurg* 2009;111:261-9.
4. Fukaya R, Yoshida K, Ohira T, Kawase T. Trigeminal schwannomas: Experience with 57 cases and a review of the literature. *Neurosurg Rev* 2010;34:159-71.
5. Chen LF, Yang Y, Yu XG, Gui QP, Bu B, Xu BN, *et al.* Operative management of trigeminal neuromas: An analysis of a surgical experience with 55 cases. *Acta Neurochir (Wien)* 2014;156:1105-14.
6. Tsuboi K, Fujimori H, Tomono Y, Hamano K, Nose T. Dumbbell-shaped trigeminal neurinoma in a child. *Acta Neurochir (Wien)* 1999;141:429-32.
7. Pérez-Díaz CJ, Villarejo FJ, Pascual AM. Trigeminal neurinomas in infants: Report of two cases. *Childs Nerv Syst* 1996;12:283-6.
8. de Benedittis G, Bernasconi V, Ettorre G. Tumours of the fifth cranial nerve. *Acta Neurochir (Wien)* 1977;38:37-64.
9. Jefferson G. The trigeminal neurinomas with some remarks on malignant invasion of the gasserian ganglion. *Clin Neurosurg* 1953;1:11-54.
10. Yoshida K, Kawase T. Trigeminal neurinomas extending into multiple fossae: Surgical methods and review of the literature. *J Neurosurg* 1999;91:202-11.
11. Samii M, Alimohamadi M, Gerganov V. Endoscope-assisted retrosigmoid intradural suprameatal approach for surgical treatment of trigeminal schwannomas. *Neurosurgery* 2014;10 Suppl 4:565-75.
12. Chanda A, Nanda A. Retrosigmoid intradural suprameatal approach: Advantages and disadvantages from an anatomical perspective. *Neurosurgery* 2006;59 1 Suppl 1:ONS1-6.
13. Chung JC, Chung SY, Kim SM, Park MS. Surgery for a case of three-compartment trigeminal schwannoma: Technical aspects. *J Korean Neurosurg Soc* 2010;48:383-7.
14. Taha JM, Tew JM Jr., van Loveren HR, Keller JT, el-Kalliny M. Comparison of conventional and skull base surgical approaches for the excision of trigeminal neurinomas. *J Neurosurg* 1995;82:719-25.
15. Al-Mefty O, Ayoubi S, Gaber E. Trigeminal schwannomas: Removal of dumbbell-shaped tumors through the expanded Meckel cave and outcomes of cranial nerve function. *J Neurosurg* 2002;96:453-63.
16. Goel A, Muzumdar D, Raman C. Trigeminal neuroma: Analysis of surgical experience with 73 cases. *Neurosurgery* 2003;52:783-90.