

CASE REPORT

Cerebellospinal hemangioblastoma with bilateral pheochromocytoma and hepatic cyst: A rare entity

Mrinal Bhuyan, Deep Dutta, Basanta Kumar Baishya, Zakir Hussain

Department of Neurosurgery, Gauhati Medical College, Guwahati, Assam, India

ABSTRACT

A 45-year-old gentleman presented with headache, dizziness, and unsteadiness of gait. On imaging, he was found to have a cerebellar and a spinal intramedullary hemangioblastoma. To rule out Von Hippel–Lindau (VHL) disease, we did screening of the whole abdomen with ultrasonography followed by contrast-enhanced computed tomography of the abdomen, and surprisingly, the patient was having bilateral adrenal pheochromocytoma and a hepatic cyst. A diagnosis of VHL disease was made on this basis. The patient was operated and he made a very good recovery. We are reporting this interesting case because of its typical findings and its rarity. Disease management and review of literature were also discussed at the end.

Key words: Cerebellospinal, hemangioblastoma, Von Hippel–Lindau disease

Introduction

Von Hippel–Lindau (VHL) syndrome is a rare autosomal dominant condition characterized clinically by the development of vascular tumors, both benign and malignant. It is caused by germline mutations in the VHL gene located in the chromosome 3p25. The most common presentation is cerebellar hemangioblastoma. Typical tumors in VHL disease are hemangioblastomas of the retina, cerebellum, and medulla, renal cell carcinomas (RCC), and pheochromocytomas. Other VHL tumors are cysts with adenomas in the kidneys, pancreatic islets, epididymis, ligamentum latum, fallopian tubes and ovaries, and endolymphatic sac tumors. A wide range of disease and age manifestations exist between families and within families.

Case Report

A 45-year-old gentleman presented with 4-month history of headache, dizziness, and unsteadiness of gait. Headache was suboccipital and gradually progressive in nature with associated vomiting suggestive of raised intracranial pressure.

He had a tendency to fall toward the right side while walking and a feeling of clumsiness and tremor over his right hand, more while holding objects suggestive of the right side cerebellar involvement. There was a feeling of pain and paresthesia over his right forearm and hand. His bladder and bowel habits were normal.

On examination, his pulse and blood pressure were normal. The patient was conscious and well-oriented to time, place, and person. His vision was 6/6 bilateral. His fundus was found to be normal bilaterally. There was no nystagmus. Muscle power was found to be 5/5 in all groups of muscle in both upper and lower limbs. Cerebellar sign (Finger–Nose Test) was positive over the right side. On sensory examination, all modalities of sensations were found to be intact.

Family history

The patient has three brothers and one sister. His eldest sister and elder brother suffered a sudden death 2 years back due to some unknown cause. According to the patient, his father died of brain tumor when he was 5-year-old, although they could not produce any relevant documents. He is married and has a 10-year-old daughter who is enjoying good health.

Access this article online

Quick Response Code:



Website:

www.asianjns.org

DOI:

10.4103/1793-5482.179644

Address for correspondence:

Dr. Deep Dutta, Department of Neurosurgery,
 Gauhati Medical College, Guwahati, Assam, India.
 E-mail: duttadeep2844@yahoo.co.in

This is an open access article distributed under the terms of the Creative Commons Attribution-NonCommercial-ShareAlike 3.0 License, which allows others to remix, tweak, and build upon the work non-commercially, as long as the author is credited and the new creations are licensed under the identical terms.

For reprints contact: reprints@medknow.com

How to cite this article: Bhuyan M, Dutta D, Baishya BK, Hussain Z. Cerebellospinal hemangioblastoma with bilateral pheochromocytoma and hepatic cyst: A rare entity. *Asian J Neurosurg* 2016;11:311.

Investigations

Routine blood examination and complete blood count revealed neither polycythemia nor diabetes mellitus. Vanillylmandelic acid in the urine was found to be 7.2 mg/24 h (biological reference interval is 0.00–13.60 mg/24 h). Adrenaline in urine was 26.8 µg/24 h (Reference is <20 µg/24 h) and nor-adrenaline was 233.1 µg/24 h (Reference is <90 µg/24 h). Magnetic resonance imaging (MRI) of brain revealed a large and well-defined cystic intraaxial mass lesion predominantly in the cerebellar vermis extending to the right cerebellar hemisphere along with vascular voids, suggesting cerebellar hemangioblastoma [Figure 1a-c]. Further, MRI of the spine revealed an intramedullary mass lesion, involving the cervicodorsal cord, extending from C6 to T2 vertebral body level, causing cord expansion. The lesion showed

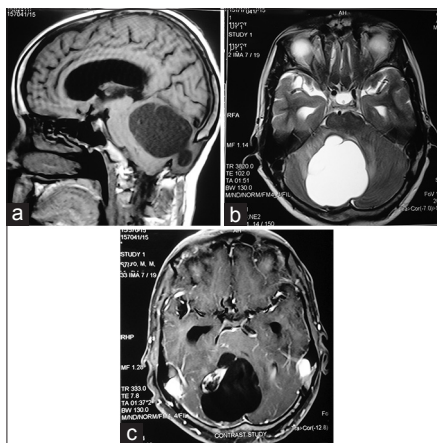


Figure 1: (a) T1-weighted sagittal image (b) T2-weighted axial image (c) contrast axial image of brain magnetic resonance imaging revealing a large and well-defined cystic intraaxial mass lesion predominantly in the cerebellar vermis extending to the right cerebellar hemisphere along with vascular voids, suggesting cerebellar hemangioblastoma

peripheral enhancement with a nodular enhancing component showing the presence of intralesional cystic areas, suggestive of hemangioblastoma [Figure 2a-d]. We did an ultrasonography and contrast-enhanced computed tomography of the whole abdomen for screening of VHL disease that revealed bilateral pheochromocytoma and even a hepatic hemangioma in segment VII [Figure 3a-d].

Differential diagnosis

Hemangioblastoma, pilocytic astrocytoma of posterior fossa, spinal cord intramedullary ependymoma, glioma, and schwannoma were considered as the differential diagnosis.

Treatment

The patient underwent a midline suboccipital craniotomy. We encountered a cystic lesion which was carefully punctured under microscope and the cyst contents were sucked out. Meticulous microscopical dissection identified the mural nodule that was found to be reddish and vascular. The nodule was carefully dissected out from the surrounding structures and removed in piecemeal fashion [Figure 4a and b]. The capsule

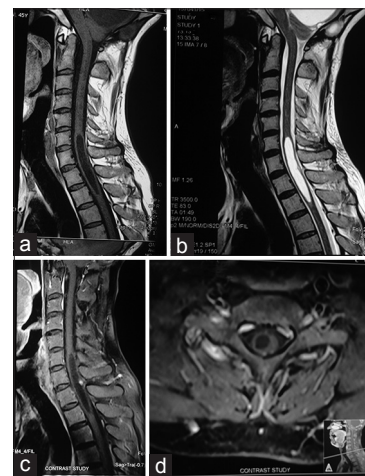


Figure 2: (a) T1-weighted sagittal image (b) T2-weighted sagittal image (c) contrast sagittal image (d) contrast axial image of magnetic resonance imaging of spine revealed an intramedullary mass lesion, involving the cervico-dorsal cord, extending from C6 to T2 vertebral body level, causing cord expansion. The lesion showed peripheral enhancement with a nodular enhancing component showing the presence of intralesional cystic areas, suggestive of hemangioblastoma

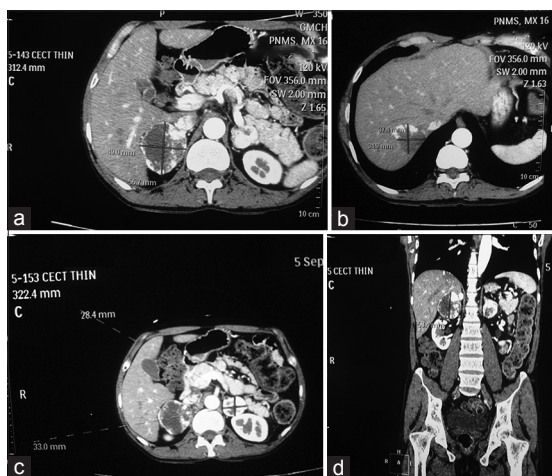


Figure 3: (a) Contrast-enhanced computed tomography of abdomen (b) contrast-enhanced computed tomography of abdomen showing a hepatic hemangioma (c) contrast-enhanced computed tomography of the whole abdomen revealed bilateral pheochromocytoma (d) contrast-enhanced computed tomography of the whole abdomen revealed bilateral pheochromocytoma and a hepatic hemangioma in segment VII

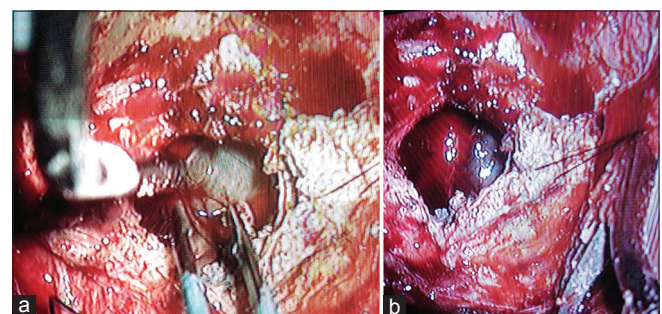


Figure 4: (a) Operative photograph showing the cystic cavity (b) the mural nodule under the microscope

was excised as far as possible without injuring normal brain parenchyma. Total homeostasis was obtained. Then, the wound was closed in layers. Postoperative period was satisfactory. He was kept in Intensive Care Unit for 1 day. Postoperative MRI showed complete removal of the tumor [Figure 5a].

Outcome

The tumor tissue tested for histopathology confirmed hemangioblastoma [Figure 5b]. The patient showed good recovery and with no intraoperative or postoperative complications. His neurological status was back to normal. We have done a thorough counseling with the patient as well as his family members, and currently, they are in regular follow-up with periodic radiologic evaluations. For his spinal intramedullary hemangioblastoma as he is asymptomatic till writing this manuscript, we decided craniospinal irradiation and regular close follow-up.

Discussion

The diagnosis of VHL may be made on clinical grounds. In a patient with a positive family history of VHL, finding of a single retinal or cerebellar hemangioblastoma, pheochromocytoma, or RCC is sufficient to make the diagnosis.^[1] Renal or epididymal cysts alone are not sufficient enough for diagnosis because of their frequent occurrence in general population. Up to 30% of the patients with cerebellar hemangioblastoma seem to have VHL syndrome. However, spinal hemangioblastomas are more indicative of VHL syndrome, about 80% coexistent.

For brain hemangioblastomas, within the brain, the vast majority are infratentorial, mainly in the cerebellar hemispheres. The pituitary stalk is the most common site for the development of supratentorial hemangioblastomas in individuals with VHL syndrome.^[2] Clinical symptoms depend on the site of the tumor: With infratentorial tumors, headache, vomiting, and gait disturbances or ataxia predominate; with tumors above the tentorium, symptoms depend on the location of the lesion.

Spinal hemangioblastomas are generally intradural, most commonly occur in the cervical or thoracic regions,

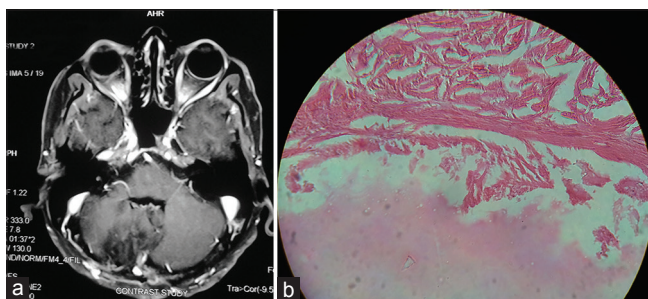


Figure 5: (a) Postoperative picture showing complete excision of the mass (b) histopathological picture showing clusters of stromal cells separated by multiple vascular channels consistent with hemangioblastoma

and occasionally may involve the entire cord. Most symptom-producing spinal hemangioblastomas are associated with cysts/syringomyelia/syrinx.^[3]

Families without a history of pheochromocytomas are labeled type 1 and families with a history of pheochromocytomas which constitute 7–20% of total incidence are designated as type 2.^[2] It seems that the case we encountered here is of type 2.

VHL type 1: Retinal angioma, central nervous system (CNS) hemangioblastoma, RCC, pancreatic cysts, and neuroendocrine tumors.

VHL type 2 is further subdivided as follows:

- Type 2A: Pheochromocytoma, retinal angiomas, and CNS hemangioblastoma; low-risk for RCC
- Type 2B: Pheochromocytoma, retinal angiomas, CNS hemangioblastomas, pancreatic cysts, and neuroendocrine tumor with a high risk for renal carcinoma
- Type 2C: Risk for pheochromocytoma only.

CNS hemangioblastoma is the prototypic lesion of VHL syndrome.^[4,5]

Genetics

The responsible tumor suppressor gene for VHL disease was recently identified from chromosome 3p25, and inactivating germline mutations of this gene, VHL, were found in the majority of VHL disease patients.^[5,6] Therefore, a genetic analysis and a chromosomal study are required in such patients not only to establish a diagnosis but also for counseling. The disease is inherited in an autosomal dominant pattern, and hence, all family members require screening.^[7] We intended to carry out a thorough genetic workup in our patient. However, they had declined.

Operative approach

Most CNS hemangioblastomas can be surgically removed completely and safely.^[2]

Cerebellar hemangioblastomas as for describing the optimal approach, authors have recommended suboccipital ipsilateral approach, modified far lateral approach, suboccipital midline approach, and suboccipital supracerebellar approach. Under microscope, the tumors can be identified as superficial racemose hemangiomas appearing bright or dark red. All authors followed the principle that the feeding arteries should be divided prior to the division of draining veins, which should be ligated last. We followed the same principle.

Follow-up

Although documented growth on serial MRIs and the need for pathological diagnosis have been suggested as indications for in otherwise asymptomatic patients, Harati *et al.*^[8] in their series showed a potentially larger group of asymptomatic patients with spinal hemangioblastoma associated with VHL

disease which would benefit from microsurgical resection and also have favorable prognosis. Their result suggested staging and early treatment for spinal hemangioblastomas larger than 55 mm, especially in patients with VHL disease. Small spinal hemangioblastomas may be followed up, if asymptomatic. Our case was asymptomatic, so we decided to follow-up. Closely monitored long-term follow-up is mandatory for monitoring the recurrence of primary tumors, once cerebellar hemangioblastoma with VHL has been diagnosed and treated.^[9] The frequency and length of the follow-up period should be considered when cystic lesions of abdominal organs are known to exist given that this seemingly benign condition can progress into malignancy.^[9]

Conclusion

With proper follow-up and screening of the family members of a patient with VHL disease, we can decrease the morbidity and mortality associated with this disease. Patient counseling is of paramount importance as the disease is inherited in an autosomal dominant pattern and this would aid us screen the family members as well, necessitating further interventions wherever deemed necessary to ensure patient well-being.

Financial support and sponsorship

Nil.

Conflicts of interest

There are no conflicts of interest.

References

1. Friedrich CA. Von Hippel-Lindau syndrome. A pleomorphic condition. *Cancer* 1999;86 11 Suppl: 2478-82.
2. Lonser RR, Glenn GM, Walther M, Chew EY, Libutti SK, Linehan WM, *et al.* von Hippel-Lindau disease. *Lancet* 2003;361:2059-67.
3. Wanebo JE, Lonser RR, Glenn GM, Oldfield EH. The natural history of hemangioblastomas of the central nervous system in patients with von Hippel-Lindau disease. *J Neurosurg* 2003;98:82-94.
4. Tootee A, Hasani-Ranjbar S. Von Hippel-Lindau disease: A new approach to an old problem. *Int J Endocrinol Metab* 2012;10:619-24.
5. Catapano D, Muscarella LA, Guarnieri V, Zelante L, D'Angelo VA, D'Agruma L. Hemangioblastomas of central nervous system: Molecular genetic analysis and clinical management. *Neurosurgery* 2005;56:1215-21.
6. Frantzen C, Kruizinga RC, van Asselt SJ, Zonnenberg BA, Lenders JW, de Herder WW, *et al.* Pregnancy-related hemangioblastoma progression and complications in von Hippel-Lindau disease. *Neurology* 2012;79:793-6.
7. Rahman A, Hoque SU, Bhandari PB, Alam S. Contiguous haemangioblastomas of the brain and spine in a patient of Von Hippel-Lindau disease. *BMJ Case Rep* 2013;2013. pii: Bcr2012007989.
8. Harati A, Satopää J, Mahler L, Billon-Grand R, Elsharkawy A, Niemelä M, *et al.* Early microsurgical treatment for spinal hemangioblastomas improves outcome in patients with von Hippel-Lindau disease. *Surg Neurol Int* 2012;3:6.
9. Lee SH, Park BJ, Kim TS, Lim YJ. Long-term follow-up clinical courses of cerebellar hemangioblastoma in von Hippel-Lindau disease: Two case reports and a literature review. *J Korean Neurosurg Soc* 2010;48:263-7.