

A novel equine-derived pericardium membrane for dural repair: A preliminary, short-term investigation

Roberto Centonze, Emiliano Agostini, Samantha Massaccesi, Stefano Toninelli, Letterio Morabito

Division of Neurosurgery, Ospedali Riuniti Marche Nord Hospital, Pesaro, Italy

ABSTRACT

Background: A large variety of biological and artificial materials are employed in dural repair, each of them with major limitations. Autologous grafts have limited availability and require an additional incision and surgical time. Cadaveric preparations and heterologous materials entail the risk of iatrogenic transmission of prions, whereas synthetic substitutes have been reported to cause inflammatory reactions and graft rejection. An equine-derived pericardium membrane has been developed (Heart[®], Bioteck, Vicenza, Italy) with mechanical and safety-related features that could make it suitable for neurosurgical application.

Aims: This preliminary study aimed to evaluate the short-term safety and efficacy of the Heart[®] membrane in dural repair procedures following meningioma surgeries.

Subjects and Methods: Medical records of patients who were surgically treated for an intracranial meningioma and underwent duraplasty with the Heart[®] membrane were reviewed retrospectively. The occurrence of any graft-related complications such as cerebrospinal fluid (CSF) leakage, postoperative hematoma, wound infection, meningitis, and neurological symptoms was analyzed.

Results: Eight patients were identified as meeting the inclusion criteria. A watertight closure was achieved in all of them. Postoperatively, no patients exhibited CSF leak, cerebral contusion, hemorrhage, or wound infection. The 1-month radiological follow-up revealed no evidence of pseudomeningocele, wound breakdown, or meningitis. Neurologic complications were observed in three patients but not directly imputable to the dural substitute or its application.

Conclusions: In all the patients, the pericardium membrane enabled achievement of a watertight dural closure without graft-related adverse events. Further investigations should be performed to assess medium- and long-term clinical outcomes in a larger set of patients.

Key words: Dural substitute, duraplasty, equine pericardium, xenograft

Introduction

A dural substitute should ideally have mechanical and biological properties that make it biocompatible, prevent cerebrospinal fluid (CSF) leakage, and foster neodura formation. Moreover, it ought to be easy to handle, readily available, and cost-effective.^[1] Despite many materials developed over the years, the search for an ideal dural substitute continues.^[2,3]

Heart[®] (Bioteck, Vicenza, Italy) is a collagen-based membrane derived from equine pericardium that could potentially guarantee higher levels of safety compared to other xenogeneic materials. Therefore, the present study was undertaken to review the short-term safety and efficacy outcomes obtained using Heart[®] membrane as a dural substitute.

Subjects and Methods

Medical records of patients who presented at the Division of Neurosurgery of the Ospedali Riuniti Marche Nord Hospital

This is an open access article distributed under the terms of the Creative Commons Attribution-NonCommercial-ShareAlike 3.0 License, which allows others to remix, tweak, and build upon the work non-commercially, as long as the author is credited and the new creations are licensed under the identical terms.

For reprints contact: reprints@medknow.com

| Access this article online | |
|---|----------------------------------|
| Quick Response Code: | Website: www.asianjns.org |
|  | DOI: 10.4103/1793-5482.179645 |

Address for correspondence:

Dr. Roberto Centonze, Ospedali Riuniti Marche Nord Hospital, Piazzale Cinelli 1, 61121 Pesaro PU, Italy.
E-mail: robcento72@gmail.com

How to cite this article: Centonze R, Agostini E, Massaccesi S, Toninelli S, Morabito L. A novel equine-derived pericardium membrane for dural repair: A preliminary, short-term investigation. Asian J Neurosurg 2016;11:201-5.

seeking surgical removal of intracranial meningiomas between May 2013 and November 2014 were collected and reviewed retrospectively. Inclusion criteria were: (a) a radiographic diagnosis of cerebral meningioma, (b) a tumor size at diagnosis ranging between 2 and 5 cm, (c) a surgical plan calling for a complete tumor resection followed by duraplasty, (d) the use of a Heart® membrane as a patch for dural repair, and (e) the availability of a radiological scan taken 1 month after surgery.

In examining the patient records, any occurrence of CSF leakage, postoperative hematoma, wound infection, meningitis, hydrocephalus, and new-onset neurological deficits was noted.

Results

The study group comprised 8 patients affected by intracranial meningioma, including 5 men and 3 women. They ranged in age from 56 to 81 years with an average age of 71 years. Two had undergone previous surgeries and experienced a recurrence, whereas 6 were surgically treated for the first time. The study group included 1 patient with a history of colorectal adenocarcinoma treated by surgical resection.

The operated tumors were six convexity meningiomas (3 in the parietal, 2 in the frontal, 1 in both the frontal and in the temporal cerebral regions) and 2 skull base meningiomas (1 foramen magnum and 1 sphenopetroclival meningioma). Total tumor resection was achieved in all the cases.

All the surgeries were carried out by the same experienced surgeon (LM). The surgical procedure was performed with the patient under general anesthesia and in the supine or half-seated position. Depending on the tumor location, different approaches were used to expose the tumors. The craniotomies included 2 frontotemporal, 2 parietal, 1 frontal, 1 frontoparietal, 1 suboccipital, and 1 fronto-orbito-temporal procedure. The tumor surface was incised with microscissors, as necessary; internal debulking proceeded with an ultrasonic aspirator (Sonopet Ultrasonic Aspirator, Stryker Corporation, MI, USA) or using bipolar cautery and suction. Tumor bioptic specimens were submitted for histopathological analysis.

In one patient, a hyperostosis of the frontal bone was found during surgery, and one case showed localized meningioma infiltration into the overlying bone and muscle tissues. In these patients, a complete removal of the hyperostosis and the infiltrated tissues was performed, and biopsies of these materials were collected for pathological evaluation.

For dural reconstruction of all patients, the equine-derived Heart® membrane (HRT-020 HEART Pericardium Membrane, Bioteck, Vicenza, Italy) was used as a dural patch. Heart® is a Type 1 collagen-based membrane obtained from equine pericardium taken from slaughtered animals. The

manufacturing process is performed by means of physical and enzymatic treatments aiming to remove potentially immunological elements while preserving the collagen network. After a freeze-drying lyophilization phase, sterilization with beta irradiation eliminates pathogens without affecting collagen native conformation. The membranes used in the present work were 50 mm × 50 mm × 0.2–0.4 mm in size. Before being used, they were rehydrated in sterile physiological solution for 3–5 min according to the manufacturer's instructions and trimmed to the size and shape of the defect [Figure 1]. The graft was fixed to the native dura mater using surgical sutures performed in a watertight fashion [Figure 1]. In two patients, DuraSeal (Confluent Surgical, Inc., Waltham, MA, USA) or fibrin glue (Tissucol, Baxter AG, Volketswil, Switzerland) were additionally applied at the interface between the graft and the remaining dura mater. To facilitate hemostasis, absorbable hemostatic agents (Surgicel, Ethicon, Somerville, NJ, USA) were used when needed.

After closing the dura, in six cases the patient's own bone flap was reimplanted and fixed with screws and plates or by titanium clamps (Craniofix, Aesculap AG, Tuttlingen, Germany). The two patients exhibiting hyperostotic or infiltrated tissues underwent cranioplasty with acrylic resin. After hemostasis, the wound was sutured in layers with a suction drain *in situ*.

All patients were adequately instructed about the surgery and gave their written informed consent. All underwent clinical and radiological evaluation on the 1st and 30th postoperative days. The visits included radiological examinations with computed tomography or magnetic resonance.

In all the surgeries, the Heart® membrane was found to have good handling properties and be easily suturable to the dura using standard suture material. Postoperatively, no patient developed a CSF leak, cerebral contusion, or hemorrhage. Moreover, no meningitis or wound breakdown was observed.

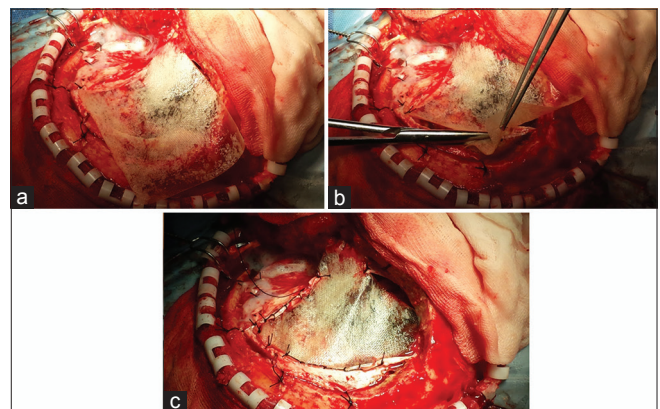


Figure 1: Application of the Heart® membrane as a dural substitute. After positioning over the defect (a), the membrane is cut back to appropriate dimensions (b) and sutured to the patient's dura mater (c)

During the follow-up period, three patients experienced new-onset neurological deficits or worsening of preexisting neurological symptoms and were hospitalized until complete remission occurred. One of the three displayed a mild motor and expressive aphasia. Left hemiparesis and probably fourth, fifth, and sixth right cranial nerve deficits were observed in the second case. Dysphagia and progression of preexisting tetraparesis developed in the third patient. None of these clinical and neurological complications could be directly attributed to the graft material or its application.

At the 1-month follow-up visit, neither local nor systemic signs of infection were observed. Based on radiological examinations, none of the patients showed signs of graft intolerance, inflammatory reactions, or pseudomeningocele formation.

Discussion

Surgery is the primary treatment for meningiomas and often requires the use of replacement materials for covering sizeable dural defects.^[4] Given the advantage of having no immunoreactivity and immunogenicity, autologous tissues are considered the most effective and safest choice as a substitute for dura mater. Nevertheless, such tissue is not always available in the desired quantity and shape and may require an additional incision or a second surgical site for harvest, thus requiring additional surgical time and increasing the risk of graft site morbidity.^[3]

To overcome such constraints, allografts have been widely used for several decades. Cadaveric dural implants are easy to handle and widely available but have been associated with the transmission of viral infections and prion diseases, such as the Creutzfeldt-Jakob disease (CJD).^[5] CJD can be sporadic, hereditary, or acquired.^[6] Acquired CJD is often an iatrogenic disease, spread to other people through medical procedures such as grafts of dura mater, transplanted corneas, implantation of inadequately sterilized electrodes in the brain, and injections of contaminated pituitary growth hormone derived from cadavers.^[7] CJD associated with dura mater grafts has been reported in 20 countries.^[8,9] Since the first description in 1987, almost 228 additional cases of dura-related CJD have been recognized worldwide,^[5,8,10] most of them related to the use of a single allogenic dural graft (Lyodura, B. Braun Melsungen AG, Melsungen, Germany).^[11,12] Since the 1990s, new techniques for sterilizing, tracing, and processing tissues have been developed, resulting in a drastic reduction of the reported cases of new infections.^[8,13] However, given the very long silent incubation period of this degenerative disorder (an average of 12 years but as long as 30 years), this epidemic may have not ended yet.^[5] Overall, according to Heath *et al.*, the estimated risk of human dura mater-associated CJD was estimated to be 1 per 500–2000, depending on the study

population and the year when the graft was performed.^[14] However, an accurate estimate of the use of human dural grafts is not available in many countries,^[9,15] so the data should not be considered exhaustive.

Concerns about possible CJD transmission from cadaveric preparations prompted the search for safer synthetic dural substitutes. Because of their unlimited availability, their controlled manufacturing and sterilization procedures, and standardized features, synthetic products theoretically bear a close resemblance to an ideal graft.^[16] Nonetheless, most have been associated with severe adverse events including failure of graft incorporation, CSF bleeding, chronic inflammatory reactions, meningitis, or excessive scar formation for which a reoperation is often required.^[17-22] This wide range of complications may also occur belatedly, up to 32 years after implantation.^[23-25]

As alternatives to autologous and allogenic transplantations, various xenografts have been studied. Pericardium, peritoneum, dermis, and fascia lata from bovine, porcine, ovine, or equine donors are the most common sources.^[3,26-30] The abundance of supply, mechanical properties similar to those of native dura mater, and relatively low cost compared with allogeneic dural grafts have made their use widespread in many countries.^[3] Xenogeneic sources, however, involve an additional set of considerations associated with potential immunologic issues as well as zoonoses. In particular, the possible risk of transmission of zoonotic prion disease from cattle, pigs, and sheep is concerning and has discouraged the use of such materials.^[31] Indeed, prion proteins (PrP^c) are highly resistant to denaturation by chemical and physical agents and therefore cannot be effectively neutralized by common processing and sterilizing stages.^[32-34]

This poses a serious issue in neurosurgical use of xenografts, given that graft materials are often directly in touch with the brain, and prion diseases target the central nervous system.^[35] These neurological disorders arise as a result of the misfolding of the normal cellular PrP^c into its pathogenic and infectious form. However, unlike all the other animal sources for dural graft materials, horses express a PrP^c protein with a very stable structure, making this species resistant to prion infection.^[36] Indeed, no occurrence of prion diseases has been reported in horses.^[37-39] This means the zoonotic risk to humans of contracting prion diseases from equine-derived biomaterials is very low compared to other animal sources. Materials of equine origins may offer protection against iatrogenic prion disease transmission. To date, a set of equine collagen-based dural substitutes are available on the market (TissuDura[®], Baxter; Audiomesh Neuro[®], Audio Technologies; Lyomesh[®], Audio Technologies) and have been demonstrated to be suitable material for dural implantation.^[30,40,41] Although similar in their collagen composition, these materials each have physical and biological features that reflect their

different collagen sources (pericardium, peritoneum, Achilles tendons, or dermis of fetal skin) and processing methods. Such differences ultimately influence their intraoperative handling and biological performance.^[40,42-44]

Heart[®] membrane is a graft material obtained from equine pericardium that consists of interwoven collagen fibers. The manufacturing process operates at low temperatures, thus allowing the native collagen conformation to be preserved. It also replaces several steps normally performed by chemical methods (e.g., organic solvents) with enzymatic or physical treatments. Compared to other equine-derived biomaterials, the risk of residual chemicals within the membrane being released into the recipient tissue with possible cytotoxic effects should therefore be minimized.

Whereas the use of Heart[®] membrane in dental surgery has already been explored and documented,^[45,46] the present study provides the first preliminary outcomes collected in a neurosurgical application. In a study based upon 2115 cranial operations, Ernestus *et al.* retrospectively evaluated frequency and nature of complications following duraplasty in intracranial operations. Complications, including CSF fistula, inflammation, pneumatocephalus, and pseudocysts, were observed in 13.1% of cases.^[47] This percentage was as high as 41.1% in a more recent, retrospective work focusing on 2216 patients who underwent resection for meningioma.^[48]

In the present case series, the membrane proved resistant to suture stitches and impermeable to CSF, permitting closure of the dura in all the patients to be watertight. None of the main graft-related complications were observed either postoperatively or 1 month after surgery. In particular, no cases of CSF leakage, postoperative hematoma, wound infection, or meningitis were found. The reported incidence of these adverse events in convexity meningiomas, the most represented in our case series, is around 1.4% with regard to CSF leakage and hematoma, 3.9% for cases of infection and 0.6% for meningitis.^[49-51] Given the small sample size of the study, it is not possible to compare our results with the published ones, nor to predict if our observations would be confirmed on a greater number of patients.

Nonetheless, and within the limits of a retrospective and short-term study, we believe that our preliminary findings depict an encouraging picture and that the Heart[®] membrane could be a suitable alternative to current graft options for dural reconstruction. Prospective studies with larger sample sizes and longer follow-up periods are needed to assess the middle- and long-term clinical outcomes.

Conclusions

In this preliminary, short-term study the safety and efficacy profile of an equine-derived pericardium membrane for dural

repair was tested. The Heart[®] membrane enabled achievement of a watertight dural closure in all the patients without postoperative graft-related adverse events, such as CSF leak, cerebral contusion, hemorrhage, or wound infection. At the 1-month follow-up no evidence of pseudomeningocele, wound breakdown, or meningitis was noticed. The absence of local and systemic complications together with the animal source of the biomaterial and the peculiarities of its manufacturing process make the membrane suitable and worthwhile as dural substitute in neurosurgical procedures.

Financial support and sponsorship

Nil.

Conflicts of interest

There are no conflicts of interest.

References

- Berjano R, Vinas FC, Dujovny M. A review of dural substitutes used in neurosurgery. *Crit Rev Neurosurg* 1999;9:217-22.
- Caroli E, Rocchi G, Salvati M, Delfini R. Duraplasty: Our current experience. *Surg Neurol* 2004;61:55-9.
- Yu F, Wu F, Zhou R, Guo L, Zhang J, Tao D. Current developments in dural repair: A focused review on new methods and materials. *Front Biosci (Landmark Ed)* 2013;18:1335-43.
- Whittle IR, Smith C, Navoo P, Collie D. Meningiomas. *Lancet* 2004;363:1535-43.
- Brown P, Brandel JP, Sato T, Nakamura Y, MacKenzie J, Will RG, *et al.* Iatrogenic Creutzfeldt-Jakob disease, final assessment. *Emerg Infect Dis* 2012;18:901-7.
- Sikorska B, Liberski PP. Human prion diseases: From kuru to variant Creutzfeldt-Jakob disease. *Subcell Biochem* 2012;65:457-96.
- Will RG. Acquired prion disease: Iatrogenic CJD, variant CJD, kuru. *Br Med Bull* 2003;66:255-65.
- Brown P, Brandel JP, Preece M, Sato T. Iatrogenic Creutzfeldt-Jakob disease: The waning of an era. *Neurology* 2006;67:389-93.
- Kim HL, Do JY, Cho HJ, Jeon YC, Park SJ, Ma HI, *et al.* Dura mater graft-associated Creutzfeldt-Jakob disease: The first case in Korea. *J Korean Med Sci* 2011;26:1515-7.
- Thadani V, Penar PL, Partington J, Kalb R, Janssen R, Schonberger LB, *et al.* Creutzfeldt-Jakob disease probably acquired from a cadaveric dura mater graft. *Case report. J Neurosurg* 1988;69:766-9.
- Yamada M, Noguchi-Shinohara M, Hamaguchi T, Nozaki I, Kitamoto T, Sato T, *et al.* Dura mater graft-associated Creutzfeldt-Jakob disease in Japan: Clinicopathological and molecular characterization of the two distinct subtypes. *Neuropathology* 2009;29:609-18.
- Hannah EL, Belay ED, Gambetti P, Krause G, Parchi P, Capellari S, *et al.* Creutzfeldt-Jakob disease after receipt of a previously unimplicated brand of dura mater graft. *Neurology* 2001;56:1080-3.
- Marx RE, Carlson ER. Creutzfeldt-Jakob disease from allogeneic dura: A review of risks and safety. *J Oral Maxillofac Surg* 1991;49:272-4.
- Heath CA, Barker RA, Esmonde TF, Harvey P, Roberts R, Trend P, *et al.* Dura mater-associated Creutzfeldt-Jakob disease: Experience from surveillance in the UK. *J Neurol Neurosurg Psychiatry* 2006;77:880-2.
- Brooke FJ, Boyd A, Klug GM, Masters CL, Collins SJ. Lyodura use and the risk of iatrogenic Creutzfeldt-Jakob disease in Australia. *Med J Aust* 2004;180:177-81.
- Costa BS, Cavalcanti-Mendes Gde A, de Abreu MS, de Sousa AA. Clinical experience with a novel bovine collagen dura mater substitute. *Asian J Neurosurg* 2010;5:31-4.
- Cohen AR, Aleksic S, Ransohoff J. Inflammatory reaction to synthetic dural substitute. *Case report. J Neurosurg* 1989;70:633-5.
- Ng TH, Chan KH, Leung SY, Mann KS. An unusual complication of silastic dural substitute: Case report. *Neurosurgery* 1990;27:491-3.

19. Siccardi D, Ventimiglia A. Fibrotic-haemorrhagic reaction to synthetic dural substitute. *Acta Neurochir (Wien)* 1995;132:148-9.
20. Nakagawa S, Hayashi T, Anegawa S, Nakashima S, Shimokawa S, Furukawa Y. Postoperative infection after duraplasty with expanded polytetrafluoroethylene sheet. *Neurol Med Chir (Tokyo)* 2003;43:120-4.
21. Malliti M, Page P, Gury C, Chomette E, Nataf F, Roux FX. Comparison of deep wound infection rates using a synthetic dural substitute (neuro-patch) or pericranium graft for dural closure: A clinical review of 1 year. *Neurosurgery* 2004;54:599-603.
22. Yoshioka N. Cranial reconstruction following the removal of an infected synthetic dura mater substitute. *Plast Reconstr Surg Glob Open* 2014;2:e134.
23. Ohbayashi N, Inagawa T, Katoh Y, Kumano K, Nagasako R, Hada H. Complication of silastic dural substitute 20 years after dural plasty. *Surg Neurol* 1994;41:338-41.
24. Teo M, Martin S, Bowness J, Eljamel MS. Dural graft-induced fibrotic mass twelve years after successful treatment of skull base non-Hodgkin lymphoma mimicking recurrence: Case report and literature review. *Open J Mod Neurosurg* 2014;4:7-12.
25. Ström JO, Boström S, Bobinski L, Theodorsson A. Low-grade infection complicating silastic dural substitute 32 years post-operatively. *Brain Inj* 2011;25:250-4.
26. Parizek J, Husek Z, Mericka P, Téra J, Nemecek S, Spacek J, *et al.* Ovine pericardium: A new material for duraplasty. *J Neurosurg* 1996;84:508-13.
27. Parizek J, Mericka P, Husek Z, Suba P, Spacek J, Nemecek S, *et al.* Detailed evaluation of 2959 allogeneic and xenogeneic dense connective tissue grafts (fascia lata, pericardium, and dura mater) used in the course of 20 years for duraplasty in neurosurgery. *Acta Neurochir (Wien)* 1997;139:827-38.
28. Filippi R, Schwarz M, Voth D, Reisch R, Grunert P, Perneczky A. Bovine pericardium for duraplasty: Clinical results in 32 patients. *Neurosurg Rev* 2001;24:103-7.
29. Bejjani GK, Zabramski J; Durasis Study Group. Safety and efficacy of the porcine small intestinal submucosa dural substitute: Results of a prospective multicenter study and literature review. *J Neurosurg* 2007;106:1028-33.
30. Montinaro A, Gianfreda CD, Proto P. Equine pericardium for dural grafts: Clinical results in 200 patients. *J Neurosurg Sci* 2007;51:17-9.
31. Norrby E. Prions and protein-folding diseases. *J Intern Med* 2011;270:1-14.
32. Antloga K, Meszaros J, Malchesky PS, McDonnell GE. Prion disease and medical devices. *ASAIO J* 2000;46:S69-72.
33. Rutala WA, Weber DJ. Creutzfeldt-Jakob disease: Recommendations for disinfection and sterilization. *Clin Infect Dis* 2001;32:1348-56.
34. Papacchini M, Mansi A, Marta I. Prevention of transmissible spongiform encephalopathy and methods for prion inactivation. *Med Lav* 2003;94:271-84.
35. Blättler T. Implications of prion diseases for neurosurgery. *Neurosurg Rev* 2002;25:195-203.
36. Zhang J. The structural stability of wild-type horse prion protein. *J Biomol Struct Dyn* 2011;29:369-77.
37. Khan MQ, Sweeting B, Mulligan VK, Arslan PE, Cashman NR, Pai EF, *et al.* Prion disease susceptibility is affected by beta-structure folding propensity and local side-chain interactions in PrP. *Proc Natl Acad Sci U S A* 2010;107:19808-13.
38. Pérez DR, Damberger FF, Wüthrich K. Horse prion protein NMR structure and comparisons with related variants of the mouse prion protein. *J Mol Biol* 2010;400:121-8.
39. Giachin G, Biljan I, Ilc G, Plavec J, Legname G. Probing early misfolding events in prion protein mutants by NMR spectroscopy. *Molecules* 2013;18:9451-76.
40. Biroli F, Esposito F, Fusco M, Bani GG, Signorelli A, de Divitiis O, *et al.* Novel equine collagen-only dural substitute. *Neurosurgery* 2008;62 3 Suppl 1:273-4.
41. Cavallo LM, Solari D, Somma T, Di Somma A, Chiamonte C, Cappabianca P. Use of equine pericardium sheet (LYOMESH®) as dura mater substitute in endoscopic endonasal transphenoidal surgery. *Transl Med UniSa* 2013;7:23-8.
42. Zerris VA, James KS, Roberts JB, Bell E, Heilman CB. Repair of the dura mater with processed collagen devices. *J Biomed Mater Res B Appl Biomater* 2007;83:580-8.
43. Esposito F, Cappabianca P, Fusco M, Cavallo LM, Bani GG, Biroli F, *et al.* Collagen-only biomatrix as a novel dural substitute. Examination of the efficacy, safety and outcome: Clinical experience on a series of 208 patients. *Clin Neurol Neurosurg* 2008;110:343-51.
44. Esposito F, Grimod G, Cavallo LM, Lanterna L, Biroli F, Cappabianca P. Collagen-only biomatrix as dural substitute: What happened after a 5-year observational follow-up study. *Clin Neurol Neurosurg* 2013;115:1735-7.
45. Di Stefano DA, Andreasi Bassi M, Cinci L, Pieri L, Ammirabile G. Treatment of a bone defect consequent to the removal of a periapical cyst with equine bone and equine membranes: Clinical and histological outcome. *Minerva Stomatol* 2012;61:477-90.
46. Materni A. Managing a vestibular infra-bony periodontal defect in the aesthetic zone through bone regeneration: A case report. *Stomatolog* 2013;19:30-5.
47. Ernestus RI, Ketter G, Klug N. Dura-plasty in intracranial operations. *Zentralbl Neurochir* 1995;56:106-10.
48. Connolly ID, Cole T, Veeravagu A, Popat R, Ratliff J, Li G. Craniotomy for resection of meningioma: An age-stratified analysis of the MarketScan longitudinal database. *World Neurosurg* 2015;84:1864-70.
49. Morokoff AP, Zauberman J, Black PM. Surgery for convexity meningiomas. *Neurosurgery* 2008;63:427-33.
50. Sanai N, Sughrue ME, Shangari G, Chung K, Berger MS, McDermott MW. Risk profile associated with convexity meningioma resection in the modern neurosurgical era. *J Neurosurg* 2010;112:913-9.
51. Nanda A, Bir SC, Konar S, Maiti TK, Bollam P. World Health Organization grade I convexity meningiomas: Study on outcomes, complications and recurrence rates. *World Neurosurg* 2015. pii: S1878-875001651-4.