

# Contribution of the xenograft bone plate-screw system in lumbar transpedicular stabilization: An *in vivo* study in dogs

Sani Sarigul, Hakan Salci<sup>1</sup>, Huseyin Lekesiz<sup>2</sup>, Seref Dogan, Resat Ozcan<sup>2</sup>, Osman Sacit Gorgul<sup>1</sup>, Kaya Aksoy

Department of Neurosurgery, Faculty of Medicine, Uludag University, <sup>1</sup>Department of Surgery, Faculty of Veterinary Medicine, Uludag University, <sup>2</sup>Department of Machines, Faculty of Engineering and Architecture, Uludag University, Bursa, Turkey

## ABSTRACT

**Objectives:** Xenograft bone plate-screws (XBPSs) can be alternative tools in lumbar transpedicular stabilization (TS). The aim of this study was to show biomechanical and histopathological contribution of the XBPSs system in lumbar TS.

**Materials and Methods:** Fifteen ( $n = 15$ ) hybrid dog and ten ( $n = 10$ ) L<sub>2-4</sub> cadaveric specimens were included in the study. The dogs were separated according to surgical techniques: L<sub>3</sub> laminectomy and bilateral facetectomy (LBF) in Group I (experimental group [EG I]) ( $n = 5$ ), L<sub>3</sub> LBF plus TS with metal plate-screws (MPSs) in Group II (EG II) ( $n = 5$ ), and L<sub>3</sub> LBF plus TS with XBPSs in Group III (EG III) ( $n = 5$ ). The cadaveric specimens were separated to L<sub>2-4</sub> intact in Group I (CG I), ( $n = 5$ ), and L<sub>3</sub> LBF in Group II (CG II), ( $n = 5$ ). The dogs were sacrificed at the end of 3<sup>rd</sup> month, and their L<sub>2-4</sub> spinal segments were *en bloc* removed and prepared as in control groups. Flexion, extension, left-right bending, rotation, and compression tests were applied to all segments. Stiffness values were calculated and analyzed statistically. All dog segments were evaluated histopathologically.

**Results:** XBPS system showed a higher average stiffness values for left bending, extension, flexion, and compression compared to MPS, but these differences were not statistically meaningful. XBPS system had superiority to the fusion formation, as well.

**Conclusions:** XBPSs provide stability and help the fusion formation, but this system does not have a biomechanical advantage over MPS system in TS.

**Key words:** Biomechanic, histopathology, transpedicular stabilization, xenograft bone plate-screw

## Introduction

Xenograft bone plate-screw (XBPS) systems are clinically effective devices in spinal surgery.<sup>[1]</sup> They provide osteoinduction, osteogenesis, and fusion formation between the spinal segments, if compare to long time results of the metal instruments.<sup>[2,3]</sup> Application of these instruments needs

some requirements including nonantigenic, resterilizable, noncontaminated, and resistant to excessive loadings.<sup>[4,5]</sup>

Biomechanical stability between the spinal segments may not be estimated as *in vivo*.<sup>[2,6]</sup> In addition, clinical and radiological examinations have no competence to proclaim the stability between spinal segments. Therefore, *in vitro* or experimental biomechanical studies have to be performed in spinal surgery.<sup>[4,7-9]</sup> We previously reported the *in vitro* biomechanical contribution of XBPS system in lumbar transpedicular stabilization (TS) of the dogs.<sup>[10]</sup> Here, it was

This is an open access article distributed under the terms of the Creative Commons Attribution-NonCommercial-ShareAlike 3.0 License, which allows others to remix, tweak, and build upon the work non-commercially, as long as the author is credited and the new creations are licensed under the identical terms.

**For reprints contact:** reprints@medknow.com

Access this article online	
Quick Response Code:	Website: www.asianjns.org
	DOI: 10.4103/1793-5482.185061

### Address for correspondence:

Dr. Hakan Salci, Department of Surgery, Faculty of Veterinary Medicine, Uludag University, Gorukle Campus, 16059 Bursa, Turkey.  
E-mail: hsalci@uludag.edu.tr

**How to cite this article:** Sarigul S, Salci H, Lekesiz H, Dogan S, Ozcan R, Gorgul OS, *et al.* Contribution of the xenograft bone plate-screw system in lumbar transpedicular stabilization: An *in vivo* study in dogs. Asian J Neurosurg 2017;12:494-500.


aimed to demonstrate biomechanical and histopathological contribution of XBPS system in TS of the dogs.

## Materials and Methods

This study was designed after permission of the local ethical committee of Uludag University. Fifteen ( $n = 15$ ) healthy adult, hybrid, same size (about 20 kg weight) and ten ( $n = 10$ ) L<sub>2-4</sub> cadaveric lumbar dog specimens (nonpathologic) were studied in experimental and control groups (CGs), respectively. The dogs were separated into three groups: L<sub>3</sub> laminectomy and bilateral facetectomy (LBF) (experimental group I [EG I],  $n = 5$ ), LBF plus TS with metal plate-screw (MPS) (EG II,  $n = 5$ ), and LBF plus TS with XBPS (experimental group III,  $n = 5$ ). L<sub>2-4</sub> cadaveric lumbar dog specimens ( $n = 10$ ) were harvested, and their muscles were dissected, but discs and ligaments and the other tissues were kept intact from the dissection. Cadaveric specimens were separated into two groups L<sub>2-4</sub> intact (CG I,  $n = 5$ ) and LBF (CG II,  $n = 5$ ). Specimens in CG I and CG II were tested following the preparations.

The XBPSs were machined (Yunan Machine Tool Works, China) from cadaveric cattle tibia and sized as in the previous study.<sup>[10]</sup> Metal screws and plates had same size as in XBPS [Figure 1]. Sterilization of the all equipment was made in autoclave, but XBPSs were boiled in 3% acide borique solution at 15 min for sterilization as described previously.<sup>[4]</sup>

In EGs, general anesthesia was maintained with 2% isoflurane after xylazine HCl (1 mg/kg, intramuscular) and thiopental Na (15 mg/kg, intravenous [iv.] bolus) inductions. Cefazolin Na (20 mg/kg, iv.) and carprofen (5 mg/kg, subcutaneous) were administered as antibiotic and analgesic agents, respectively. The same surgical team carried out all operations. The dogs were placed in dorsal recumbency, and surgery was performed on the dorsal lumbar mid-line between L<sub>1</sub> and L<sub>5</sub>. After paravertebral muscles dissection and retraction, LBF was performed with the routine technique [Figure 2]. L<sub>2</sub> and L<sub>4</sub> facet



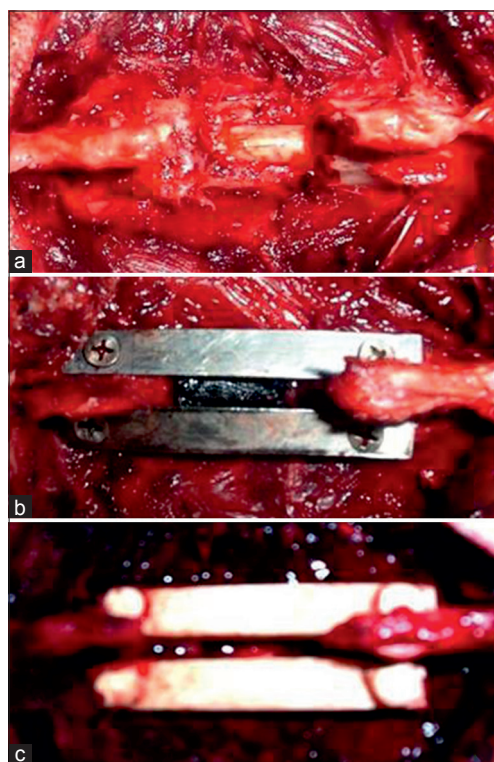
**Figure 1:** The metal (a) and xenograft bone (b) plate and screw instruments applied transpedicular to vertebral segments in the dogs

surfaces were flattened, and holes were dorsoventrally drilled on the facet surfaces through pedicles to corpus vertebrae. Plates were placed on this surface and screwed through the pedicle. Xenograft and metal screws were firmly tightened with screwdriver. L<sub>2-4</sub> lumbar segments were stabilized transpedicular with XBPSs or MPSs [Figure 2]. The surgical area was bandaged, and the dogs were restricted to prevent the abnormal lumbar movements.


Postoperative care was maintained for 3 months of period complying with the rules of the National Society of Medical Research Principles of Laboratory Animal Care. Postoperatively, the dogs were relieved with carprofen, and cefazolin Na was administered as an antibiotic agent. Methylprednisolone sodium succinate (4 mg/kg, iv.) administration was continued 3 days postoperatively. Hematologic parameters of the dogs were controlled routinely, and dogs were closely monitored. Operation site was checked with dorsoventral and lateral radiograms during 3 months [Figure 3].

At the end of 3<sup>rd</sup> month, the dogs were euthanized with high-dose thiopental Na. L<sub>2-4</sub> spinal segments of the dogs were *en bloc* removed and then tested biomechanically.

A universal testing machine (Hounsfield®, UK) was used for biomechanical tests as reported in the previous study.<sup>[10]</sup> Six



**Figure 2:** These per-operative views show the L<sub>3</sub> laminectomy and bilateral facetectomy in experimental group I (a), transpedicular stabilization with metal plate-screw (b) and xenograft bone plate-screw (c) of the L<sub>2-4</sub> lumbar segments in experimental group II and experimental group III, respectively



**Figure 3:** The comparative radiographs taken following surgery (a-c) and at the end of 3<sup>rd</sup> months (a'-c') show the osteophytic areas (right arrows) in experimental group II and resorption of the transpedicular applied xenograft bone screws (left arrows) in experimental group III

different types of loads were applied to specimens sequentially in the following order: Flexion, extension, left-right bending, rotation, and compression. To execute these motions, couple moments were applied on the specimens about different axes with the aim of a moment arm. This arm facilitated the translation of vertical movement of testing machine to couple moment. The variation in the motions was achieved by changing the orientation of the specimen for each different test. All loadings except compression were applied nondestructively. However, compression test was performed until the specimen fails. Therefore, compression test was carried out as the last test of the sequence.

Data were collected in the same manner as in the previous study.<sup>[10]</sup> The load was applied monotonically, and the magnitude of loading is recorded for each 1 mm displacements. The test was interrupted at 16 mm displacement. The recorded loading values were converted to the couple moment using the following relation:

$$M = F \times L \text{ (N mm)}$$

Where F was the applied loading by testing machine and L was the length of the moment arm. Displacement values could be converted to the rotation angle using the relation:

$$A = v/L \text{ (rad)}$$

v here was the displacement value in mm and  $\alpha$  was in radians.

Compression test did not require any of the conversion formulas mentioned above. Instead, loading values were recorded in 1 mm intervals up to the failure point of specimen.

To quantify the sustainability of specimens, stiffness of the specimens were calculated using following formula:

$$k_i = M/\alpha = F_i L^{2n}/180 v_i \text{ (Nmm/}^\circ\text{)}$$

Where  $k_i$  was the stiffness value, where  $F_i$  was the loading value ( $v_i = 1, 2, 3, 16$  mm). An average value of this stiffness needed to be determined to facilitate the comparison between groups, which could be defined as

$$K = 1/16 \sum k_i.$$

K here represented the resistance of the specimens to the flexion, extension, left-right bending, and rotation. In the range of the test, there was almost a linear relation between moment and angle. Therefore, slope of the linear curve fit of moment – angle plot yielded a very close stiffness value to the average value. Therefore, both average and slope of linear curve fit could be used interchangeably as the stiffness value.

Following the calculation of the average stiffness value of specimens for each motion type, an analysis was performed to check if test groups create a meaningful classification or not. For this purpose, Euclidean distances method was applied to the right bending data using statistical software (Statistica'99; StatSoft, USA). For simplicity in the analysis, specimens were numbered from C\_1 to C\_25. Each five specimens belongs to a test group such as CG I (C\_1, C\_2, C\_3, C\_4, C\_5), CG II (C\_6, C\_7, C\_8, C\_9, C\_10), EG I (C\_11, C\_12, C\_13, C\_14, C\_15), EG II (C\_16, C\_17, C\_18, C\_19, C\_20), and EG III (C\_21, C\_22, C\_23, C\_24, C\_25).

As mentioned above, compression test was evaluated in different units, and stiffness value was calculated as

$$k_i = F_i/v_i \text{ (N/mm)}.$$

This stiffness represented the resistance of specimen to the compressive load. Similar to the other groups an average stiffness value was calculated for each specimen. Different than other tests, this test was performed up to failure displacement. Therefore, for each sample, a different breakage displacement was observed, and number of data points had variety for each sample.

The differences between groups were evaluated statistically using  $k_i$  values and assessed if the differences were meaningful or not. For this purpose, one-tailed hypothesis test with 95% confidence interval was performed using Analyse-it Software, Microsoft®, USA, which works compatible with Microsoft Excel.

After biomechanical tests, L<sub>2-4</sub> spinal segments of the dogs were fixed in 10% neutral-buffered formalin solutions. Segments were kept in a solution containing 4% formic acid and 4% sulfuric acid for decalcification during 10 days. After decalcification, segments were cut axially and sagittally at 5  $\mu$ m in thickness, and then slides were stained with hematoxylin and eosin for microscopic examination.



**Results**

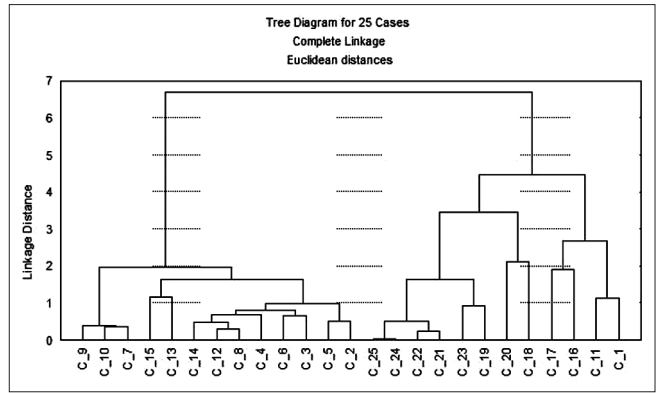
At the end of 3<sup>rd</sup> month, radiopacity on the facetectomy and laminectomy surface possibly related to fusion was determined in all experiment groups [Figure 3]. In addition, resorption of the xenograft bone screws was detected in the pedicle and vertebral corpus [Figure 3].

To check the grouping of the specimens, the Euclidean distances between specimens for right bending data are shown in Figure 4. This figure provided the possible grouping based on the differences between stiffness of samples. Considering the first five specimens, which belong to CG I; four samples (C\_2, C\_3, C\_4, and C\_5) were grouped under a common branch; however, C\_1 was isolated from group under a different cluster. For CG II, C\_6 and C\_8 shared a common branch and C\_7, C\_9, and C\_10 were located under a different branch. However, all five members were placed under a common cluster. For EG I, all samples were perfectly grouped under a branch except C\_11. Specimens belonging to EG II and EG III were perfectly grouped and shared a common branch. CG I and EG I created a meaningful group except one specimen. CG I, EG II, and EG III consist of perfectly grouped members, which shared a common cluster. This analysis provided the justification of grouping such that EGs were considered to be meaningful for further statistical investigations.

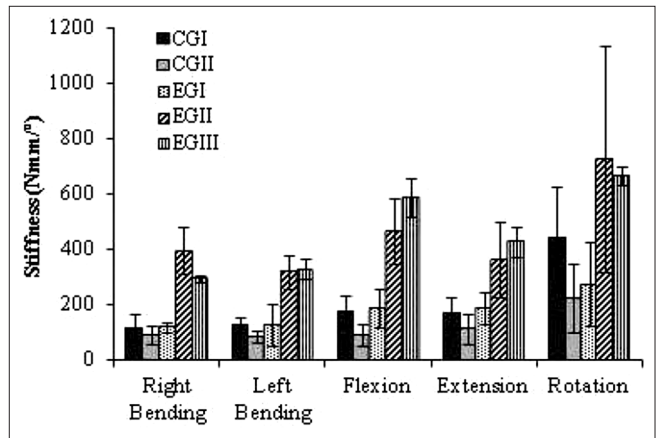
The average stiffness values of each specimen for each motion were calculated and shown in Figures 5 and 6. The error bars in this figure represented the standard deviation of the corresponding group.

As could be seen from the Figure 5, both MPS and XPBS have much higher stiffness values compared to CGs, and therefore, they contribute stability significantly. The stiffest motion was the rotation unexceptionally for all groups, and right-left bending was the most flexible motions among groups. Compared to MPS, XPBS had a higher stiffness for left bending, flexion, and extension and lower stiffness for rotation and right bending. These were the most noticeable observations concluded from the Figure 5. However, a more detailed analysis needed to be performed to comprehend more results from experimental data. Quantitative values were calculated based on average stiffness values. However, if the deviation from one group to another was not noticeably large, all the specimens needed to be taken into consideration in statistical analysis rather than using only average values. In the following part, comparison of groups would be given for each motion, individually.

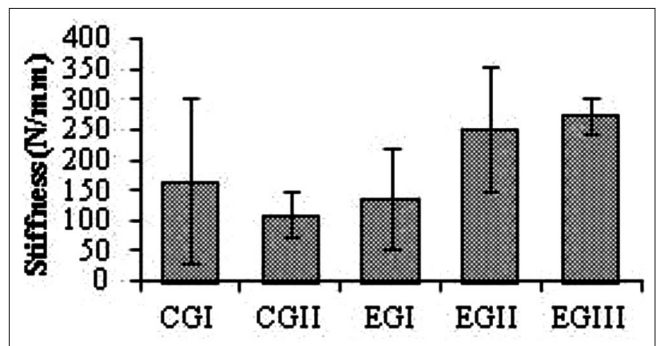
For right bending, CG II had the lowest resistance with the value of 89 Nmm/° and EG II had the highest resistance with the value of 394.2 Nmm/°. CG I (114 Nmm/°) and EG II (117 Nmm/°) had approximately same resistance. EG III had more resistance (292 Nmm/°) than EG I, CG I, and CG II. For left bending, a similar ranking to the right bending could be



**Figure 4:** The Euclidean distance graphic demonstrates the statistically distribution and cluster of the specimens in groups



**Figure 5:** Average stiffness and standard deviation values of the each bending in groups



**Figure 6:** Average stiffness and standard deviation values of the compression test in groups

observed except that EG III was more rigid than EG II, this time with the 3.5% difference. For flexion-extension, the ranking of groups was same as in left bending motion while the difference between EG II and EG III increased to 26%. CG I was almost twice as stiff as CG II and EG I while EG II was 10% more rigid than EG III for rotation.

The stiffness against rotation was the largest in all types of motions. The lowest resistance existed in left-right bendings.

Flexion-extension motions took place after left-right bendings.

The average stiffness values of compression are plotted as in Figure 6. The error bars in this figure indicated the standard deviation of the averages. As could be seen from the Figure 6, the most rigid group in compression was EG III in which was 8.7% more rigid than EG II, but this difference was not meaningful statistically ( $P > 0.05$ ).

Important facts based on the results listed above could be summarized as follows. When CG I and CG II were compared, it could be clearly seen that laminectomy caused instability. CG II had stiffness of  $89 \text{ Nmm}^\circ$  in right bending, but CG I had stiffness of  $114 \text{ Nmm}^\circ$ . This means that the stability was decreased approximately 22% due to LBF.

CG I was more rigid than EG I in all motions ( $P < 0.05$ ). It could be seen that XBPS contributed to stability of the segments. For instance, in right bending, CG I had stiffness of  $114 \text{ Nmm}^\circ$  and EG III had stiffness of  $292 \text{ Nmm}^\circ$ . This indicated that XBPS system increased the stability approximately 156% for right bending. MPS increased the stiffness to  $394 \text{ Nmm}^\circ$  which means stability was increased approximately 245%.

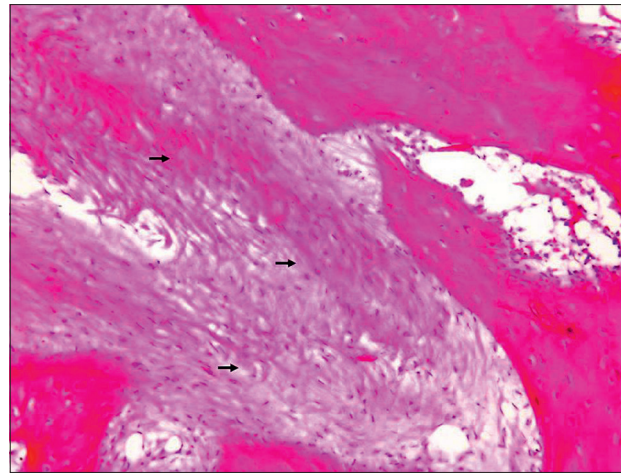
Macroscopic examination revealed the gray-white colored fibrotic granulation tissue on the operation side of the lumbar segments. Axial and sagittal cutting of the lumbar segments showed a strong fibrotic tissue on the laminectomy and facetectomy surfaces. No infection and complication were observed.

In the microscopic examination of facetectomy and laminectomy sides, all specimens of EGs had proliferative connective tissue and new vessel formations. In EG I, no cartilaginous and bone tissue formation were seen microscopically [Figure 7]. In EG II, cartilaginous tissue and reactive bone proliferation were observed on chondroblastic and osteoblastic areas of the proliferative connective tissue on the operation sides. Focally, endochondral bone proliferation was markedly seen [Figure 8]. EG III had the same microscopic findings; however, cartilage and reactive bone proliferation were not as much as EG II [Figure 9].

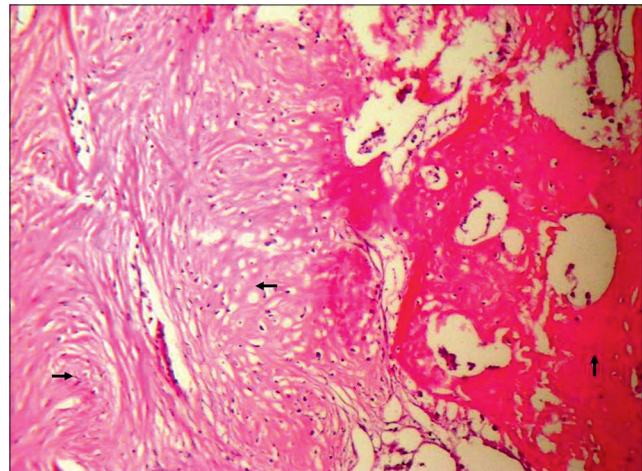
## Discussion

A numerous instrumentation system has been designed for spinal stabilization. Although these systems include the well-designed components such as screws, interconnecting rods, plates, and cross-links, the optimum rigidity of these systems has not been clearly mentioned till now.<sup>[11]</sup> Hence, contribution of the XBPS system was planned in this study as *in vivo*.

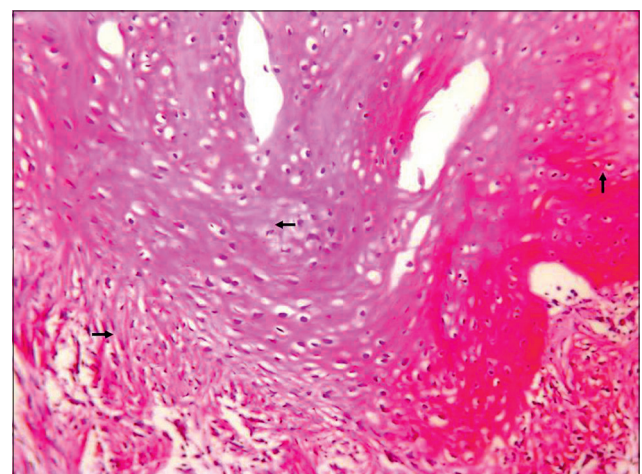
TS provides stability and contributes the fusion between the segments. Although surgical exploration is a more reliable



**Figure 7:** Microscopic view from an experiment of experimental group I shows excessive connective tissue proliferation between the bone trabeculas (right arrows)



**Figure 8:** This view points out the connective tissue proliferation (right arrow), increased osteoblastic activity (left arrow) together with the bone transformation (up arrow) (endochondral ossification) in an experiment of experimental group II



**Figure 9:** In an experiment of experimental group III, microscopic view shows connective tissue proliferation (right arrow), increased osteoblastic and chondroblastic activity (left arrow), and bone transformation (up arrow)



way to evaluate the fusion between the vertebral segments, this method is not suitable due to some drawbacks including surgical risk and trauma.<sup>[1]</sup> Therefore, to evaluate and reveal the fusion rate, between the vertebral segments, a considerable amount of experimental studies were reported.<sup>[4,7-10,12-14]</sup> Here, biomechanical and histological results of the study show the contributing role of XBPS in lumbar segments of the dogs with TS for stabilization.

Screw bending or breaking in the pedicle induces many studies for the evaluation of the pedicle morphometry in humans.<sup>[15]</sup> Transition of the pedicle is elliptic, and wideness of pedicle in coronal plane is major, but minor in the sagittal plane.<sup>[16]</sup> The reported compatible parameters of the transpedicular screwing include pedicle fullness (%), minor wideness of pedicle, pedicle length, and mediolateral angulation of the pedicle.<sup>[12,16]</sup> As a result of the previous study,<sup>[10]</sup> same size metal and xenograft bone screws were used to provide the desired pedicular fullness.

In humans, for lumbar spinal fusion, the roentgen stereophotogrammetric analysis (RSA) has been determined as a good way to compare the *in vivo* behavior for different TS systems.<sup>[1]</sup> RSA was unfeasible because of our clinic conditions. However, radio pact appearances on the facetectomy and laminectomy sites were evident and assessed as fusion formation at the end of 3<sup>rd</sup> month in groups. Furthermore, xenograft bone screws in the pedicle and vertebral corpus appeared siluative because of the resorption.

Spinal plate-screw instrumentation has popularity between the surgeons due to its capacity to increase the fusion rates and stabilize the vertebral segments satisfactorily.<sup>[11]</sup> It has been concluded in a study addressing to some clinical and experimental studies that plate-screw instrumentation increases the fusion formation between vertebral segments.<sup>[17]</sup> Similarly, rigid spinal instrumentation enhances the spinal fusion rate and rise.<sup>[18]</sup> According to our biomechanical test results, it was the most noticeable observations that XBPS system in EG III had the highest average stiffness values for all motions with the exception of right bending and rotation. EG III was 3.5% more rigid than MPS for left bending, 26% for flexion, and 18% for extension; however, these differences were not meaningful ( $P > 0.05$ ).

According to Ito *et al.*,<sup>[18]</sup> type of the spinal instrument is not important to obtain much more fusion formation between segments. They conclude the same fusion formation results both stabilized and unstabilized vertebral segments. Of all groups in the study, histopathological results showed that MPS stabilization in EG II had superiority in terms of fusion formation. No cartilaginous and bone tissue formation in EG I (unstabilized segments) were detected. Proliferative connective and cartilaginous tissue, endochondral bone

proliferation, and new vessel formations were observed both in EG II and EG III.

Because bone graft usage is the most applicable technique to enhance the spinal fusion,<sup>[17]</sup> comparing the EG I histologic results, it can be concluded that EG III (XBPS system) contributes the fusion formation.

## Acknowledgment

The authors thank to Department of Pathology staff in Uludag University, Faculty of Medicine because of the histopathologic evaluations.

## Financial support and sponsorship

Nil.

## Conflicts of interest

There are no conflicts of interest.

## References

1. Johnsson R, Axelsson P, Gunnarsson G, Strömquist B. Stability of lumbar fusion with transpedicular fixation determined by roentgen stereophotogrammetric analysis. *Spine (Phila Pa 1976)* 1999;24:687-90.
2. Benzel EC. *Biomechanics of Spine Stabilization: Principles and Clinical Practice*. New York: McGraw-Hill; 1995. p. 191-3.
3. Chesnut RM, Abitbol JJ, Garfin SR. Surgical management of cervical radiculopathy. Indication, techniques, and results. *Orthop Clin North Am* 1992;23:461-74.
4. Calisir B, Dogan S, Aksoy K, Gorgul S, Ozcan R. Xenograft Bone Plate and Screw Usage in the Anterior Lumbar Stabilization: Experimental Study. 4<sup>th</sup> International Congress on Cerebral Venous System and 4<sup>th</sup> International Congress on the Meningiomas combined with Annual Meeting of Turkish Neurosurgical Society. Istanbul, Turkey; 3-8, June 2002.
5. Csécséi GI, Klekner AP, Dobai J, Lajtos A, Sikula J. Posterior interbody fusion using laminectomy bone and transpedicular screw fixation in the treatment of lumbar spondylolisthesis. *Surg Neurol* 2000;53:2-6.
6. Sano S, Yokokura S, Nagata Y, Young SZ. Unstable lumbar spine without hypermobility in postlaminectomy cases. Mechanism of symptoms and effect of spinal fusion with and without spinal instrumentation. *Spine (Phila Pa 1976)* 1990;15:1190-7.
7. Delécrin J, Aguado E, NGuyen JM, Pyrè D, Royer J, Passuti N. Influence of local environment on incorporation of ceramic for lumbar fusion. Comparison of laminar and intertransverse sites in a canine model. *Spine (Phila Pa 1976)* 1997;22:1683-9.
8. Emery SE, Fuller DA, Stevenson S. Ceramic anterior spinal fusion. Biologic and biomechanical comparison in a canine model. *Spine (Phila Pa 1976)* 1996;21:2713-9.
9. Fuller DA, Stevenson S, Emery SE. The effects of internal fixation on calcium carbonate. Ceramic anterior spinal fusion in dogs. *Spine (Phila Pa 1976)* 1996;21:2131-6.
10. Salci H, Sarigul S, Dogan S, Lekesiz H, Ozcan R, Gorgul OS, *et al.* Contribution of the xenograft bone plate-screw system in lumbar transpedicular stabilization of dogs: An *in vitro* study. *J Vet Sci* 2008;9:193-6.
11. Brodke DS, Bachus KN, Mohr RA, Nguyen BK. Segmental pedicle screw fixation or cross-links in multilevel lumbar constructs. A biomechanical analysis. *Spine J* 2001;1:373-9.
12. Hasegawa K, Takahashi HE, Uchiyama S, Hirano T, Hara T, Washio T, *et al.* An experimental study of a combination method using a pedicle screw and laminar hook for the osteoporotic spine. *Spine (Phila Pa 1976)* 1997;22:958-62.

13. Pintar FA, Maiman DJ, Hollowell JP, Yoganandan N, Droese KW, Reinartz JM, *et al.* Fusion rate and biomechanical stiffness of hydroxylapatite versus autogenous bone grafts for anterior discectomy. An *in vivo* animal study. *Spine (Phila Pa 1976)* 1994;19:2524-8.
14. Poynton AR, Zheng F, Tomin E, Lane JM, Cornwall GB. Resorbable posterolateral graft containment in a rabbit spinal fusion model. *J Neurosurg* 2002;97 4 Suppl: 460-3.
15. McLain RF, McKinley TO, Yerby SA, Smith TS, Sarigul-Klijn N. The effect of bone quality on pedicle screw loading in axial instability. A synthetic model. *Spine (Phila Pa 1976)* 1997;22:1454-60.
16. Brantley AG, Mayfield JK, Koeneman JB, Clark KR. The effects of pedicle screw fit. An *in vitro* study. *Spine (Phila Pa 1976)* 1994;19:1752-8.
17. Karaismailoglu TN, Tomak Y, Andaç A, Ergün E. Comparison of autograft, coralline graft, and xenograft in promoting posterior spinal fusion. *Acta Orthop Traumatol Turc* 2002;36:147-54.
18. Ito M, Fay LA, Ito Y, Yuan MR, Edwards WT, Yuan HA. The effect of pulsed electromagnetic fields on instrumented posterolateral spinal fusion and device-related stress shielding. *Spine (Phila Pa 1976)* 1997;22:382-8.