

Endoscopic carpal tunnel decompression: Comparison of mid- and long-term outcomes of 30 endoscopic and 30 standard procedure carpal tunnel decompression operations

Umit Eroglu, Onur Ozgural, Fatih Yakar, Gökmen Kahiloğulları

Department of Neurosurgery, Faculty of Medicine, Ankara University, Ankara, Turkey

ABSTRACT

Background: Carpal tunnel syndrome is the most frequently seen trap neuropathy leads to pain, paresis, and weakness of hands.

Methods: Totally, 60 patients who underwent endoscopic or standard CTS surgery in İbni Sina Hospital, Medical Faculty of Ankara university in the period of 2009 and 2012 were enrolled in this prospective study.

Results: During 36 months, 60 patients had undergone hand surgery. Totally, 14 male and 46 female patients of this serial had an average age of 51.24 (22-74) years. A number of 26 patients (43%) had left and 34 had (57%) right hand surgery. Complete relief of nocturnal paresis and pain has been shown in the 6th, 12th, and 24th month analyses of endoscopic surgery group results. Two patients in open surgery group underwent second operation due to relapse. The patients in the endoscopic group reported higher satisfaction cosmetically.

Conclusion: Endoscopic carpal tunnel syndrome treatment is alternative and considerable option against standard open methods and due to low morbidity rates its performance is highly prevalent in recent years.

Key words: Carpal tunnel syndrome, decompression, endoscopic

Introduction

Carpal tunnel syndrome (CTS) which is the most frequently seen trap neuropathy leads to pain, paresis, and weakness of hands. Idiopathic type is the most frequent one.^[1] CTS is characterized by positive tunnel test, prolonged distal sensorial and/or motor latency in electromyography (EMG) and increased paresis at nights. Incision of the transverse carpal ligament, which was firstly conducted by Phalen 50 years ago is a very effective and lowrisk treatment option.^[2,3] Open procedures are related with some complications including hypertrophic or painful scar and pain in tenarhypothenar

region.^[4] To eliminate such complications, some new methods were proposed by surgeons. Endoscopic carpal tunnel release operations have been conducted since 1980's. Preference of endoscopic procedure is increasing instead of open methods in recent years.

Materials and Methods

Totally 60 patients who underwent endoscopic or standard CTS surgery in İbni Sina Hospital, Medical Faculty of Ankara University in the period of 2009 and 2012 were enrolled in this prospective study. 30 patients in the endoscopic surgery group had typical CTS symptoms and laboratory findings (EMG). In this series of 60 patients (14 of whom were male

This is an open access article distributed under the terms of the Creative Commons Attribution-NonCommercial-ShareAlike 3.0 License, which allows others to remix, tweak, and build upon the work non-commercially, as long as the author is credited and the new creations are licensed under the identical terms.

For reprints contact: reprints@medknow.com

How to cite this article: Eroglu U, Ozgural O, Yakar F, Kahiloğulları G. Endoscopic carpal tunnel decompression: Comparison of mid- and long-term outcomes of 30 endoscopic and 30 standard procedure carpal tunnel decompression operations. Asian J Neurosurg 2017;12:534-6.

Access this article online	
Quick Response Code:	Website: www.asianjns.org
	DOI: 10.4103/1793-5482.210002

Address for correspondence:

Dr. Onur Ozgural, Ankara University, School of Medicine, İbni Sina Hospital, Ankara, Turkey.
E-mail: onurozgural@yahoo.com

and 46 were female), we studied some factors including gender, age, results of surgery, and related complications. The 30 patients (6 males and 24 females) who underwent standard procedure had a mean age of 52 years. Three of 6 male patients and 15 of 24 female patients underwent standard CTS surgery in their right hand while the remainders were operated in the left hand. Mean distal latency was 5.8 in the standard open surgery group while 5 of them had concomitant diabetes and thyroid diseases. Both groups were administered regional intravenous anesthesia. Duration of operation ranged between 11 and 24 min in the standard surgery group. The patients (8 males and 22 females) who underwent endoscopic surgery had a mean age of 50 years. Four of 8 male patients and 12 of 22 female patients underwent endoscopic CTS surgery in their right hand while the remainders were operated in their left hand. Mean distal latency was found to be 5.9 while 7 patients presented concomitant diabetes in this group. Duration of operation ranged between 4 and 8 min in the endoscopic surgery group. Mean followup duration was 28 months for both groups. The data were analyzed according to Oertel criteria at 1st, 6th, 12th, and 24th months of the followup. Relief of nocturnal paresis and pain consisted the main favorable criteria at 6th and 12th months. At the analysis of 24th month, additional criteria such as capability of maintaining daily activities were interrogated. The existence of nocturnal paresis and pain in the 6th and 12th analysis results was accepted as midterm treatment failure. Longterm failure was defined as additionally existence of restricted daily activities at the 2nd year analysis. Relapsed patients were not included in the analysis in both groups.

Surgical route

Chow technique was preferred in endoscopic operation.^[5,6] Various instruments including knives, dissectors, trocars, and rigid endoscope have been provided before the operation. First, a transverse line of 1-1.5 cm from proximal end of pisiform bone to the radial site has been marked. From the tip of this line, a 0.5 cm vertical line to the proximal direction has been added. The addition of a 1 cm transverse line to the radial direction determined the entrance site on hand wrist [Figure 1]. To determine the exit site on the palm, a transverse line to ulnar direction applied from completely abducted thumb's lower edge. Consequently, a perpendicular line between third and fourth fingers intersected this line. Finally, we determined the exit point according to the bisector of this right angle formed by these lines [Figure 2]. We confirmed the proper site of cannule by obtaining vision of transverse fibers of transverse carpal ligament [Figure 3]. Surging of adipose tissue to tunnel soon after incision of the ligament paused achieving decompression.

Results

During 36 months, 60 patients had undergone hand surgery. Totally 14 male and 46 female patients of this serial had an

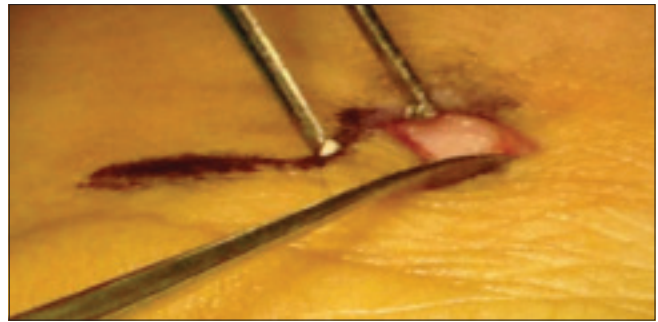


Figure 1: Site of entry is determined by Chow method. A small incision is needed to install the trochar

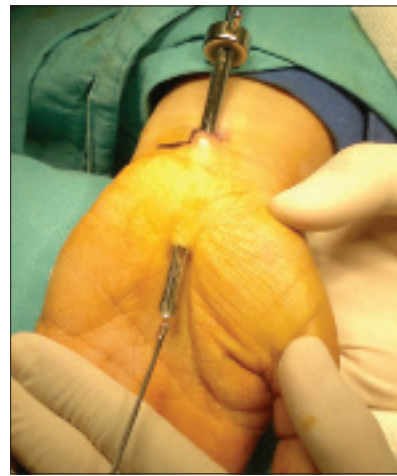

Figure 2: Trochar enables to use the exiting hole. Endoscope and ligament knives are essential to start the surgery

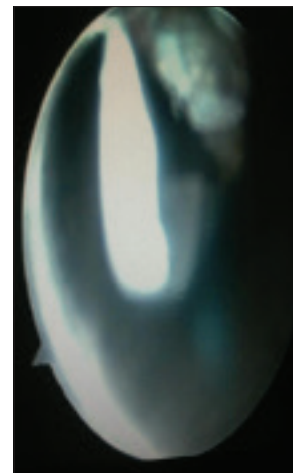


Figure 3: Appearance of transverse ligament's fibers is a marker of proper siting of trochar

average age of 51.24 (22-74). 26 patients (43%) had left and 34 had (57%) right hand surgery. Mean symptomatic duration was 26.8 months (5-36 months). A significant difference could not be determined regarding gender, age, and distal latencies between two groups. Complete relief of nocturnal paresis and pain has been shown in the 6th, 12th, and 24th months analysis of endoscopic surgery group results. The patients reported

that they had a favorable complete relief regarding nocturnal paresis in midterm. Patients did not experience complications such as hemorrhage or infection. Four of 30 patients in standard procedure group could not have complete relief of nocturnal paresis. Two patients in this group underwent an operation due to relapse. One patient had oral antibiotherapy due to a minor superficial surgical site infection. None of the patients had experienced a permanent morbidity. The patients in the endoscopic group reported higher satisfaction cosmetically.

Discussion

The open surgical method which was first conducted by Phalen in 1950's, has been accepted as being effective and low risk as a major treatment option of CTS for a long time.^[7,8] Some complications regarding painful and hypertrophic scars and delay of daily functions led to widespread use of new methods such as endoscopic surgery. There are many studies reporting favorable results of endoscopic surgery in the literature.^[9] These studies reported treatment achievements up to 92–98% with followup duration of 5 years. They also suggested very few relapses (0–10%).^[4,10] For example, Oertel *et al.* reported a 98% achievement in relief of nocturnal paresis in their series.^[11] Studies comparing ECTS surgery and standard procedures demonstrated more favorable results for ECTS treatment. Lower postoperative pain and permanent scar complications with faster functional recovery were encountered with ECTS treatment.^[12-14] In their review, Benson *et al.* detected constitutional complication rates at 0.49% and 0.19% for open and endoscopic techniques, respectively.^[1]

ECTS treatment is a feasible, well tolerated and considerable option against standard open methods and due to low morbidity rates its performance is highly prevalent in recent years.

Conclusion

Endoscopic carpal tunnel syndrome treatment is a feasible, well tolerated and considerable option against standard open

methods and due to low morbidity rates its performance is highly prevalent in recent years.

Financial support and sponsorship

Nil.

Conflicts of interest

There are no conflicts of interest.

References

1. Benson LS, Bare AA, Nagle DJ, Harder VS, Williams CS, Visotsky JL. Complications of endoscopic and open carpal tunnel release. *Arthroscopy* 2006;22:919-24, 924.e12.
2. Chow JC, Hantes ME. Endoscopic carpal tunnel release: Thirteen years' experience with the Chow technique. *J Hand Surg Am* 2002;27:10118.
3. Kahraman S, Kafadar A, Akbörü M, Atabey C. Endoscopic carpal tunnel release using the biportal technique. *Mil Med* 2006;171:1502.
4. McNally SA, Hales PF. Results of 1245 endoscopic carpal tunnel decompressions. *Hand Surg* 2003;8:1116.
5. Chow JC. Endoscopic release of the carpal ligament: A new technique for carpal tunnel syndrome. *Arthroscopy* 1989;5:1924.
6. Chow JC. The Chow technique of endoscopic release of the carpal ligament for carpal tunnel syndrome: Four years of clinical results. *Arthroscopy* 1993;9:30114.
7. Phalen GS. Reflections on 21 years' experience with the carpal tunnel syndrome. *JAMA* 1970;212:13657.
8. Phalen GS. The carpal tunnel syndrome. Clinical evaluation of 598 hands. *Clin Orthop* 1972;83:2940.
9. Chow JC. Endoscopic release of the carpal ligament for carpal tunnel syndrome: 22 month clinical result. *Arthroscopy* 1990;6:28896.
10. Varitimidis SE, Herndon JH, Sotereanos DG. Failed endoscopic carpal tunnel release. Operative findings and results of open revision surgery. *J Hand Surg Br* 1999;24:4657.
11. Oertel J, Schroeder HW, Gaab MR. Dual portal endoscopic release of the transverse ligament in carpal tunnel syndrome: Results of 411 procedures with special reference to technique, efficacy, and complications. *Neurosurgery* 2006;59:33340.
12. Brown RA, Gelberman RH, Seiler JG 3rd, Abrahamsson SO, Weiland AJ, Urbaniak JR, *et al.* Carpal tunnel release. A prospective, randomized assessment of open and endoscopic methods. *J Bone Joint Surg Am* 1993;75:126575.
13. Filippi R, Reisch R, El Shki D, Grunert P. Uniportal endoscopic surgery of carpal tunnel syndrome: Technique and clinical results. *Minim Invasive Neurosurg* 2002;45:7883.
14. Palmer DH, Paulson JC, Lane Larsen CL, Peulen VK, Olson JD. Endoscopic carpal tunnel release: A comparison of two techniques with open release. *Arthroscopy* 1993;9:498508.