

# Combination of inflammatory and amlodipine induced gingival overgrowth in a patient with cardiovascular disease

Mohan Kumar Pasupuleti, S. V. V. S. Musalaiah, M. Nagasree, Aravind Kumar P.

Department of Periodontics, St. Joseph Dental College, Eluru, Andhra Pradesh, India

## Access this article online

Website: [www.avicennajmed.com](http://www.avicennajmed.com)

DOI: 10.4103/2231-0770.118462

## Quick Response Code:



## ABSTRACT

Gingival overgrowth (GO) is among one of the most important clinical features of gingival pathology frequently seen in periodontal clinic. Amlodipine is a comparatively new calcium channel blocker and is being used with increasing frequency in the management of hypertension and angina. A 48-year-old Indian woman who was on amlodipine for 3 years for hypertension reported to the department of periodontics with the complaint of swollen, unesthetic gums. The patient developed GO 6 months before her first visit to dental hospital. She developed GO very rapidly due to the increase in amlodipine dose due to the severe angina attack 6 months before and due to the use of cholesterol (CHO) lowering drug. The main aim of the case report is to study the severity of amlodipine induced GO in a patient with cardiovascular disease (CVD) and to identify the role of subgingival microorganisms on inflammatory gingival enlargement in the same patient. The severity and rapidity of gingival enlargement in this report could have been triggered by doubling the dose of amlodipine and concomitant use of CHO lowering drug.

**Key words:** Acute myocardial infarction, amlodipine, angina, gingival overgrowth

## INTRODUCTION

The gingiva and associated soft tissues of the periodontium may be enlarged in response to various interactions between the host and the environment. Etiology of gingival overgrowth (GO) is multifactorial. It has been frequently associated with inflammatory changes and the other factors related to this condition are hereditary, malignancies, and those resulting from adverse effects associated with the systemic administration of certain drugs.<sup>[1]</sup>

“Gingival enlargement” or “gingival overgrowth” is the preferred term for all medication-related gingival lesions. Currently, more than 20 prescription medications are associated with gingival enlargement.<sup>[2]</sup>

Anticonvulsants, cyclosporin A, and calcium channel blockers are the three different groups of pharmaceutical

agents that have been commonly associated with the occurrence of GO in susceptible individuals.<sup>[3]</sup>

All these factors are associated with the disproportionate, disfiguring, and functionally compromising overgrowth of gingival tissues that have provided new niches for the growth of microorganisms, results in a serious concern for the patients. This made the clinicians to generate the most investigative attention in the scientific community on gingival enlargements.<sup>[1,3]</sup>

Prevalence of the drug induced gingival enlargement is 3-20% compared to most important inflammatory gingival enlargements. Antihypertensive drugs in the calcium channel blocker group are used extensively in elderly patients who have angina or peripheral vascular disease. Amlodipine, an agent of dihydropyridine, a third generation calcium channel blocker that is used for treatment of hypertension and angina, causes GO as an adverse effect.<sup>[4]</sup>

**Address for correspondence:** Dr. Mohan Kumar, Flat no. 303, R.K Gold Apartments, Sriram nagar, 5<sup>th</sup> Road, Eluru, West Godavari District, Andhra Pradesh, India. E-mail: [suppimohan@gmail.com](mailto:suppimohan@gmail.com)

Though the pharmacologic effect of each class of the drugs causing GO is different and directed toward various primary target tissues, all of them seem to have similar adverse effect on a secondary target tissue, that is, the gingival connective tissue, causing common clinical and histopathological findings.<sup>[4,5]</sup>

Calcium channel blockers act by inhibiting calcium ion influx across the cell membrane of cardiac and smooth muscle cells thereby blocking the intracellular mobilization of  $Ca^{++}$ . It causes dilatation of coronary arteries and arterioles as well as decreased myocardial contractility and oxygen demand. The first report of occurrence of GO associated with calcium channel blocker (nifedipine) was reported by Ramon *et al.*, 1984. Amlodipine, flodipine, diltiazem, nitrendipine, and verapamil are the other agents associated with this side effect.<sup>[6,7]</sup>

GO has been reported in 15-83% of patients taking nifedipine (Barak *et al.*, 1987<sup>[8]</sup>; Fattore *et al.*, 1991<sup>[9]</sup>), approximately 21% of patients taking diltiazem (Steel *et al.*, 1994<sup>[10]</sup>), about 4% of those medicated with verapamil (Miller *et al.*, 1992<sup>[11]</sup>) and 1.7% for amlodipine (Ellis *et al.*, 1999).

Several factors are responsible for the pathogenesis of drug induced GO as discussed by Seymour *et al.* These factors include: (1) Age, (2) genetic predisposition, (3) pharmacokinetic variables, (4) alteration in gingival connective tissue homeostasis, (5) histopathology, (6) ultrastructural factors, (7) inflammatory changes, and (8) drug action on growth factors.<sup>[6,12]</sup>

A number of risk factors also relate closely to the development of atherosclerotic disease and risk for cardiovascular events (e.g., myocardial infarction and stroke), including age, gender, hypertension, diabetes mellitus, smoking, and low serum levels of high density lipoprotein (HDL) cholesterol (CHO). Over the past 2 decades, inflammation has emerged as an integrative cardiovascular disease (CVD) factor. Inflammation can operate in all stages of this disease from initiation through progression and, ultimately, the thrombotic complications of atherosclerosis.<sup>[13]</sup>

It is well recognized that calcium channel blockers, which are strong inhibitors of cytochrome P450 3A4, coadministered with statins that are metabolized by the same isoenzyme before biliary and renal excretion may lead to reduced clearance of both the drugs, with an increase in adverse effects.<sup>[14]</sup>

Nevertheless, when statins and calcium channel blockers are coprescribed, especially at high doses, there may possibly be

an increase in adverse effects, such as GO. However, the exact mechanism remains unknown. This case report presents the management of a case of a combination of drug-influenced gingival enlargement with acute myocardial infarction.<sup>[14,15]</sup>

## CASE PRESENTATION

A 48-year-old Indian woman was referred to the department of periodontology, with the chief complaint of swollen gums. She felt discomfort with the disfigurement of gums which appeared unesthetic due to its more severity and there was bleeding and difficulty while chewing food.

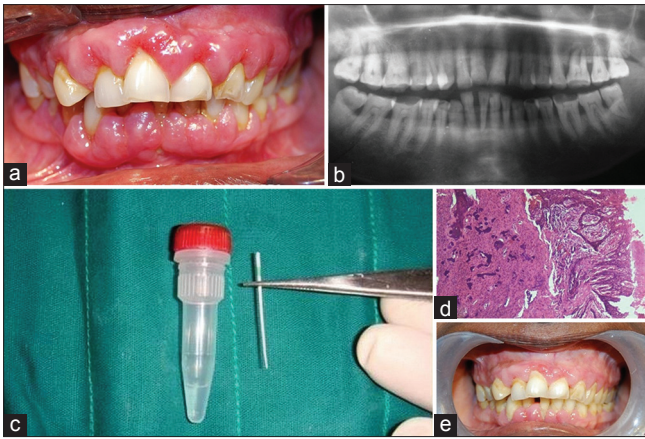
Past medical history revealed that she is under medication for hypertension with amlodipine (10 mg/day orally) for the last 2 years and 6 months. The amlodipine dose was increased to 50 mg/day orally and statins were prescribed due to the acute angina attack and hypercholesterolemia before 6 months of the dental visit.

### Oral examination

Clinical examination was carried out by assessing the periodontal status by plaque index (PI), gingival index (GI), Russel's periodontal index. The patients oral hygiene status revealed the presence of more amount of plaque and some amount of calculus on both anterior and posterior surfaces of the teeth due to the presence of new niches for accumulation of plaque and microorganisms. There was generalized bleeding on probing and generalized probing depths ranging from 3 to 8 mm with greatest depths in relation to mandibular anteriors. Due to the outward enlargement of gingiva, there were no deep periodontal pockets.

Intraorally, there was generalized GO on the labial and lingual/palatal surface of the maxillary and mandibular teeth, which was more pronounced in the labial surfaces than the lingual and palatal surfaces. The interdental papillae were enlarged, fibrous, and lobulated in appearance mainly around the mandibular and maxillary anterior teeth [Figure 1a].

In this case report, photographic analysis by Ellis and Seymour was used for assessing the gingival encroachment or overgrowth on adjacent surfaces for a gingival unit (0 = no encroachment of interdental papilla on tooth surface, 1 = mild encroachment producing a blunted papilla tip, 2 = moderate encroachment involving lateral spread of papilla across buccal tooth surface of less than one quarter tooth width, 3 = marked encroachment of papilla, more than One-fourth tooth width with loss of interdental papilla form).<sup>[16]</sup> In this case report, score 3 severity of gingival enlargement was observed.



**Figure 1:** (a) Preoperative view showing gingival overgrowth, (b) Orthopantomograph showing generalized horizontal bone loss, (c) Plaque sample collected by paperpoints and sent for RNA hybridization (d) Histologic view showing elongated rete pegs and dense connective tissue, (e) Postoperative view

Grade III mobility was observed in relation to mandibular anteriors. Generalized reddish color, purulent discharge in relation to mandibular anteriors and generalized bleeding on probing were observed due to the generalized inflammation of gingiva. Radiographic examination revealed generalized horizontal bone loss with more destruction of bone in relation to maxillary and mandibular anterior region [Figure 1b].

#### Laboratory analysis

Blood sample was taken at the patients first visit to the dental hospital. Serum total CHO, HDL, low density lipoprotein (LDL), and triglycerides (TG) were determined by autoanalyzer in the clinical laboratory.

#### Microbiologic tests

Several methods have been employed for the detection of putative periodontal pathogens in subgingival samples to identify the microbiologic profile of periodontitis. Here we had chosen a genetic microbiologic test to identify microbiologic profile in amlodipine induced gingival enlargement with CVD.

A paper point made of cellulose is introduced into the deep periodontal pocket. After 10 s, the point is withdrawn and placed in a RNA stabilizer buffer and sent for hybridization [Figure 1c]. The IAI Pado Test 4.5 (IAI ESCHENWEG 6. CH-4528 ZUCHWIL/SWITZERLAND) which is a genetic test used in this case study allowed for the identification and quantification of bacteria which have a preponderant pathogenic role in periodontitis.

The IAI Pado Test 4.5 is a biologic molecular test which allowed the identification and quantification. The specific periodontal pathogens like *Aggregatibacter actinomycetemcomitans* (Aa),

*Porphyromonas gingivalis* (Pg), *Tannerella forsythia* (Tf), and *Treponema denticola* (Td) were identified by this test.

#### Histologic examination

Biopsy was taken during the surgical phase and sent to the laboratory. It revealed mixture of dense and loose fibrous components with the chronic inflammatory cell infiltrate in the connective tissue and elongation of rete pegs in the epithelium. On the basis of patient's history, clinical features, laboratory investigations for lipid profile, microbiologic profile, and biopsy reports, a diagnosis of amlodipine induced GO in a patient with CVD was made.

### CASE MANAGEMENT

#### Prevention

In a drug induced gingival enlargement susceptible patient, GO cannot be prevented just by removing the local factors. Periodontal maintenance therapy for at least 3 months is recommended and each appointment should be scheduled by giving oral hygiene instructions with complete oral prophylaxis.

#### Treatment

##### Drug substitution

Substitution or withdrawal of drug causing gingival enlargement is more effective during treatment. The patient was referred to a physician to replace the drug causing the adverse side effect and after thorough assessment of the severity of gingival enlargement due to the combined effect of inflammation and amlodipine, the drug was substituted to atenolol 50 mg/day orally to treat hypertension.

##### Nonsurgical treatment

Complete scaling and root planing was done for supragingival and subgingival calculus removal at the first visit. Review after 1 week showed some relief but there was not much noticeable reduction in overgrowth even after 1-3 months follow-up due to substitution of drug and periodontal maintenance therapy.

Though the most effective treatment of drug related gingival enlargement is withdrawal or substitution of medication. Unfortunately, not all patients respond to this mode of treatment especially those with long standing gingival lesions. 3 month interval for periodontal maintenance therapy has been recommended after the substitution or cessation of drug in gingival enlargement patients. Surgical reduction of the enlarged tissue is frequently necessary to accomplish an esthetic and functional outcome when the drug substitution alone does not reduce GO.

### Surgical therapy

Patient requested for surgical correction of gingival on upper and lower quadrants, except for lower anteriors which had grade II mobility. Gingival enlargement was resected segment wise by modified flap operation except for mandibular anteriors which had grade III mobility and was extracted later.

### Clinical outcome and patient responses

There was no discomfort or side effects were observed in the postoperative period. At 3 months after the treatment of maxillary overgrowth, there was no recurrence of GO and the patient expressed a high level of satisfaction and willingness to treat remaining areas of overgrowth in mandibular posterior regions. No recurrence of GO observed at 6 months after the treatment.

Clinical parameters 6 months postoperative surgery were shown in Table 1.

## DISCUSSION

Gingival enlargement has become a serious concern for both the patients and clinicians because of the disfigurement of gingiva which helped in the production of new niches for microorganisms. These implications lead to addition of inflammatory gingival enlargement to the drug induced gingival enlargement.<sup>[17,18]</sup>

Clinical manifestation of GO commonly appears within 1-3 months after initiation of treatment with the associated drugs. In the present case, although the patient was taking 10 mg amlodipine for 2 years and 6 months, GO was noted only 6 months before her initial visit to the dental hospital. The severity of gingival enlargement is due to the increase in dose of amlodipine and also due to the prescription of CHO lowering drug.

When statins and calcium channel blockers are prescribed together, especially at high doses, there may possibly be an increase in adverse effects, such as gingival enlargement. This is because calcium channel blockers, which are strong inhibitors of cytochrome P450 3A4, coadministered with statins that are metabolized by the same isoenzyme before biliary and renal excretion may lead to reduced clearance of both the drugs, with an increase in adverse effects.<sup>[14,15,17]</sup>

This case report presents the management of a case of a combination of drug influenced gingival enlargement in a patient with CVD and hypercholesterolemia.

Blood samples were taken on admission from the patient. Serum total CHO, HDL, LDL, and TG were determined by

autoanalyzer in the clinical laboratory [Table 1].

The lipid profile showed low HDL and high LDL levels at base line when compared to the 2<sup>nd</sup> and 3<sup>rd</sup> visits. TG and CHO levels were high in 1<sup>st</sup> visit compared to 2<sup>nd</sup> and 3<sup>rd</sup> visits [Table 2].

In this case, microbiologic analysis by IAI Pado Test 4.5 showed all the putative periodontal pathogens with detection frequency of *A. actinomycetemcomitans*, (12) *P. gingivalis*, (6) *P. intermedia*, (3) and *T. forsythia* (2) in the sites of more probing depths when compared to the levels after nonsurgical and surgical treatment [Table 3]. These results confirm the association of inflammatory gingival enlargement with drug induced overgrowth. These results are in accordance with the recent epidemiologic study by Li *et al.*, in 2008 which showed the increase in attachment loss and bone loss in patients taking nifedipine as an antihypertensive.<sup>[19-21]</sup>

Histopathological examination revealed the mixture of dense and loose fibrous components with chronic inflammatory cell infiltrate in the connective tissue. Epithelium showed acanthosis and elongation of rete pegs [Figure 1d].

**Table 1: Periodontal parameters**

Visits	PI (mean)	GI (mean)	PPD (mean)	Russels index
1 <sup>st</sup> visit (baseline)	2.60	2.49	6.09	3.31
2 <sup>nd</sup> visit (after nonsurgical therapy)	2.28	1.58	2.10	0.64
3 <sup>rd</sup> visit (after surgical therapy)	1.05	1.26	1.89	0.68

The above table demonstrates high periodontal parameters (PI: plaque index, GI: gingival index, PPD: mean probing pocket depth, and Russel's periodontal index) at first visit compared to second and third visit

**Table 2: Lipid profile**

Visits	HDL (mg/dL)	LDL (mg/dL)	TG (mg/dL)	CHO (mg/dL)
1 <sup>st</sup> visit (baseline)	41	160.80	342.0	262.10
2 <sup>nd</sup> visit (after nonsurgical therapy)	42.65	155.10	312.85	226.05
3 <sup>rd</sup> visit (after surgical therapy)	44.10	122.0	165.00	183.80

This table demonstrates low high density lipoprotein (HDL) and high low density lipoprotein (LDL) levels at baseline when compared to the second and third visits. Triglycerides (TG) and cholesterol (CHO) levels were high in first visit compared to second and third visits

**Table 3: Detection frequency of microorganisms by IAI PADO TEST 4.5**

Groups	Aa	Pg	Pi	Tf
1 <sup>st</sup> visit	12	6	3	2
2 <sup>nd</sup> visit	6	2	1	0
3 <sup>rd</sup> visit	2	0	0	0

The above table demonstrates Aggregatibacter actinomycetemcomitans (Aa), Porphyromonas gingivalis (Pg), Prevotella intermedia (Pi), Tanerella forsythia (Tf) detection frequency in all the three visits by IAI PADO TEST 4.5

Generalized gingival enlargement was reported and the combination of inflammatory and drug induced overgrowth is more pronounced in mandibular anterior region due to the more plaque accumulation.<sup>[22,23]</sup> Periodontal pocket depths from 3 to 8 mm were recorded with greater depths up to 8 mm in relation to mandibular anteriors. Grade III mobility was recorded in relation to mandibular anteriors which were extracted during the maintenance phase according to the patients' acceptance.

In this case, surgical treatment was done only after 3 months after withdrawal of the drug causing overgrowth of gingival and even after the completion of the nonsurgical therapy.

Patient was recalled for every 2 weeks up to 6 months for maintenance therapy [Figure 1e]. Patient was satisfied with the outcome of the treatment chosen for gingival enlargement and finally she accepted for the extraction of grade III mobile teeth in relation to mandibular anteriors which showed the combination of inflammatory and drug induced gingival GO.

## CONCLUSION

This case further highlights the role of amlodipine in gingival enlargements when the dose is increased along with the prescription of CHO lowering drug in a patient with CVD. I, further emphasize the importance of biopsy examination, microbiologic profile for the confirmation of results in every such cases with the combination of inflammatory and drug induced enlargements.

## ACKNOWLEDGEMENT

We thank Prof. Dr. K. Krishna Murthy and Prof. Dr. D. Roopa and Prof. Dr. N. Ravindra Reddy, C.K.S Teja Institute of Dental Sciences for their extreme support throughout my post graduation studies. We also acknowledge Dr. Supraja, Mr. and Mrs. Sreedhar, Mr. and Mrs. Chandra Mohan, Mr. Vinod and Mrs. Usha Rani for partly funding for the parameters used in this case report.

## REFERENCES

1. Newman MG, Takei HH, Klokkevold PR, Carranza FA. Text book of clinical Periodontology. 11<sup>th</sup> ed. Elsevier; p. 373-88.
2. Rees TD, Levine RA. Systemic drugs as a risk factor for periodontal disease initiation and progression. *Compend Contin Educ Dent* 1995;16:20-42.
3. Ellis JS, Seymour RA, Steele JG, Robertson P, Butler TJ, Thomason JM. Prevalence of gingival overgrowth induced by calcium channel blockers:

- A community-based study. *J Periodontol* 1999;70:63-7.
4. Seymour RA, Thomason JM, Ellis JS. The pathogenesis of drug-induced gingival overgrowth. *J Clin Periodontol* 1996;23:165-75.
5. Hallmon WW, Rossmann JA. The role of drugs in the pathogenesis of gingival overgrowth. A collective review of current concepts. *Periodontol* 2000 1999;21:176-96.
6. Miranda J, Brunet L, Roset P, Berini L, Farre M, Mendieta C. Prevalence and risk of gingival enlargement in patients treated with nifedipine. *J Periodontol* 2001;72:605-11.
7. Ramon Y, Behar S, Kishon Y, Engelberg IS. Gingival hyperplasia caused by nifedipine- a preliminary report. *Int J Cardiol* 1984;5:195-206.
8. Barak S, Engelberg IS, Hiss Z. Gingival hyperplasia caused by nifedipine: Histopathologic findings. *J Periodontol* 1987;58:639-42.
9. Fattore L, Stablein M, Bredfeldt G, Semla T, Moran M, Doherty-Greenberg JM. Gingival hyperplasia: A side effect of nifedipine and diltiazem. *Spec Care Dentist* 1991;11:107-9.
10. Steel RM, Schuna AA, Schreilber RT. Calcium antagonist-induced gingival hyperplasia. *Ann Intern Med* 1994;120:663-4.
11. Miller CS, Damm DD. Incidence of verapamil-induced gingival hyperplasia in a dental population. *J Periodontol* 1992;63:453-6.
12. Meisel P, Schwahn C, John U, Kroemer HK, Kocher T. Calcium antagonists and deep gingival pockets in the population-based SHIP study. *Br J Clin Pharmacol* 2005;60:552-9.
13. Friedewald VE, Kornman KS, Beck JD, Genco R, Goldfine A, Libby P, *et al.* American Journal of Cardiology; Journal of Periodontology. The American Journal of Cardiology and Journal of Periodontology editors' consensus: Periodontitis and atherosclerotic cardiovascular disease. *J Periodontol* 2009;80:1021-32.
14. Azie NE, Brater DC, Becker PA, Jones DR, Hall SD. The interaction of diltiazem with lovastatin and pravastatin. *Clin Pharmacol Ther* 1998;64:369-77.
15. Smitha K. Amlodipine-induced gingival overgrowth in a patient with uncontrolled type 2 diabetes mellitus with hypercholesterolemia: A case report. *Clinical Advances in Periodontics*. Vol. 2, No. 2, 2012.
16. Ellis JS, Seymour RA, Robertson P, Butler TJ, Thomason JM. Photographic scoring of gingival overgrowth. *J Clin Periodontol* 2001;28:81-5.
17. Boltchi FE, Rees TD, Iacopino AM. Cyclosporine A - induced gingival overgrowth: A comprehensive review. *Quintessence Int* 1999;30:775-83.
18. Meller AT, Rumjanek VM, Sansone C, Allodi S. Oral mucosa alterations induced by cyclosporin in mice: Morphological features. *J Periodontol Res* 2002;37:412-5.
19. Triveni MG, Rudrakshi C, Mehta DS. Amlodipine induced gingival overgrowth. *J Indian Soc Periodontol* 2009;13:160-3.
20. Shouda J, Nakamoto H, Sugahara S, Okada H, Suzuki H. Incidence of gingival hyperplasia caused by calcium antagonists in continuous ambulatory peritoneal dialysis patients. *J Clin Periodontol* 2004;31:126-31.
21. Nakou M, Kamma JJ, Andronikaki A, Mitsis F. Subgingival microflora associated with nifedipine-induced gingival overgrowth. *J Periodontol* 1998;69:664-9.
22. Li X, Luan Q, Wang X, Sha Y, He L, Cao C, *et al.* Nifedipine intake increases the risk for periodontal destruction in subjects with type 2 diabetes mellitus. *J Periodontol* 2008;79:2054-9.
23. Marshall RI, Bartold PM. A clinical review of drug-induced gingival overgrowth. *Aust Dent J* 1999;44:219-32.

**Cite this article as:** Pasupuleti MK, Musalalah S, Nagasree M, Kumar PA. Combination of inflammatory and amlodipine induced gingival overgrowth in a patient with cardiovascular disease. *Avicenna J Med* 2013;3:68-72.

**Source of Support:** Nil, **Conflict of Interest:** None declared.