

## CASE REPORT

# Uterine leiomyoma with spontaneous intraleiomyoma hemorrhage, perforation, and hemoperitoneum in postmenopausal woman: Computed tomography diagnosis

Sultan R. Alharbi

Department of Radiology and Medical Imaging, King Khalid University Hospital, King Saud University, Riyadh, Kingdom of Saudi Arabia

## Access this article online

Website: [www.avicennajmed.com](http://www.avicennajmed.com)

DOI: 10.4103/2231-0770.118465

## Quick Response Code:



## ABSTRACT

Spontaneous intraleiomyoma hemorrhage, perforation, and hemoperitoneum are very rare complications of uterine leiomyoma. We report a case of postmenopausal woman who presented with acute abdomen found to have intraleiomyoma hemorrhage, perforation, and hemoperitoneum. Our case also illustrates the computed tomography findings of such complications of uterine leiomyoma.

**Key words:** Fibroids, hemoperitoneum, intraleiomyoma hemorrhage, perforation, postmenopausal woman

## INTRODUCTION

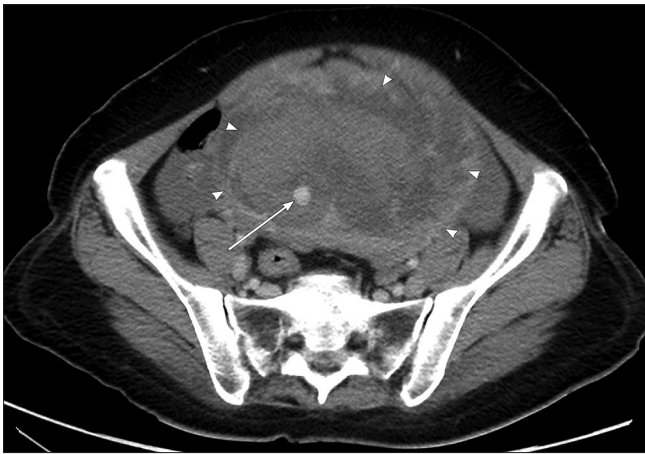
Uterine leiomyomas (fibroids) are the most common pelvic tumors affecting females in the fertile age group.<sup>[1]</sup> These benign tumors are hormone-dependent, responding to both estrogen and progesterone; they often increase in size during pregnancy and usually decrease in size after menopause.<sup>[2]</sup> Acute complications of fibroids are rarely seen but may be serious.<sup>[1]</sup> Spontaneous hemoperitoneum due to fibroid rupture is a rare entity with less than 100 cases reported in the literature.<sup>[3,4]</sup> Intratumor massive bleeding leading to hypovolemia is extremely rare. Only two cases were reported by Koide *et al.*, and Manopunya *et al.*,<sup>[4]</sup> just after delivery. In this case report, we report the case of spontaneous uterine intraleiomyoma hemorrhage, perforation, and hemoperitoneum in postmenopausal woman diagnosed by computed tomography (CT) and confirmed by laparotomy and pathological diagnosis.

## CASE REPORT

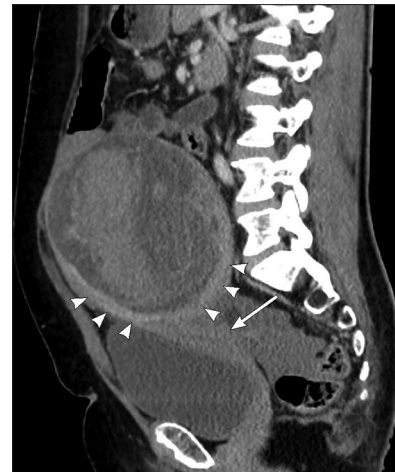A 55-year-old multiparous postmenopausal woman presented to our emergency department with acute sudden lower abdominal pain for 2 h associated with dizziness.

She denied trauma or vaginal bleeding and has no other associated symptoms. Her last menstrual period was 1 year back. Her medical history is significant for uterine fibroids only. On general examination, she had mild pallor. Her vital signs were stable. Abdominal examination revealed distension of lower abdomen with diffuse tenderness and guarding. A firm tender mass was felt arising from the pelvis. Her lab results were within normal limits except hemoglobin level was 10.4 g/dL. CT scan of abdomen and pelvis with intravenous contrast was performed which revealed a large uterine mass arising from the fundus with heterogeneous appearance and active contrast extravasation inside it [Figures 1 and 2]. It also showed an evidence of perforation at the fundus and high density moderate-free fluid (hemoperitoneum) [Figures 3 and 4]. A repeated hemoglobin level after 2 h was 8.5 g/dL. Therefore, two packed red blood cells were given and the patient was taken emergently to operating room. Laparotomy was done and revealed enlarged uterus with fundal perforation and clot and tissue coming out from the perforation site as well as about 1 L of hemoperitoneum. A total hysterectomy with bilateral salpingo-oophorectomy was performed. The patient recovered after surgery with uneventful postoperative course and discharged home.

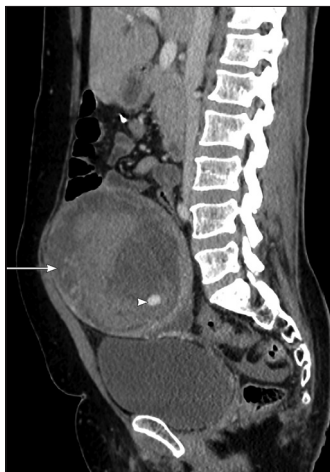**Address for correspondence:** Dr. Sultan R. Alharbi, PO Box 7805, Riyadh 11472, Kingdom of Saudi Arabia. E-mail: [drsultan000@gmail.com](mailto:drsultan000@gmail.com)



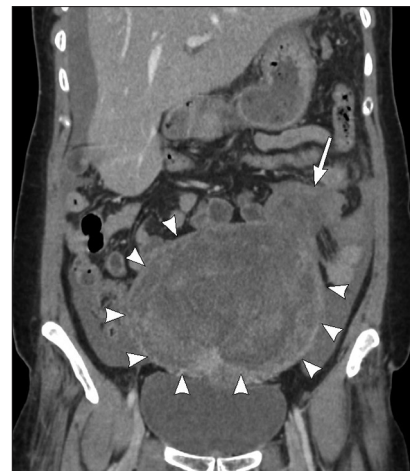**Figure 1:** Post contrast axial computed tomography image showing a large heterogeneous pelvic mass “arrow heads” and high attenuation area inside it “arrow” suggesting active contrast extravasation



**Figure 2:** Post contrast sagittal reformatted computed tomography image showing heterogamous pelvic mass “arrow heads” arising from uterine fundus “arrow”



**Figure 3:** Post contrast sagittal reformatted computed tomography image showing heterogeneous pelvic mass “arrow” and high attenuation area inside it “arrow head,” suggesting active contrast extravasation



**Figure 4:** Post contrast coronal reformatted computed tomography image showing heterogeneous mass “arrow heads” with a defect at its superior aspect “arrow” in keeping with perforation as well as moderate amount of free fluid of high density, suggesting hemoperitoneum

Gross pathological examination revealed enlarged uterus measured 15 × 14 × 9 cm. Bisected uterus showed solid mass measured 15 × 12 × 7 cm arising from the fundus with evidence of perforation. On microscopic examination, a cellular leiomyoma with evidence of hemorrhagic infarction is found. No malignant cells were identified. The uterine cervix, fallopian tubes, and ovaries were normal.

## DISCUSSION

The common causes of acute abdomen in cases of fibroid uterus include torsion of subserous fibroid, red degeneration, torsion of uterus along with the fibroid, and sarcomatous degeneration.<sup>[5]</sup> Large fibroids often degenerate as they outgrow their blood supply. The various types of degeneration include hyaline, myxoid, cystic, and red degeneration.<sup>[2]</sup> Red or carneous degeneration is occasionally seen in a fibroid, which develops most frequently during pregnancy.<sup>[6]</sup> Sudden

intraperitoneal hemorrhage in a case of fibroid uterus can also present as acute abdomen.<sup>[5]</sup> The bleeding is likely to occur from torn enlarged veins coursing over the surface of subserous leiomyomas, resulting in hemoperitoneum and hypovolemic shock.<sup>[4]</sup>

Ultrasound is often the initial diagnostic imaging modality for suspected complications of fibroids. A simple fibroid is usually seen as a hypoechoic lesion that may be well-defined and arising within the surrounding myometrium. Fibroids can also demonstrate posterior acoustic enhancement or attenuation without any calcification. Degeneration of fibroids gives a more complex ultrasound appearance with areas of cystic change and Doppler can show circumferential vascularity. Fibroids that are torsed or are necrotic will show absence of flow on Doppler ultrasound.<sup>[1]</sup> CT is not the primary modality for diagnosing or evaluating

fibroids; however, fibroids are often found incidentally at CT. Therefore, familiarity with their various CT appearances is important.<sup>[7]</sup> The typical finding is a bulky, irregular uterus, or a mass in continuity with the uterus. Degenerate fibroids may appear complex and contain areas of fluid attenuation.<sup>[1]</sup> Magnetic resonance imaging is highly accurate in evaluating leiomyoma size, number, location, and presence or extent of degeneration, but it requires a stable patient and may be difficult to perform in a timely fashion in the emergency department.<sup>[3]</sup>

Management is both surgical and supportive. Intravenous fluids and blood should be infused for significant blood loss and gynecology should be consulted immediately. The definitive treatment is surgical, requiring vessel repair and/or myomectomy.<sup>[3]</sup>

Alternative to surgery, percutaneous embolization of uterine artery has become established treatment for nonacute uterine hemorrhage. It is minimally invasive and also maintained patient's fertility. In addition, percutaneous embolization of internal iliac arteries branches has proven effectiveness in the emergency treatment of pelvic hemorrhage, resulting from trauma and other causes. It is also an effective treatment to control intractable uterine hemorrhage secondary to uterine fibroids.<sup>[8]</sup>

Our patient underwent total hysterectomy with bilateral salpingo-oophorectomy because of the increased risk of sarcomatous degeneration of the uterine fibroids at her age.

## CONCLUSION

Our case report illustrates the importance of CT in emergency setting to correctly diagnose uterine intraleiomyoma hemorrhage, perforation, and hemoperitoneum, which optimized the surgical approach and management.

## REFERENCES

1. Roche O, Chavan N, Aquilina J, Rockall A. Radiological appearances of gynaecological emergencies. *Insights Imaging* 2012;3:265-75.
2. Sue W, Scott-Barrett S. Radiological appearances of uterine fibroids. *Indian J Radiol Imaging* 2009;19:222-31.
3. Lotterman S. Massive hemoperitoneum resulting from spontaneous rupture of uterine leiomyoma. *Am J Emerg Med* 2008;26:974.e1-2.
4. Manopunya M, Tongprasert F, Sukpan K, Tongsong T. Intra-leiomyoma massive hemorrhage after delivery. *J Obstet Gynaecol Res* 2013;39:355-8.
5. Dasari P, Maurya DK. Hemoperitoneum associated with fibroid uterus. *J Obstet Gynecol India* 2005;55:553-4.
6. Kamat NV, Telkar HB, Ramani SK, Thakker AP. Ruptured degenerated uterine fibroid diagnosed by imaging. *Obstet Gynecol* 2001;98:961-3.
7. Bennett GL, Slywotzky CM, Giovanniello G. Gynecologic causes of acute pelvic pain: Spectrum of CT findings. *Radiographics* 2002;22:785-801.
8. Browne RF, McCann J, Johnston C, Molloy M, O'Connor H, McEniff N. Emergency selective arterial embolization for control of life-threatening hemorrhage from uterine fibroids. *AJR Am J Roentgenol* 2004;183:1025-8.

**Cite this article as:** Alharbi SR. Uterine leiomyoma with spontaneous intraleiomyoma hemorrhage, perforation, and hemoperitoneum in postmenopausal woman: Computed tomography diagnosis. *Avicenna J Med* 2013;3:81-3.

**Source of Support:** Nil, **Conflict of Interest:** None declared.

### Author Help: Reference checking facility

The manuscript system ([www.journalonweb.com](http://www.journalonweb.com)) allows the authors to check and verify the accuracy and style of references. The tool checks the references with PubMed as per a predefined style. Authors are encouraged to use this facility, before submitting articles to the journal.

- The style as well as bibliographic elements should be 100% accurate, to help get the references verified from the system. Even a single spelling error or addition of issue number/month of publication will lead to an error when verifying the reference.
- Example of a correct style  
Sheahan P, O'leary G, Lee G, Fitzgibbon J. Cystic cervical metastases: Incidence and diagnosis using fine needle aspiration biopsy. *Otolaryngol Head Neck Surg* 2002;127:294-8.
- Only the references from journals indexed in PubMed will be checked.
- Enter each reference in new line, without a serial number.
- Add up to a maximum of 15 references at a time.
- If the reference is correct for its bibliographic elements and punctuations, it will be shown as CORRECT and a link to the correct article in PubMed will be given.
- If any of the bibliographic elements are missing, incorrect or extra (such as issue number), it will be shown as INCORRECT and link to possible articles in PubMed will be given.