Article published online: 2021-08-09

CASE REPORT

Preoperative splenic artery embolization in klippel-Trenaunay syndrome with massive splenomegaly: A case report

Zishu Zhang, Narasimham L Dasika, Michael J Englesbe[1], Scott R Owens[2], Ranjith Vellody, Paula M Novelli, James J Shields

Departments of Radiology, Division of Interventional Radiology, [1]Surgery, [2]Pathology, University of Michigan Health System, Ann Arbor, Michigan, USA

Access this article online

Website: www.avicennajmed.com

DOI: 10.4103/2231-0770.130345

Quick Response Code:

ABSTRACT

The authors describe a case of Klippel-Trenaunay syndrome (KTS) with massive splenomegaly in a 29-year-old woman. Preoperative splenic artery embolization using the "double embolization technique" (a combination of distal selective splenic artery embolization and proximal splenic artery occlusion) facilitated open splenectomy.

Key words: Klippel-Trenaunay syndrome, spleen, splenic artery embolization

INTRODUCTION

Klippel-Trenaunay syndrome (KTS) is a congenital abnormality with combined malformation of the vascular and lymphatic systems.[1] KTS is characterized by the triad of varicose veins, bony and soft tissue hypertrophy, and cutaneous vascular malformations.[2] Rarely associated with KTS patients is visceral involvement with vascular malformations. In the spleen, vascular malformations with or without lymphatic malformations have been rarely observed.[3-5] We report a case of KTS with splenic vascular/lymphatic malformation involvement that was managed successfully by splenectomy following splenic artery embolization.

CASE REPORT

A 29-year-old woman with a history of KTS with vascular malformations involving both legs and pelvis was admitted to the hospital for open splenectomy. She had lymphedema of the lower extremities and cutaneous port-wine stains. Seven years prior to the admission, the patient had noncirrhotic portal hypertension of unknown etiology, complicated by portal vein thrombosis, and bleeding esophageal varices. Since then, she has undergone endoscopic variceal banding and percutaneous transhepatic portal vein recanalization with stent placement. Subsequently, she developed massive splenomegaly with thrombocytopenia and a 30-pound weight loss over six months. She had left-sided abdominal pain associated with massive splenomegaly.

Hematocrit was 25.3%, hemoglobin 8.5 g/dL, and platelet count 38,000/mm^3. Computed tomography (CT) of the abdomen demonstrated massive splenomegaly with innumerable, less than 1 cm, low attenuation lesions in the spleen. Magnetic resonance imaging (MRI) of the abdomen depicted a markedly enlarged spleen with similar innumerable abnormal signal structures within the spleen [Figure 1]. Splenomegaly and splenic involvement of KTS were delineated on both CT and MRI images. Because of the risk of bleeding, the patient underwent transcatheter splenic artery embolization, immediately prior to open splenectomy.

After obtaining written informed consent, the procedure was performed on the morning of surgery. Digital subtraction angiogram of celiac trunk demonstrated a dilated and tortuous splenic artery, and an enlarged spleen with inhomogeneous parenchymal staining. Innumerable

Address for correspondence: Dr. Zishu Zhang, Department of Radiology, Division of Interventional Radiology, University of Michigan Health System, Ann Arbor, Michigan, USA. E-mail: zishuzhang@hotmail.com

avascular lesions were seen in the splenic parenchymal phase. There was no arteriovenous shunting [Figure 2]. After placing a catheter distal to the origins of the caudal pancreatic and left gastroepiploic arteries, distal splenic artery embolization was performed using Gelfoam slurry (Ferrosan, Somerville, NJ), achieving occlusion of the segmental arteries. The proximal splenic artery (immediately distal to its origin at the celiac axis), measuring 8 mm in diameter was occluded using a 14 mm diameter Amplatzer Vascular Plug II (AVP II; St. Jude Medical Inc. St. Paul, MN). Follow-up arteriography confirmed optimal deployment of AVP II in splenic artery. No persistent flow, through the deployed AVP II was demonstrated on the completion celiac digital subtraction angiography (DSA) [Figure 3]. Selective left gastric arteriography demonstrated no evidence of collateral blood flow to the spleen.

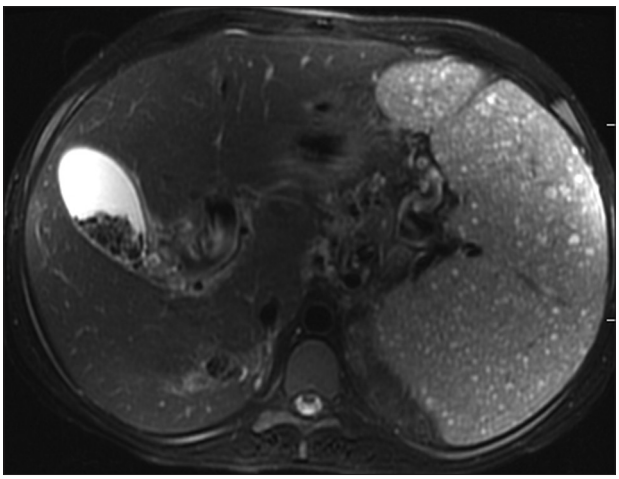

Figure 1: Magnetic resonance imaging T2-weighted image shows high signal intensity lesions in massively enlarged spleen. Gall stones are noted in gallbladder

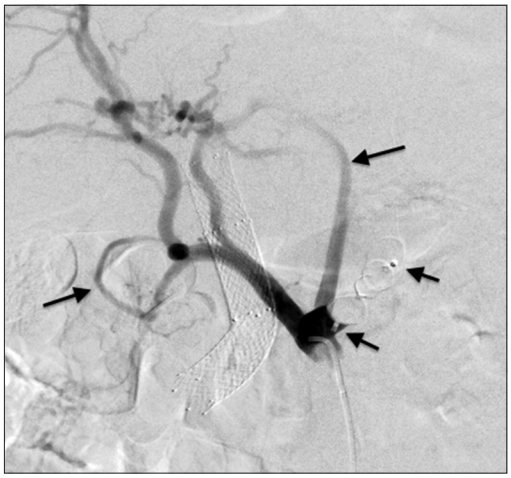

Figure 3: Completion celiac arteriogram after distal and proximal splenic artery embolization (arterial phase). The splenic artery is occluded, immediately after its origin (arrows). The left gastric and common hepatic arteries are filled. No reconstitution vessels feeding the spleen from right and left gastric arteries (long arrows)

After splenic artery embolization, the patient was transferred to the operating room for open splenectomy. After careful dissection, the spleen was isolated on its hilum. The spleen was soft, secondary to the prior splenic artery embolization. Surgical ligation of the splenic artery before dissection for surgical exposure was not necessary due to prior embolization. The estimated blood loss was 100 cc during surgical splenectomy. The patient received pneumococcal and hemophilus vaccines, immediately after surgery.

On pathology examinations, the removed spleen measured 27.5 × 21 × 6.5 cm in size and weighed 2,935 g [Figure 4]. Grossly, the spleen was diffusely enlarged without any discrete lesions. Large quantities of blood exuded from its cut surfaces. Histologically, the spleen had mixed arteriovenous and lymphatic components [Figure 5]. Thrombocytopenia was successfully corrected after splenectomy with platelet count of 160,000/mm^3 on postoperative day 5. Postoperative

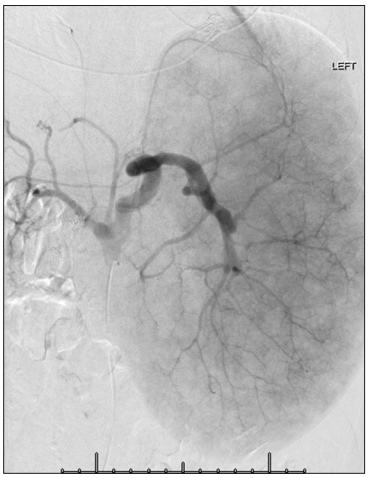

Figure 2: Digital subtraction celiac arteriography (late arterial phase) shows tortuous, dilated splenic artery with massive splenomegaly. Heterogeneous parenchymal staining with innumerable avascular lesions are noted

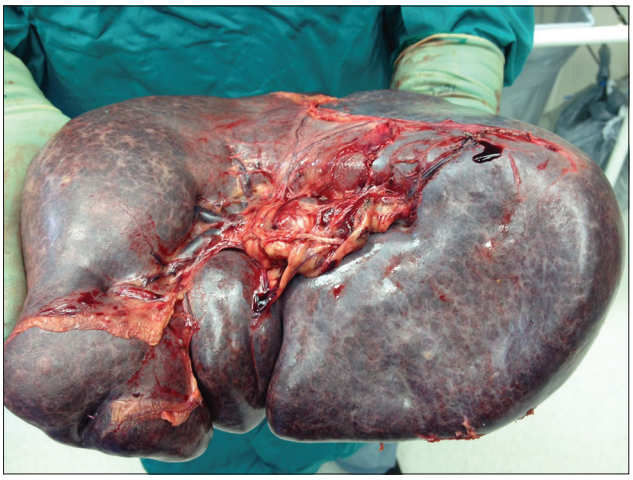

Figure 4: Photograph of the resected spleen. The spleen measured 27 × 21 × 6.5 cm and weighed 2.9 kg

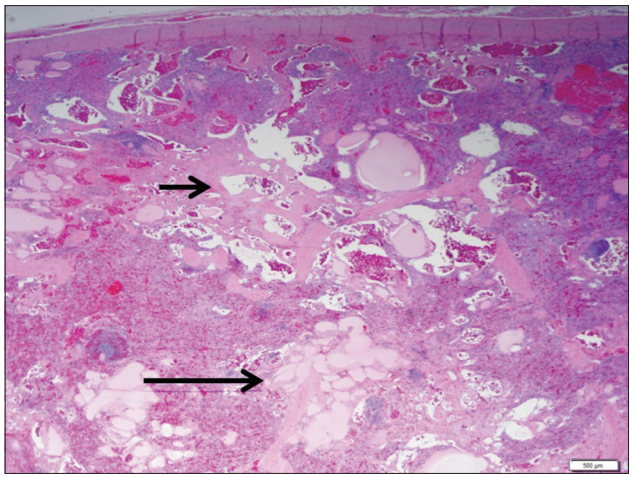

Figure 5: Photomicrograph of the resected spleen. The splenic parenchyma is replaced largely by a tangled collection of blood and lymphatic vessels. Only a small amount of intact red and white pulp is visible. A collection of thick-walled interconnecting arteries and veins are visible in the middle of the photomicrograph (short arrow); and a knot of thin-walled lymphatic channels filled with lightly pink lymph fluid is seen near the bottom (long arrow) (H and E 20×, magnification)

recovery was smooth without complications. Patient was discharged 5 days after the surgery. The patient was closely followed by the surgical and hematological services. During 6 months after the surgery, abdominal pain has improved with weaning off narcotics. The platelet count of 184,000/mm^3 was also noted at her 6-month follow-up visit.

DISCUSSION

Two factors could be contributory to the etiology of massive splenomegaly in our patient. First is the history of noncirrhotic portal hypertension and the other is the intrasplenic involvement of vascular malformation. Thrombocytopenia, in the context of KTS is due to Kasabach-Merritt syndrome secondary to the peripheral vascular malformations. Due to the avascular nature of intrasplenic KTS involvement on DSA, the KTS lesions are unlikely the causes of sequestration and platelet consumption. Thus, the underline reason of thrombocytopenia, in this patient, is likely due to portal hypertension related splenomegaly. Splenic embolization is not routinely advocated for thrombocytopenia in splenic involvement with KTS, unless other potential causes of consumptive coagulopathy are ruled out. The indications of surgical splenectomy for our patient were: Portal hypertension with a history of recurrent variceal bleeding, refractory thrombocytopenia, symptomatic massive splenomegaly, and the imaging demonstration of coincident splenic involvement of KTS, with noncirrhotic portal hypertension related splenomegaly.

Embolization is a well-established technique to treat hypersplenism and for preoperative reduction of blood loss.[6,7] Surgical splenectomy for massive splenomegaly (i.e., >1,000 g, >20 cm long) has a higher incidence of intraoperative bleeding because of technical challenges and problems of hemostasis.[8] The present case demonstrated the benefits of the combined distal and proximal splenic artery embolization, prior to open splenectomy for the following reasons: First, the vast majority of bleeding during splenectomy occurs from venous collaterals associated with splenomegaly. This bleeding can be copious and life threatening. Furthermore, the splenic vein course posterior to the pancreas, making it technically difficult to manage the intraoperative venous bleeding. The distal embolization significantly decreases the venous outflow of the spleen, thus decreasing the risk of intraoperative venous bleeding. Second, access to the splenic artery for surgical ligation can be difficult and treacherous, especially in patients with massive splenomegaly; if the spleen has been embolized, this step is not needed.[9] Proximal splenic artery embolization blocks the splenic artery inflow to the spleen, thus, decreases the risk of intraoperative arterial bleeding. Third, the risk of parenchymal bleeding during surgical dissection may be increased due to the size of the spleen and intrasplenic vascular malformation involvement. This "double embolization" decreases both the splenic artery perfusion pressure and the intrasplenic blood reservoir; thus, decreases the risk of parenchymal bleeding. Finally, preoperative splenic artery embolization allows correction of thrombocytopenia prior to surgery. This will further decrease the risk of intraoperative bleeding.

Splenic involvement in KTS patients should alert us to diligently search for the presence of vascular abnormalities in other visceral organs.[10] Furthermore, the existence of arteriovenous fistula as part of vascular malformation in the spleen should always be a serious concern during pre-embolization diagnostic arteriography.[11] Care must be taken to avoid non-target embolization of the pulmonary artery through the arteriovenous fistula. "Double embolization" is recommended for patients with significant splenomegaly and the intrasplenic vascular malformation involvement. Timing for surgery is important following preoperative splenic artery embolization. Post-embolization syndrome does not happen if surgery is performed immediately after embolization like in this case.

REFERENCES

1. Klippel MT. The nevus variqueux osteo-hypertrophique. Arch Gen Med Paris 1900;3:640-50.
2. Servelle M. Klippel and Trenaunay's syndrome. 768 operated cases. Ann Surg 1985;201:365-73.
3. Spasic M, Radovanovic D, Canovic D, Azanjac G, Djurdjevic P, Mitrovic S. Combined lymphangioma and hemangioma of the spleen in a patient with Klippel-Trenaunay syndrome. Srp Arh Celok Lek 2012;140:777-81.

4. Jindal R, Sullivan R, Rodda B, Arun D, Hamady M, Cheshire NJ. Splenic malformation in a patient with Klippel-Trenaunay syndrome: A case report. J Vasc Surg 2006;43:848-50.
5. Lin CC, Chen YS, Lin KJ, Chen W, Chen HC. Klippel-Trenaunay syndrome complicated with splenomegaly. Am Surg 2011;77:E240-1.
6. Gaba RC, Katz JR, Parvinian A, Reich S, Omene BO, Yap FY, *et al*. Splenic artery embolization: A single center experience on the safety, efficacy, and clinical outcomes. Diagn Interv Radiol 2013;19:49-55.
7. Thacker PG, Friese JL, Loe M, Biegler P, Larson M, Andrews J. Embolization of nonliver visceral tumors. Semin Intervent Radiol 2009;26:262-9.
8. Sharp P, Grace CS, Rozenberg MC, Ham JM. Splenectomy for massive splenomegaly. Aust N Z J Surg 1985;55:489-92.
9. Raikhlin A, Baerlocher MO, Asch MR, Myers A. Imaging and transcatheter arterial embolization for traumatic splenic injuries: Review of the literature. Can J Surg 2008;51:464-72.
10. Kuo PH, Chang YC, Liou JH, Lee JM. Mediastinal cavernous hemangioma in a patient with Klippel-Trenaunay syndrome. Thorax 2003;58:183-4.
11. Weber FP. Angioma formation in connection with hypertrophy of limbs and hemi-hypertrophy. Br J Dermatol 1907;19:231-5.

Cite this article as: Zhang Z, Dasika NL, Englesbe MJ, Owens SR, Vellody R, Novelli PM, *et al*. Preoperative splenic artery embolization in klippel-Trenaunay syndrome with massive splenomegaly: A case report. Avicenna J Med 2014;4:40-3.

Source of Support: Nil, **Conflict of Interest:** None declared.

Author Help: Online submission of the manuscripts

Articles can be submitted online from http://www.journalonweb.com. For online submission, the articles should be prepared in two files (first page file and article file). Images should be submitted separately.

1) **First Page File:**
Prepare the title page, covering letter, acknowledgement etc. using a word processor program. All information related to your identity should be included here. Use text/rtf/doc/pdf files. Do not zip the files.
2) **Article File:**
The main text of the article, beginning with the Abstract to References (including tables) should be in this file. Do not include any information (such as acknowledgement, your names in page headers etc.) in this file. Use text/rtf/doc/pdf files. Do not zip the files. Limit the file size to 1024 kb. Do not incorporate images in the file. If file size is large, graphs can be submitted separately as images, without their being incorporated in the article file. This will reduce the size of the file.
3) **Images:**
Submit good quality color images. Each image should be less than **4096 kb (4 MB)** in size. The size of the image can be reduced by decreasing the actual height and width of the images (keep up to about 6 inches and up to about 1800 x 1200 pixels). JPEG is the most suitable file format. The image quality should be good enough to judge the scientific value of the image. For the purpose of printing, always retain a good quality, high resolution image. This high resolution image should be sent to the editorial office at the time of sending a revised article.
4) **Legends:**
Legends for the figures/images should be included at the end of the article file.