Article published online: 2021-08-09

CASE REPORT

A rare case of coronary artery fistula presented with acute myocardial infarction

Osama Abdalhadi Smettei, Rami Mahmood Abazid

Advanced Cardiac Imaging Prince Sultan Cardiac Centre, Qassim, Saudi Arabia

Access this article online

Website: www.avicennajmed.com

DOI: 10.4103/2231-0770.154200

Quick Response Code:

ABSTRACT

Coronary artery fistulas (CAFs): Are anomalous connections of the coronary arteries (CA) with major vascular structures or heart chambers. Most of CAFs are incidental findings during invasive coronary angiography (ICA) or computed tomography angiography (CTA). Many patients with CAFs are asymptomatic; only a minority has been associated with various clinical features and outcomes. We have reported a rare CAF complicated with acute myocardial infarction (AMI) in 43 years old female Patient who was admitted to our institution with a Diagnosis of Acute Infero-Posterior Myocardial Infarction (AMI). ICA and CTA showed a thrombosed CAF between left main coronary artery and right atrium with totally occluded left circumflex artery by a thrombus extended from the fistula. As there was a high risk associated with immediate intervention, the patient was kept on conservative management with a future plan of catheter-assisted or surgical closure. We have shown a rare case of CAF presenting with AMI that is unusual for such an anomaly, and have highlighted the role of CTA in the diagnosis and management of such rare disorder.

Key words: Acute myocardial infarction, computed tomography angiography, coronary anomalies, coronary artery fistula

INTRODUCTION

Coronary artery fistulas (CAFs) are rare anomalies of the coronary arteries (CAs), characterized by normal aortic origin of the involved (CA), but with a fistulous communication of CA with the atria, ventricles or with the pulmonary artery (PA), coronary sinus or superior vena cava. The number of incidental findings of CAF has been increased with the use of computed tomography angiography (CTA). Correct and early diagnosis and management of this rare disorder are important to avoid later complications, morbidity, and mortality.

CASE REPORT

A 43-year-old female patient, not known to have any past medical illnesses, was taken through the Emergency Department with a 6-h history of retrosternal chest pain, compressive in nature, radiating to the left arm and back, with associated sweating and vomiting. Electrocardiogram (ECG) [Figure 1] showed ST elevation in inferior leads with reciprocal ST depression in leads I, AVL, V1–V6, and with prominent R waves in leads V1–V2. Diagnosis of acute infero-posterior MI was made and the patient was taken for primary percutaneous coronary intervention that showed dilated left main coronary artery (LMCA) with an aneurysm-like structure rising from its distal portion with no clear termination. Left circumflex coronary artery (LCX) was totally occluded from the ostium [Figure 2a and b]. Owing to its complex anatomy, invasive angiography did not clearly define the distal course and drainage of the CAF. The patient underwent CTA to delineate the course and anatomy of it. CTA showed: Aneurysmal left main (LM) with a diameter of 11 mm, CAF between distal LM and right atrium (RA) which was thrombosed with some faint filling of contrast. Wing of the thrombus into LCX had occluded its ostium with multiple thromboses and in the middle and distal parts as well. The

Address for correspondence: Dr. Osama Smettei, Saudi Arabia Qassim King Fahad Specialist Hospital P. O. Box 2290, Burhydah-Saudi Arabia. E-mail: Drossama1971@yahoo.com

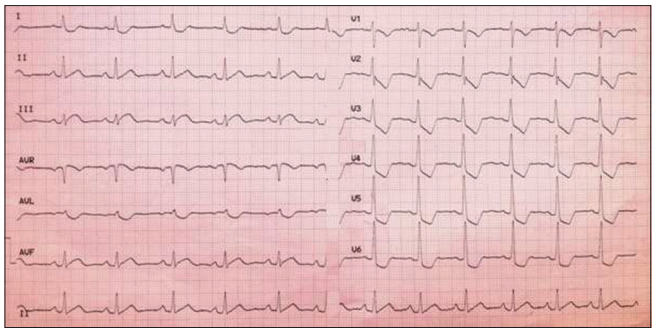

Figure 1: Twelve leads electrocardiogram showed ST elevation in II, III, AVF, with a tall R wave and ST depression in pericardial leads suggesting acute inferior posterior MI

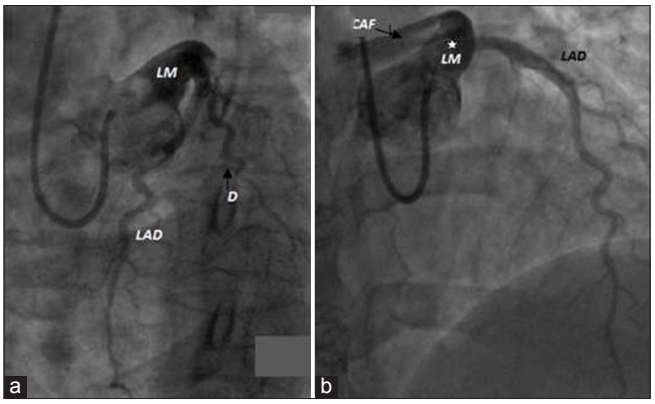

Figure 2: Coronary angiography (a) left anterior oblique view, aneurismal left main (LM), left circumflex coronary artery is not visible. (b) Aneurismal LM (star), fistula-like structure rising from distal LM coronary artery with no clear termination (black arrow)

rest of the CAs were normal [Figure 3a-d]. As the chest pain did not recur, and there was a high risk for intervention. The patient was kept on antithrombotic, antiplatelet, glycoprotein IIb/IIIa inhibitors and anti-ischemic medications. With prompt recognition of the disease and early suitable treatment, the patient was stabilized within 24 h and became asymptomatic. ECG changes resolved over time**.** After 5 days, the patient was discharged and kept on dual antiplatelet therapy (aspirin and clopidogrel) in addition to anti ischemic medications. Follow-up was scheduled after 3 months with repeat CTA to evaluate the management options (surgical or catheter based closure of the fistula). Three months later, CTA was repeated and showed decreases in the thrombus size, but the fistula was not fully patent [Figure 3e], LCX was occluded at its ostium with retrograde filling. Surgical closure of the CAF was planned because of the proximal location, aneurismal dilation of the LMCA and the persisting thromboses to avoid the risk of future cardiac events and extension of the thrombus to the CAs, but the patients preferred to continue on medical treatment for future follow-up, the future risk was explained to the patient with possible extension of the thrombus to the adjacent arteries (including the LM and left anterior descending coronary artery) with its catastrophic outcomes (MI, sudden death), but the patient selected to avoid surgery at present.

DISCUSSION

Coronary artery fistulas is a direct pre-capillary connection between a branch of CA and other vascular structure or a heart chamber.[1,2] This disorder accounts for approximately 0.2–0.4% of congenital cardiac anomalies. CAFs have an estimated prevalence of 0.002% in the general population and 0.05–0.25% in patients who undergo invasive coronary angiography (ICA).[3] Fistula arises from the right coronary artery (RCA) in close to 50% of patients, the left coronary artery (LCA) in about 42% of patients, and both the RCA and LCA in approximately 5% of patients.[4] There is no race or gender predilection. More than 90% of the fistulas drain into the venous circulation. The majority of adult patients are asymptomatic. Majority of the symptomatic CAFs originate from the RCA.[5] The clinical presentation of CAFs mainly Depends on the severity of the left-to-right shunt. If symptoms develop, dyspnea and right ventricular enlargement or dysfunction can be the presenting symptoms. Other clinical features include fatigue, orthopnea, chest pain, endocarditis, arrhythmia's, stroke, myocardial ischemia and MI. ICA is usually useful to evaluate the fistula's clinical significance. The cardiac CT and MRA on the other hand, is being progressively used to assess those patients, as it can better illustrate the fistula's three-dimensional structure and offer a fuller apprehension of it, as shown in this patient. The natural history of CAFs is variable. Spontaneous closure secondary to thrombosis has been described.[6] Antiplatelets therapy is recommended, particularly in patients with distal CAF and abnormally dilated CAs.[7] Although some authors suggest surgical closure or coil embolization even in asymptomatic patients, this is not a widely recommended strategy, as most patients can adequately be managed conservative unless a significant volume overload is present. The main indications for closure are the clinical manifestations like heart failure and myocardial ischemia and in asymptomatic patients with high-flow shunting to prevent the occurrence of symptoms or complications.[8] Transcatheter embolization techniques using coils, bags, or other devices can be performed at the time of diagnostic studies or later, and may obviate the need for cardiac surgical intervention.[9] Results from trans-catheter embolization and surgical ligation show that both approaches have similar early effectiveness, morbidity, and mortality.[10] The main indications for emobilization are the proximal location of the fistulous vessel, single drain site, extra-anatomic

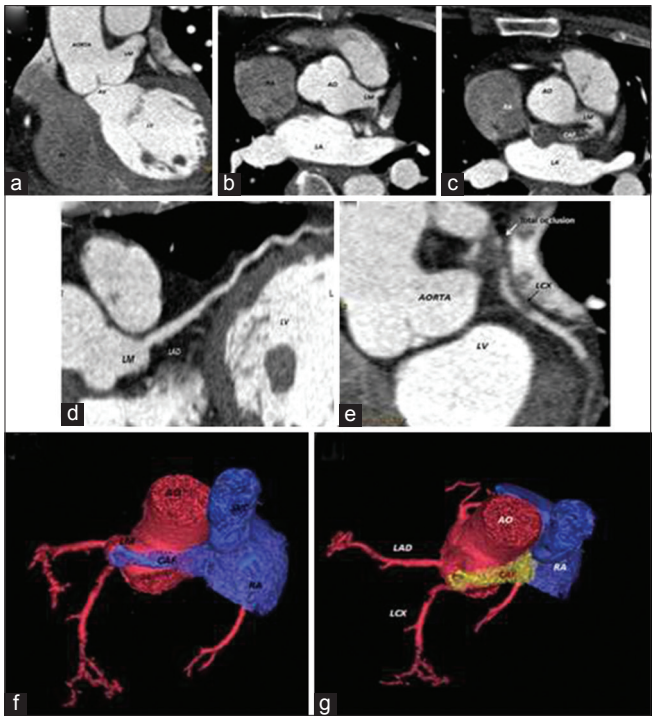

Figure 3: Computed tomography coronary angiography. (a) Maximum intensity projection (MIP), showing the aneurismal dilatation of the left main (LM) coronary artery. (b) MIP image at the level of LM coronary artery and the ostium of LAD and left circumflex coronary artery (LCX) showing aneurismal dilatation of LM and occluded LCX from its ostium. (c) multi planner reformation (MPR) image, note the thrombosed fistula between LM and right atrium (RA). (d) MPR image, showing normal left anterior descending artery. (e) MPR image, note the occluded LCX artery at the ostium (arrow) by thrombus, mid and distal thromboses. (f and g) volume rendering images showing the three dimensional orientation of the anatomy and the course of the fistula and its connections to LM and RA

termination of the fistula away from the normal coronary arteries, older patient age and absence of concomitant cardiac disorders requiring surgical intervention.[11,12] To date, the literature has primarily provided only case reports and reports of small series. Results have been comparable to surgery without associated morbidities of cardiopulmonary bypass and/or sternotomy. Indications for surgery include a large CAF characterized by the high fistula flow, multiple communications, very tortuous pathways, multiple terminations, significant aneurysmal formation, need for simultaneous distal bypass or the presence of large vascular branches that can be accidentally embolized.[11,12,13] After closure of the CAF, Patients remain at risk for developing endocarditis until the flow is totally abolished. Therefore, they should receive antibiotic prophylaxis for the procedures that require infective endocarditis prophylaxis.[14]

CONCLUSION

This case is showing a rare CAF complicated by thrombosis extending into one of the main coronary vessels causing an AMI. The aim of this case report is also to stress upon the role of CTA in diagnosis and management plan when such cases present a clinical challenge.

REFERENCES

1. Yildiz A, Okcun B, Peker T, Arslan C, Olcay A, Bulent Vatan M. Prevalence of coronary artery anomalies in 12,457 adult patients who underwent coronary angiography. Clin Cardiol 2010;33:E60-4.
2. Schumacher G, Roithmaier A, Lorenz HP, Meisner H, Sauer U, Müller KD, *et al.* Congenital coronary artery fistula in infancy and childhood: Diagnostic and therapeutic aspects. Thorac Cardiovasc Surg 1997;45:287-94.
3. Pelech AN. Coronary Artery Fistula. Available from: http://www.emedicine.com/ped/topic2505.htm. [Last accessed on 2008 Mar 21].
4. Nakamura M, Matsuoka H, Kawakami H, Komatsu J, Itou T, Higashino H, *et al.* Giant congenital coronary artery fistula to left brachial vein clearly detected by multidetector computed tomography. Circ J 2006;70:796-9.
5. Sherwood MC, Rockenmacher S, Colan SD, Geva T. Prognostic significance of clinically silent coronary artery fistulas. Am J Cardiol 1999;83:407-11.
6. Sapin P, Frantz E, Jain A, Nichols TC, Dehmer GJ. Coronary artery fistula: An abnormality affecting all age groups. Medicine (Baltimore) 1990;69:101-13.
7. Umaña E, Massey CV, Painter JA. Myocardial ischemia secondary to a large coronary-pulmonary fistula – A case report. Angiology 2002;53:353-7.
8. Balanescu S, Sangiorgi G, Castelvecchio S, Medda M, Inglese L. Coronary artery fistulas: Clinical consequences and methods of closure. A literature review. Ital Heart J 2001;2:669-76.
9. McMahon CJ, Nihill MR, Kovalchin JP, Mullins CE, Grifka RG. Coronary artery fistula. Management and intermediate-term outcome after transcatheter coil occlusion. Tex Heart Inst J 2001;28:21-5.
10. Gowda RM, Vasavada BC, Khan IA. Coronary artery fistulas: Clinical and therapeutic considerations. Int J Cardiol 2006;107:7-10.
11. Jung C, Jorns C, Huhta J. Doppler findings in a rare coronary artery fistula. Cardiovasc Ultrasound 2007;5:10.
12. Mavroudis C, Backer CL, Rocchini AP, Muster AJ, Gevitz M. Coronary artery fistulas in infants and children: A surgical review and discussion of coil embolization. Ann Thorac Surg 1997;63:1235-42.
13. Said SA, van der Werf T. Dutch survey of coronary artery fistulas in adults: Congenital solitary fistulas. Int J Cardiol 2006;106:323-32.
14. Said SA, Lam J, van der Werf T. Solitary coronary artery fistulas: A congenital anomaly in children and adults. A contemporary review. Congenit Heart Dis 2006;1:63-76.

Cite this article as: Smettei OA, Abazid RM. A rare case of coronary artery fistula presented with acute myocardial infarction. Avicenna J Med 2015;5:49-51.

Source of Support: Nil, **Conflict of Interest:** None declared.