Article published online: 2021-08-09

CASE REPORT

Esophageal stent placement as a therapeutic option for iatrogenic esophageal perforation in children

Alsafadi Ahmad, Louis M. Wong Kee Song[1], Imad Absah

Pediatrics and Adult Gastroenterology and Hepatology, [1]Division of Gastroenterology and Hepatology, Mayo Clinic, Rochester, MN, USA

Access this article online

Website: www.avicennajmed.com

DOI: 10.4103/2231-0770.179552

Quick Response Code:

ABSTRACT

Iatrogenic esophageal perforation (IEP) is a potentially serious adverse event of interventional endoscopy. The approach to IEP varies from surgical repair for large perforations to conservative treatment for small contained perforations. We report a case of an 18-month-old girl with congenital esophageal stenosis suffering a large esophageal perforation after a trial of stricture dilatation, which was successfully managed by the placement of fully covered stent. Hence, in selected cases, esophageal stent placement is a feasible alternative to invasive surgery in managing IEP.

Key words: Esophageal perforation, esophageal stent, esophageal stricture

INTRODUCTION

Congenital esophageal stenosis (CES) is an uncommon malformation with an approximate incidence of 1 in 25,000–50,000 live births.[1] CES is divided histologically into three main types: (1) Membranous stenosis (MS), (2) fibromuscular stenosis (FMS), and (3) tracheobronchial remnant stenosis (TBR).[2] Early identification of the stenosis type by computed tomography (CT) or magnetic resonance imaging is of high importance, as it determines the line of management. TBR is an embryological malformation that requires surgical intervention, unlike MS and FMS, which respond well to periodic endoscopic dilatations.[3] Patients undergoing repeated esophageal dilatations are prone to developing adverse events, such as perforation. Several factors may predispose to perforation, including complexity and degree of inflammation associated with the stricture. In addition, blind esophageal dilatation using Maloney bougies is associated with higher rates of iatrogenic esophageal perforation (IEP), compared to the use of through-the-scope (TTS) or wire-guided polyvinyl savary dilators.[4,5] IEP is a serious condition that may result in mediastinitis, sepsis, and death, if not diagnosed early and managed promptly. The decision to manage conservatively or intervene surgically is determined by several factors, including size and site of the perforation, delay in diagnosis, extent of mediastinal involvement/contamination, and clinical stability of the patient. Conservative management includes nil per os (NPO), broad-spectrum intravenous (IV) antibiotics, and close monitoring for any signs of mediastinitis with or without endotherapy, such as endoscopic suturing, clip closure, and/or stent placement. The basic surgical approach by primary suturing of perforation is preferred by many as the first line of treatment, however, for immediately recognized large perforations.

The use of stents for the management of esophageal perforation is a relatively common practice in selected cases among adult patients. However, the use of stents in the pediatric population has been limited to refractory esophageal strictures, tracheoesophageal fistulas, postoperative leaks, and rare malignant conditions.

Address for correspondence: Dr. Ahmad Alsafadi, 200 First Street SW, Rochester, MN, 55905, USA.
E-mail: alsafadi.ahmad@mayo.edu

Cite this article as: Ahmad A, Wong Kee Song LM, Absah I. Esophageal stent placement as a therapeutic option for iatrogenic esophageal perforation in children. Avicenna J Med 2016;6:51-3.

CASE REPORT

A 1-year-old Caucasian girl initially presented with gagging and coughing following ingestion of solid food. Although she tolerated breast feeding and infant cereal well, her symptoms started with the introduction of solid food at 9 months of age. She was kept on a liquid diet, and a trial of a proton pump inhibitor failed to relieve her symptoms. A contrast study via feeding tube suggested normal esophageal anatomy, and a swallow study was also interpreted as normal. However, an esophagogastroduodenoscopy showed external compression and a benign-appearing esophageal stricture in the middle third of the esophagus measuring 10 mm in length and 6 mm in diameter. A subsequent chest CT revealed an aberrant right subclavian artery causing external compression and excluded TBR as the cause of the esophageal stricture.

A decision was made to proceed with stricture dilatation and to consider surgical intervention on both the aberrant vessel and stricture, only if she remained symptomatic despite stricture dilatation. The patient's symptoms were responsive to stricture dilatation using TTS balloon dilators. However, she required multiple balloon dilations over several weeks due to the fact that her stricture was refractory to TTS dilatation beyond 10 mm, with rapid relapse of symptoms within a week of dilatation.

A trial of esophageal dilation beyond 10 mm using wire-guided polyvinyl Savary dilators was complicated by an IEP measuring 1 cm × 3 cm [Figure 1]. She remained stable during the procedure, and an on-table chest X-ray showed no evidence of pneumomediastinum. This iatrogenic perforation was managed immediately by the placement of a fully covered 16 mm wide × 70 mm long self-expandable metal stent (Alimaxx, Merit Medical Endotek, South Jordan, UT) [Figure 2]. The stent was anchored in place using a TTS clip and fluoroscopic contrast injection, post-stent placement confirmed proper stent positioning and adequate sealing of the perforation site without contrast extravasation [Figure 3]. A nasogastric (NG) tube was placed through the stent. The patient was admitted for observation, kept NPO, and started on IV antibiotics. She remained stable, and a repeat esophagram at 24 h excluded any leakage. Her NG tube was removed, and a clear liquid diet was initiated. Although the plan was to maintain the stent in place for 2 weeks, the patient presented 10 days later with vomiting and decreased oral intake. A chest X-ray was clear and showed the stent in good position in the mid esophagus and excluded stent migration. Since her symptoms were possibly related to the indwelling stent, the stent was removed under endoscopic visualization using a TTS snare. Complete healing of the perforation and resolution of the esophageal stricture were noted endoscopically following stent removal [Figure 4]. The patient was seen for follow-up visit 3 months later tolerating regular solid food without dysphagia.

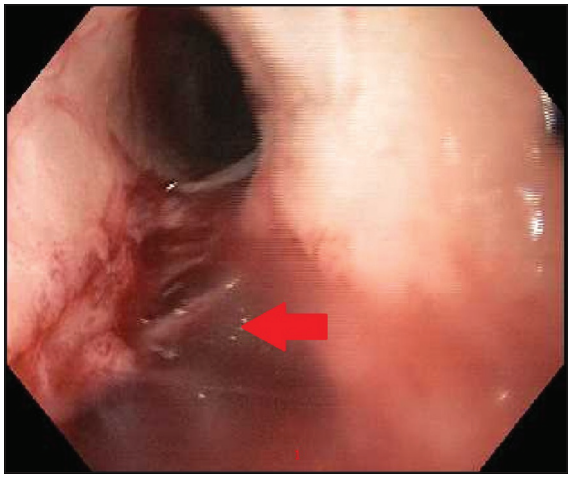

Figure 1: Large iatrogenic (dilation-induced) esophageal perforation

Figure 2: Stent in place with sealing of the perforation site

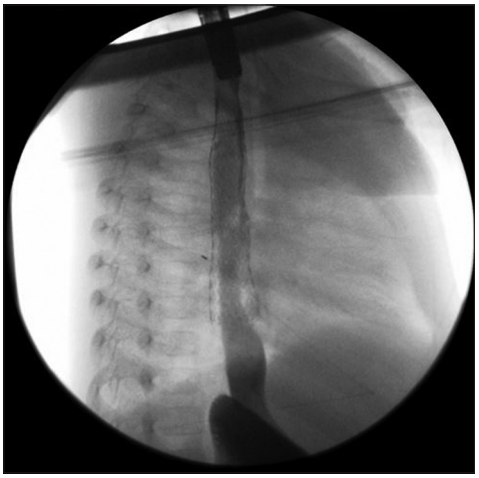

Figure 3: Successful sealing of perforation with absence of contrast extravasation following stent placement

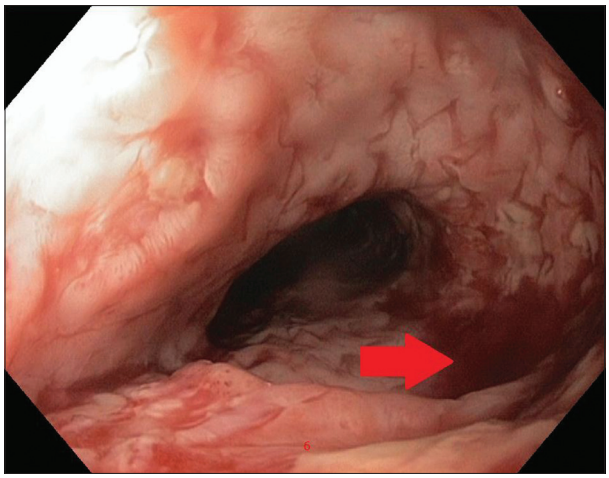

Figure 4: Complete healing of perforation site following stent removal

DISCUSSION

The goal in managing esophageal perforation is to minimize extra luminal contamination and restore luminal integrity as soon as possible. Therefore, early detection and management of iatrogenic perforations are key determinants for a successful outcome. Herein, we report an 18-month-old girl with a large 3 cm IEP, which was managed successfully by temporary placement of a fully covered esophageal stent.

Although the use of stents in managing CES has been reported, to our knowledge, only one case documented a similar concept in managing perforations, where a fully covered airway self-expandable plastic stent (airway polyflex stent) was used successfully to seal IEP of an anastomotic stricture.[6] Surgery has been the standard approach in the majority of large IEP cases regardless of clinical stability. Based on the location of the perforation site, a thoracotomy or laparotomy is the route taken for primary repair or esophagectomy. Both approaches are highly invasive procedures that carry serious risks, in addition to a long recovery period. Esophagectomy is usually indicated in case primary repair fails. An end-to-end anastomosis with gastric pull up or esophageal replacement by colon graft implies life style adjustments and potentially lifelong complications.

In select cases, we surmise that esophageal stent placement is a potential alternative to invasive surgical options for the management of large IEP. The optimal stent dwell time is unknown, but complete healing of IEP can occur as early as 10 days following stent placement as evidenced by our case. The use of esophageal stents does imply a set of possible complications such as stent migration, hemorrhage, and food impaction as well as developing postremoval strictures. In addition, reactive tissue overgrowth and stent embedding may result in removal complications and possible perforation.[7] Although TTS clips may be suitable for small iatrogenic linear perforations, they may not provide secure closure for larger, gaping perforations. Newer closure devices, such as endoscopic suturing (OverStitch, Apollo Endosurgery, Inc., Austin, TX, USA) and over-the-scope clips (OTSC, Ovesco, Inc., Tubingen, Germany), are useful tools for closing large perforations in the adult esophagus but are not suitable for use in the esophagi of small children.

Financial support and sponsorship

Nil.

Conflicts of interest

There are no conflicts of interest.

REFERENCES

1. Murphy SG, Yazbeck S, Russo P. Isolated congenital esophageal stenosis. J Pediatr Surg 1995;30:1238-41.
2. Ramesh JC, Ramanujam TM, Jayaram G. Congenital esophageal stenosis: Report of three cases, literature review, and a proposed classification. Pediatr Surg Int 2001;17:188-92.
3. Michaud L, Coutenier F, Podevin G, Bonnard A, Becmeur F, Khen-Dunlop N, *et al*. Characteristics and management of congenital esophageal stenosis: Findings from a multicenter study. Orphanet J Rare Dis 2013;8:186.
4. Hernandez LV, Jacobson JW, Harris MS. Comparison among the perforation rates of Maloney, balloon, and savary dilation of esophageal strictures. Gastrointest Endosc 2000;51(4 Pt 1):460-2.
5. Romeo E, Foschia F, de Angelis P, Caldaro T, Federici di Abriola G, Gambitta R, *et al*. Endoscopic management of congenital esophageal stenosis. J Pediatr Surg 2011;46:838-41.
6. Rico FR, Panzer AM, Kooros K, Rossi TM, Pegoli W Jr. Use of polyflex airway stent in the treatment of perforated esophageal stricture in an infant: A case report. J Pediatr Surg 2007;42:E5-8.
7. van Boeckel PG, Dua KS, Weusten BL, Schmits RJ, Surapaneni N, Timmer R, *et al*. Fully covered self-expandable metal stents (SEMS), partially covered SEMS and self-expandable plastic stents for the treatment of benign esophageal ruptures and anastomotic leaks. BMC Gastroenterol 2012;12:19.