

## CASE REPORT

# Bleeding Meckel's diverticulum diagnosed and treated by double-balloon enteroscopy

Snorri Olafsson, Julie T. Yang<sup>1</sup>, Christian S. Jackson<sup>2</sup>, Mohamad Barakat, Simon Lo<sup>3</sup>

Department of Internal Medicine/Gastroenterology, Loma Linda University Medical Center, Loma Linda, CA, <sup>1</sup>Alliance Digestive Disease Consultants, Pasadena CA 91105, <sup>2</sup>VA Loma Linda Healthcare System, Loma Linda, CA, <sup>3</sup>Digestive Diseases Center, Cedars-Sinai Medical Center, Los Angeles, CA. Pioneers Memorial hospital, CA

## Access this article online

Website: [www.avicennajmed.com](http://www.avicennajmed.com)

DOI: 10.4103/2231-0770.99166

## Quick Response Code:



## ABSTRACT

Meckel's diverticulum (MD) is the most common congenital anomaly of the gastrointestinal (GI) tract. The diagnosis of symptomatic MD has been cumbersome. Several case reports been published regarding direct visualization of MD with double balloon enteroscopy (DBE); diagnosing a bleeding MD leading to surgical resection. We report the use of DBE for the treatment of a bleeding MD.

**Key words:** Balloon, bleeding, double, endoscopy, Meckel's

## INTRODUCTION

Meckel's diverticulum (MD) is the most common congenital anomaly of the gastrointestinal (GI) tract.<sup>[1]</sup> It occurs in about two percent of the population and two to six percent of the patients develop complications.<sup>[2]</sup> Prior to the development of video capsule endoscopy (VCE) and double balloon enteroscopy (DBE), the diagnosis of symptomatic MD has been cumbersome. The first reported case of MD being diagnosed by a double-balloon enteroscopy was in 2001 by Yamamoto.<sup>[3]</sup> Since then, several case reports regarding direct visualization of MD with DBE, diagnosing a bleeding MD leading to surgical resection.<sup>[4-7]</sup> We report the use of DBE for the treatment of a bleeding MD.

## CASE REPORT

A 36-year-old Asian male presented with seven years of intermittent melena and maroon-stools, requiring at least five hospitalizations and multiple blood transfusions at outside institutions. Previous examination at other hospitals including endoscopy, colonoscopy, Meckel's scan and VCE had shown only gastric angioectasia as a possible bleeding source. Active bleeding secondary to the gastric angioectasia was never observed. Nevertheless, these lesions were treated with argon plasma coagulation (APC) as recently as two days prior to admission to our institution.

He presented to our institution with melena and maroon colored stools. He was not on aspirin or any NSAID. We performed upper endoscopy, colonoscopy which surveyed approximately 80 cm of the ileum, technetium-99m-tagged red blood cell scan and VCE. VCE showed non-bleeding gastric angiodysplasia which were again ablated with APC. The patient's rectal bleeding subsided and hemoglobin remained stable after four units of packed red blood cell (RBC) transfusion. Two months later, his rectal bleeding recurred required a four unit RBC transfusion. Patient was on Ranitidine one hundred and fifty milligrams orally; daily prior to the admission. Repeat examinations were performed, which revealed a normal Meckel's scan and a tagged RBC scan showing active bleeding in the right lower quadrant of the abdomen. VCE was again performed which showed blood in the terminal ileum. A total of at least of four upper endoscopies, five colonoscopies, three VCE's, two tagged-RBC scans, and two Meckel's scans were performed at multiple institutions. Based on the VCE findings, the source of bleeding was localized to the terminal ileum.

## DISCUSSION AND RESULTS

The patient was referred to Cedars-Sinai Medical Center for a retrograde double balloon enteroscopy. A 2.8 millimeters channel double-balloon enteroscope (Fusion Inc. Wayne, New Jersey) was inserted into the terminal ileum in a

**Address for correspondence:** Prof. Snorri Olafsson, Department of Internal Medicine/Gastroenterology, Loma Linda University Medical Center, Loma Linda, California, USA. E-mail: [SOlafsson@llu.edu](mailto:SOlafsson@llu.edu)

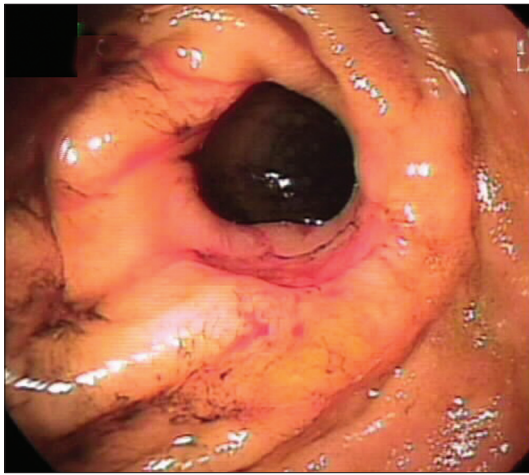


Figure 1: Meckel's diverticulum before therapy

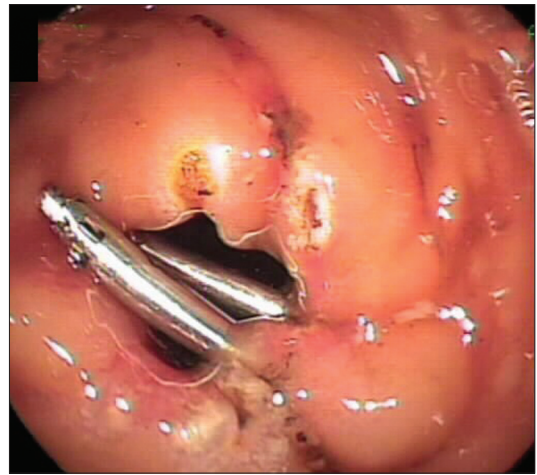


Figure 2: Meckel's diverticulum after therapy. Clips are visible

retrograde fashion through the colon. Approximately at the level of the mid-ileum, a diverticulum was noted with a long shallow ulcer along its rim. Fresh blood was noted oozing from the ulcer. A biopsy taken at the edge of the diverticulum prompted pulsating bleeding that was stopped by a combination of argon plasma coagulation and placement of two endoscopic clips (Resolution Clips, Boston Scientific Inc. Natick, Massachusetts) [Figures 1 and 2]. The clips were also used as a radiological reference of the location of the diverticulum in the event that surgery or radiographic intervention was necessary. There was no evidence of an ulcer proximal or distal to the diverticulum. No further diverticula were identified. Histological examination of the biopsy specimens showed intestinal mucosal ulceration and focal pyloric metaplasia. The patient has been doing well and his bleeding has not recurred in seventy months since the therapeutic DBE. He has not required any more hospitalizations or blood transfusions.

Both DBE and VCE provide a novel path of diagnosing and visualizing small bowel pathology. VCE and DBE may both be essential and complementary studies for the diagnosis of small bowel lesions.<sup>[8]</sup> VCE has the advantage of not requiring sedation and can be used in an ambulatory setting. However, DBE has the ability to perform therapeutic maneuvers including argon plasma coagulation, polypectomy, biopsy, and balloon dilatation.<sup>[1]</sup> Only a few case reports of MD being diagnosed either by VCE or DBE have been reported.<sup>[5-7]</sup> Gasbarrini *et al.*<sup>[1]</sup> reported a case of MD with obscure GI bleeding diagnosed with DBE and was treated with a laparoscopic diverticulectomy. Shinozaki *et al.*<sup>[2]</sup> reported five cases of obscure GI bleeding diagnosed as MD with DBE. Three out of five patients underwent diverticulectomy, one was managed conservatively and one with surgical resection of jejunal tumor. Another case of MD diagnosed by DBE was reported by Ohnita *et al.*<sup>[9]</sup> All cases

of symptomatic MD diagnosed by DBE either underwent diverticulectomy or were managed conservatively. This is the first patient in which a bleeding MD was effectively treated endoscopically with DBE. Thus far the endoscopic treatment has led to a dramatic halt of bleeding for almost six years. In the unlikely event that he re-bleeds we would try another DBE before resorting to surgery.

The question remains whether DBE can replace surgery as the definitive and durable treatment for bleeding MD. Hemostatic endoscopic therapy is now the standard of therapy for bleeding ulcers occurring in gastric mucosa in the stomach. It would therefore not be unexpected if such therapy would also work for ulcerated gastric mucosa causing bleeding in a MD. The development of complications from MD was seen at a rate of 6.4% to occur over a lifetime.<sup>[4]</sup> Unlike traditionally thought, symptomatic MD does not occur more frequently in childhood, and therefore prophylactic resection of incidental asymptomatic MD has been proposed by some surgeons for patients up to eighty years of age.<sup>[4]</sup> Therefore, not all Meckel's diverticula will manifest themselves at an early age. Some patients with symptomatic MD may not be surgical candidates. DBE may play a role in temporizing or possibly curing bleeding secondary to MD. However, to prove this a prospective randomized trial with a long follow-up period would be ideal. However, due to the rarity of the disease a large series with long-term follow-up may be more feasible.

As illustrated in our case, DBE can identify and treat a bleeding MD not available by any other non-surgical modality. It offered an effective treatment for the bleeding diverticulum in our patient thereby avoiding an operation. DBE can provide a minimally invasive and novel endoscopic approach to treatment of a symptomatic MD.

## REFERENCES

1. Gasbarrini A, Di Caro S, Mutignani M, Cammarota G, Fini L, Pacelli F. Double-balloon enteroscopy for diagnosis of a Meckel's diverticulum in a patient with GI bleeding of obscure origin. *Gastrointest Endosc* 2005;61:779-81.
2. Shinozaki S, Yamamoto H, Ohnishi H, Kita H, Yano T, Iwamoto M, *et al.* Endoscopic observation of Meckel's diverticulum by double balloon enteroscopy: Report of five cases. *J Gastroenterol Hepatol* 2008;23:e308-11.
3. Yamamoto H, Sekine Y, Sato Y, Higashizawa T, Miyata T, Iino S, *et al.* Total enteroscopy with a nonsurgical steerable double-balloon method. *Gastrointest Endosc* 2001;53:216-20.
4. Townsend CM, Beauchamp RD, Evers BM, Mattox KL, editors. *Sabiston Textbook of Surgery*. 18th ed. Philadelphia, PA: Elsevier; 2008. p. 1323.
5. Manner H, May A, Nachbar L, Ell C. Push-and-pull enteroscopy using the double-balloon technique (double-balloon enteroscopy) for the diagnosis of Meckel's diverticulum in adult patients with GI bleeding of obscure origin. *Am J Gastroenterol* 2006;101:1152-4.
6. Gölder S, Schmidt J, Kolmsee P, Rösner K, Strik M, Mohren W, *et al.* Identification of a Meckel's diverticulum by wireless capsule endoscopy. *Endoscopy* 2005;37:608.
7. Mylonaki M, MacLean D, Fritscher-Ravens A, Swain P. Wireless capsule endoscopic detection of Meckel's diverticulum after nondiagnostic surgery. *Endoscopy* 2002;34:1018-20.
8. Hadithi M, Heine GD, Jacobs MA, van Bodegraven AA, Mulder CJ. A prospective study comparing video capsule endoscopy with doubleballoon enteroscopy in patients with obscure gastrointestinal bleeding. *Am J Gastroenterol* 2006;101:52-7.
9. Ohnita K, Isomoto H, Mizuta Y, Akazawa S, Akazawa Y, Ohba K, *et al.* Meckel's diverticulum diagnosed by double-balloon enteroscopy. *Endoscopy* 2007;39 Suppl 1:E146-7.

**Cite this article as:** Olafsson S, Yang JT, Jackson CS, Barakat M, Lo S. Bleeding Meckel's diverticulum diagnosed and treated by double-balloon enteroscopy. *Avicenna J Med* 2012;2:48-50.

**Source of Support:** Nil, **Conflict of Interest:** None declared.

### Announcement

#### Android App



Download  
**Android  
application**

FREE

A free application to browse and search the journal's content is now available for Android based mobiles and devices. The application provides "Table of Contents" of the latest issues, which are stored on the device for future offline browsing. Internet connection is required to access the back issues and search facility. The application is compatible with all the versions of Android. The application can be downloaded from <https://market.android.com/details?id=comm.app.medknow>. For suggestions and comments do write back to us.