Why are neurosurgeons hesitant to use the K word for aneurysm surgery?

There is often hesitation especially among several groups of neurosurgeons to use the "keyhole" approach. Though this has not been expressed so in any definite publications this has been voiced strongly in several congresses and within the peer groups.

The apprehension is not fully unjustified especially considering factors such as small margins of error in aneurysm surgery, limitations in devising optimal escape or control routes and a feeling that patient safety is being compromised that come into the surgeon's mind, when considering this approach.

The main argument against the limited craniotomies includes:

1. Restricted maneuverability and vision: There is a feeling that 'keyhole' surgery leads to a restriction to only a single possible trajectory to access the aneurysm along with the parallel orientation of instruments to the light beam leading to the possibility of limited visualization of aneurysms. However, technology is also progressing parallel to the surgical developments. Micro instruments with slim tube-shaft design such as scissors, grasping, and coagulation forceps and narrow shaft clip applicators allow the surgeon to use this access route without hindrance. In addition, endoscope assistance allows a better visualization in this perceived limited field.
2. Full brain: Early opening of basal cisterns and drainage of cerebrospinal fluid is important to gain enough space for comfortable surgical manipulation and temporary clip placement. This allows comfortable management of intra-operative ruptures along with the clip reconstructions of vessel course.
3. Surgeon's experience: This important factor is also to be taken into consideration. In a landmark study by Fischer *et al.*,[1] that included 24 different surgeons performing 1000 surgeries over a 20 year period and demonstrated wide variance with different levels of training. Additionally, temporary clipping was not performed on a regular basis. Even in cases, with intra-operative rupture, surgery could still be successfully completed without the need to switch over to a standard microsurgical approach. Thus restricted maneuverability and narrowing of visual field were not the reasons for failure of a well-planned intervention.

Access this article online	
Quick Response Code:	Website: www.ijns.in
	DOI: 10.4103/2277-9167.110204

Thus, a well-planned approach provides the optimum space required to perform this surgery. One should also not forget that most of aneurysm is good planning, where the surgeon should carefully plan the access and clipping.

With the publication of the international subarachnoid aneurysms trial results,[2] there has been an increasing trend for more number of aneurysms to be treated by endovascular coiling.[3-6] This resulted in aneurysms with favorable configuration (smaller size, adequate dome to neck ratio) and with existing co-morbid illnesses to undergo coiling more often. This has also resulted in more complex aneurysms (like giant aneurysms, unfavorable dome to neck ratio, skull base aneurysms, and those requiring by-pass) to undergo surgery more often.

However, in countries like India, financial consideration is still to be considered as surgery is still by far much cheaper in many government supported institutes and even in private hospitals. This is more so as material resources investment is still higher than the costs incurred towards expertise support in developing countries like India.

The principle of minimally invasive surgery gels well with the principles of evolution itself-progress towards a paradigm that is smaller and compact. This philosophy is well reflected in the IT industry, in mechanization and several other fields. While this philosophy has been well taken up for abdominal procedures (by the extensive and exclusive use of laparoscopy), its ingress has been much slower in neurosurgery. This is because of the general attitude of neurosurgeons (to be more cautious) and of the brain (to be more unforgiving!).

Thus, not surprising, most of the older neurosurgeons are still very cautious to adopt or recommend towards a

minimally invasive approach in aneurysm surgery as they evolved in an era ridden with challenges and once in a while catastrophes.

Fischer *et al*. study[1] demonstrated that the outcome of keyhole surgeries was similar to that of 'open' surgeries. His study of 1000 patients also had about 79 giant aneurysms operated through this technique. While he was cautious enough to comment that only surgeons with adequate experience should adopt this technique, he was also optimistic that this should be the course of future neurosurgery. More than a decade ago, Grand *et al*.,[7] commented "we first practiced the procedure (keyhole supra orbital approach) in the laboratory and then cautiously proceeded to the operating room. In the laboratory, we were able to gauge the difference in instrumentation space available between the pterional craniotomy and the mini-supraorbital craniotomy with or without orbitotomy. Given certain lesions and certain configurations and positions of the aneurysms, the instrumentation space is approximately the same. We have also found this approach to be particularly easy, quick, and direct for certain other lesions of the peri-chiasmatic and supra-chiasmatic region. As with any new procedure, familiarity brings a sense for properly determining its indications."

The Editor has been practicing a "keyhole" approach to aneurysms for the past 4 years with experience of over 100 personally operated cases. We have been careful in selecting the cases for this technique, i.e., only patients with a good grade (H and H grade I or II), CT showing lax brain with no hematoma, relatively simple configuration of aneurysms. We use an infraciliary mini fronto-orbital craniotomy [Figure 1], where the orbital rim along with the plate and the adjacent frontal bone is removed in a single piece. In addition, drilling of the inner table of the

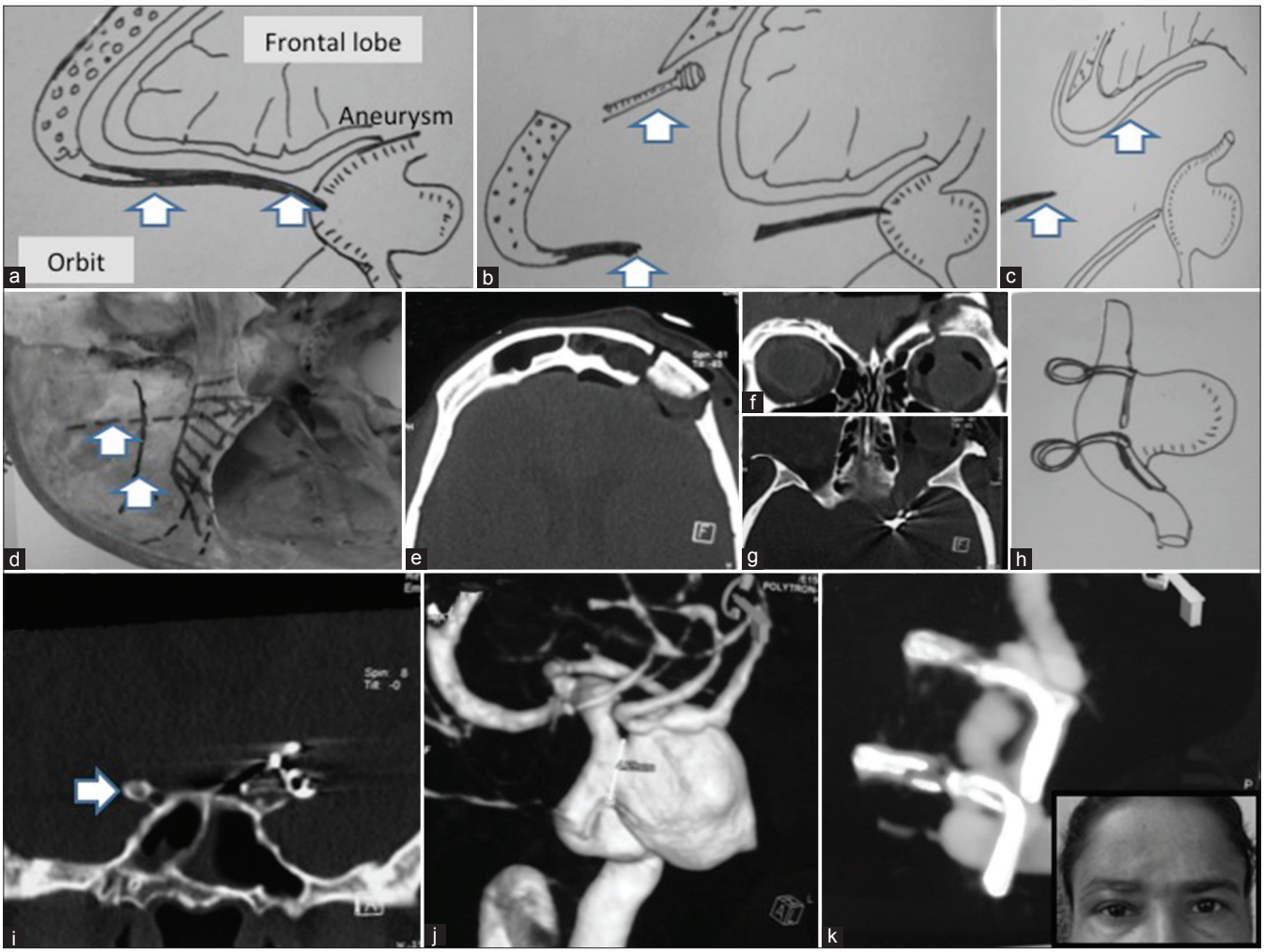

Figure 1: Figure showing evidence of a large superior hypophyseal aneursym operated through a key hole approach, more specifically a mini fronto orbital craniotomy. The same approach was used to drill the anterior clinoid process (a and i) through the orbital roof. Additional space was obtained by drilling the inner table of the frontal bone (b and c). As it can be seen, this approach provides the shortest access to the aneurysm (d-g). The anurysm (j) could be clipped well using 2 fenestrated right angled clips (h and k). While providing almost 30% more space than a conventional supra-orbital key hole approach, the procedure also provides excellent cosmetic approach

frontal bone [Figure 1b] provides much greater space for retraction [arrow, Figure 1c]. Both these techniques have provided almost a similar space and a "surgeon feeling" of operating under an open craniotomy access. The author initially used this approach for relatively simple cases and after this we performed this for more complex pathologies. With experience, the comfort factor increased and over a period of time as observed by Walter Grand, this approach provided a very quick and short access to the anterior circulation aneurysms. This approach also allowed the author to drill the clinoid process extradurally by just following the orbital roof [Figure 1d-g]. The space was also adequate to place multiple clips even for complex aneurysm configurations [Figure 1h-k]. Providing an infraciliary incision [Figure lk, inset] provided a very good cosmetic outcome.

Keyhole surgery for aneurysm should become a part of a neurosurgeon's armentorium as like multiple other procedures.[7-10] While coiling has become a standard for most aneurysms, there are still some limitations of this procedure. Financial consideration is one important factor especially in developing countries. Clipping will still continue to be an important component of aneurysm surgery and will be required in many situations and even in combination with endovascular intervention. However, this technique should be practiced or attempted only by those neurosurgeons with significant experience in this field.

P. Sarat Chandra

Department of Neurosurgery, All India Institute of Medical Sciences, New Delhi, India
E-mail: saratpchandra3@gmail.com

REFERENCES

1. Fischer G, Stadie A, Reisch R, Hopf NJ, Fries G, Böcher-Schwarz H, *et al*. The keyhole concept in aneurysm surgery: Results of the past 20 years. Neurosurgery 2011;68:45-51.
2. Molyneux A, Kerr R, Stratton I, Sandercock P, Clarke M, Shrimpton J, *et al*. International Subarachnoid Aneurysm Trial (ISAT) of neurosurgical clipping versus endovascular coiling in 2143 patients with ruptured intracranial aneurysms: A randomised trial. Lancet 2002;360:1267-74.
3. Qureshi AI, Vazquez G, Tariq N, Suri MF, Lakshminarayan K, Lanzino G. Impact of International Subarachnoid Aneurysm Trial results on treatment of ruptured intracranial aneurysms in the United States. Clinical article. J Neurosurg 2011;114:834-41.
4. Alshekhlee A, Mehta S, Edgell RC, Vora N, Feen E, Mohammadi A, *et al*. Hospital mortality and complications of electively clipped or coiled unruptured intracranial aneurysm. Stroke 2010;41:1471-6.
5. Gnanalingham KK, Apostolopoulos V, Barazi S, O'Neill K. The impact of the international subarachnoid aneurysm trial (ISAT) on the management of aneurysmal subarachnoid haemorrhage in a neurosurgical unit in the UK. Clin Neurol Neurosurg 2006; 108:117-23.
6. Grand W, Landi MK, Daré AO. Transorbital keyhole approach to anterior communicating artery aneurysms. Neurosurgery 2001; 49:483-4.
7. Mocco J, Komotar RJ, Raper DM, Kellner CP, Connolly ES, Solomon RA. The Modified Pterional Keyhole Craniotomy for Open Cerebrovascular Surgery: A New Workhorse? J Neurol Surg A Cent Eur Neurosurg. 2013 Feb 20.
8. Fischer G, Stadie A, Reisch R, Hopf NJ, Fries G, Böcher-Schwarz H, *et al*. The keyhole concept in aneurysm surgery: Results of the past 20 years. Neurosurgery. 2011;68:45-51.
9. Heros RC. The supraorbital "keyhole" approach. J Neurosurg. 2011;114:850-1.
10. Beseoglu K, Lodes S, Stummer W, Steiger HJ, Hänggi D. The transorbital keyhole approach: Early and long-term outcome analysis of approach-related morbidity and cosmetic results. Technical note. J Neurosurg. 2011;114:852-6.

How to cite this article: Chandra PS. Why are neurosurgeons hesitant to use the K word for aneurysm surgery?. Indian J Neurosurg 2013;2:1-3.