

Anticoagulant induced spontaneous spinal epidural hematoma

Sir,

Spontaneous spinal epidural hematoma (SSEH) is an uncommon but serious cause of acute spinal cord compression. The association of spinal epidural hematoma with warfarin therapy has been described in literature, although many of the reported cases were anticoagulated within the therapeutic range.^[1] SSEH should be suspected in any patient receiving anticoagulants who presents with local or referred back pain associated with limb weakness, sensory deficits or urinary retention. A 21-year-old male with SSEH who was receiving warfarin for hyperhomocysteinemia with sagittal sinus thrombosis is presented in this letter.

A 21-year-old male was brought to the emergency

department with the complaints of severe neck pain for 6 days; followed by acute onset paraparesis and urinary retention from 1 day. On examination patients power in lower limbs was 0/5 and in upper limb it was 1/5, reflexes were brisk. Patient was a known case of hyperhomocysteinemia and was on regular medical treatment. Patient had a history of sagittal sinus thrombosis for which he was on tablet warfarin 5 mg. Magnetic resonance imaging (MRI) whole spine revealed extensive hematoma anterior to cord extending from C2 to L4 level with a maximum thickness in cervical level with hematomyelia. Figures 1-4 INR was 2.7 and PT was prolonged. Patient was started steroids and supportive treatment along with correction of coagulation profile with 6 units of fresh frozen plasma and Vitamin K 10 mg once daily. As the hematoma was

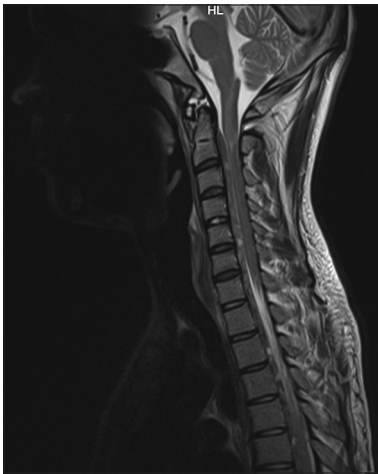

Figure 1: Magnetic resonance imaging cervical spine sagittal cuts showing epidural haematoma

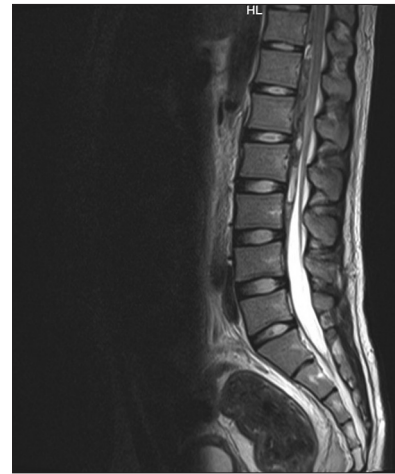


Figure 2: Magnetic resonance imaging lumbar spine sagittal cuts showing epidural haematoma

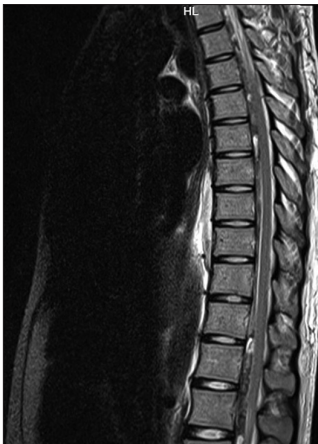

Figure 3: Magnetic resonance imaging dorsal spine sagittal cuts showing epidural haematoma

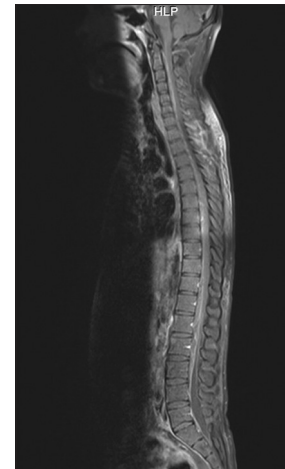


Figure 4: Magnetic resonance imaging whole spine

involving whole spine, INR was deranged and ictus was 6 days old, patients family was counseled and explained risks and benefits with and without decompression and patient was managed conservatively.

The first case report of spinal epidural hematoma was described by Jackson in 1869.^[2] Spinal epidural hematoma is a rare condition; It may develop due to trauma, blood dyscrasia, anticoagulation therapy, vascular malformation, spinal anesthesia or lumbar puncture.^[3] The term SSEH is given if no cause can be identified, which occurs in 40-50% of the cases.^[1,2] Spinal epidural hematoma is believed to result from rupture of fragile epidural venous plexus after the sudden increase in intra-thoracic or intra-abdominal pressure.^[1] An average of 3.8 spinal segments is involved. The most common sites affected are the cervicothoracic or thoracolumbar junction. Many authors have pointed out that delay of more than 6 h reduces the probability of recovery and the outcome is poor if decompression is done after 36 h.^[1,2,4] The classical presentation is a sudden onset of severe spinal pain followed by radicular pain and usually progress rapidly to paraplegia or quadriplegia. MRI scanning is the preferred method of diagnosis as it readily distinguishes spinal epidural hemorrhage from other lesions. Unless neurological signs are minimal, treatment consists of reversal of anticoagulation and prompt decompression of the hematoma.^[5] The above case is a reminder to consider spinal epidural hematoma in patients on anticoagulant therapy who develop a sudden onset of spinal pain with or without neurological deficit.

The purpose of sending this article is to increase awareness of this entity and to stress the urgency of management, as the outcome is poor if decompression is delayed.

Jasmit Singh, Hrushikesh Kharosekar,
Vernon Velho, Harish Naik

Departments of Neurosurgery, Grant Medical College,
Mumbai, Maharashtra, India
E-mail: jasmeetthukral80@gmail.com

REFERENCES

1. Winer BM. Spinal epidural hematoma during anticoagulant therapy. *Circulation* 1959;XIX:735-40.
2. Chan KM. Case report: Thoracic spinal epidural haematoma – An unusual cause of chest pain. *Hong Kong J Emerg Med* 2006; 13:217-20.
3. Prasad SS, O'Malley M, Machani B, Shackleford IM. A case report of a spinal epidural haematoma associated with warfarin therapy. *Ann R Coll Surg Engl* 2003;85:277-8.
4. Sung JH, Hong JT, Son BC, Lee SW. Clopidogrel-induced spontaneous spinal epidural hematoma. *J Korean Med Sci* 2007;22:577-9.
5. Strain RE. Spinal epidural hematoma in patients on anticoagulant therapy. *Ann Surg* 1964;159:507-9.

Access this article online	
Quick Response Code:	Website: www.ijns.in
	DOI: 10.4103/2277-9167.132012