

Traumatic pneumorrhachis

Sir,

A 50-year-old male patient presented with history of sustaining a head injury due to a road accident. He had a history of the left ear bleed, vomiting and loss of consciousness. His admission Glasgow coma scale was 14 (E4V4M6). He also had a left facial palsy (House and Brackmanns Grade III). Computed tomography (CT) scan of the head showed extensive pneumocephalus extending into the cervical canal, with fracture of left petrous temporal and basiocciput bones. X-ray cervical and CT cervical spine both showed evidence of pneumorrhachis [Figure 1]. X-rays of the chest and extremities did not show any evidence of fracture or traumatic injury. He was treated conservatively with oxygen by mask, antibiotics, anticonvulsants and other supportive measures. Repeat CT scan was done after 2 days showed resolving pneumocephalus, with resolved pneumorrhachis. He developed left cerebrospinal fluid (CSF) otorrhea after 3 days of the trauma. It was managed conservatively with 2 consecutive days of drainage lumbar puncture and oral acetazolamide. Patient improved symptomatically and was discharged on day 12 without any symptoms or gross neurological deficit except left facial paresis.

As compared to iatrogenic and nontraumatic causes, the traumatic pneumorrhachis is very rare phenomenon. Only eight cases with pneumorrhachis extending to more than one spinal region had been reported in the literature.^[1] Gordon had initially described the phenomenon of intraspinal air.^[2] The term

“pneumorrhachis” was used for the first time by Newbold *et al.*^[3] The two subtypes of pneumorrhachis, which includes epidural or subarachnoid, are difficult to distinguish even with CT scanning. However, the presence of pneumocephalus goes more in favor of subarachnoid subtype. Goh and Yeo in their study have reported that the epidural pneumorrhachis is self-limited, whereas the more common subarachnoid pneumorrhachis type may be complicated by tension pneumocephalus and meningitis.^[4] Traumatic subarachnoid pneumorrhachis is almost always secondary to major trauma and is a marker of a severe injury. The pathophysiology described for it states that, the penetrated air, which had led to the formation of pneumocephalus might have been forced caudally due to the raised intracranial pressure as a consequence of severe brain injury and patient’s horizontal position allowing the entrapped air to pass through the foramen magnum into the spinal canal.^[5] Due to its rareness, asymptomatic presentation and myriad etiologies, no guidelines for its treatment or care has been described. Pneumorrhachis typically resolves spontaneously but occasionally it can have serious complications. Patient with subarachnoid pneumorrhachis should be treated meticulously and a temporary lumbar drainage may be required if they have concomitant CSF leak.

Shailendra D. Anjankar, Raju Subodh

Department of Neurosurgery, Kamineni Hospitals Ltd., L. B. Nagar,
Hyderabad, Andhra Pradesh, India
E-mail: sdanjankar@rediffmail.com

REFERENCES

1. Gelalis ID, Karageorgos A, Arnaoutoglou C, Gartzonikas D, Politis A, Georgakopoulos N, *et al.* Traumatic pneumorrhachis: Etiology, pathomechanism, diagnosis, and treatment. *Spine J* 2011; 11:153-7.
2. Gordon IJ, Hardman DR. The traumatic pneumomyelogram. A previously undescribed entity. *Neuroradiology* 1977;13:107-8.
3. Newbold RG, Wiener MD, Vogler JB 3rd, Martinez S. Traumatic pneumorrhachis. *AJR Am J Roentgenol* 1987;148:615-6.
4. Goh BK, Yeo AW. Traumatic pneumorrhachis. *J Trauma* 2005;58:875-9.
5. Dawar P, Sedain G, Sinha S. Traumatic pneumorrhachis with tension pneumocephalus. *Indian J Neurosurg* 2013;2:207-9.

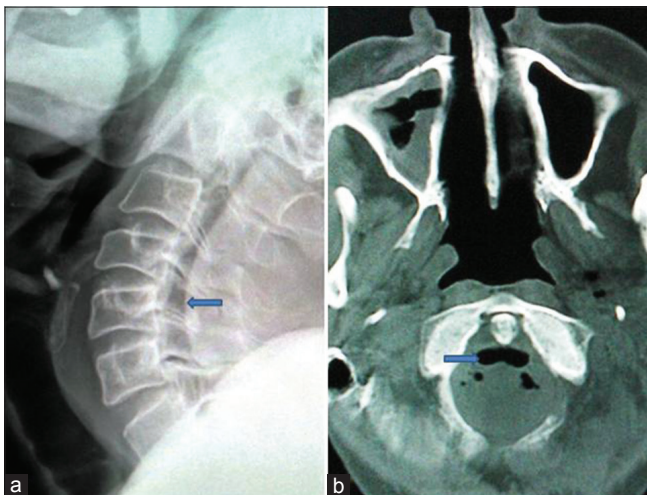


Figure 1: X-ray cervical spine – lateral view (a) and computed tomography scan – axial view (b) Pneumorrhachis (shown by arrow)

Access this article online

Quick Response Code:



Website:

www.ijns.in

DOI:

10.4103/2277-9167.132015