

# Ultrasonic osteotome: A cutting edge technology, our experience in 96 patients

V. Velho, H. Kharosekar, S. Jasmit, Shonali Valsangkar, D. A. Palande

Department of Neurosurgery, Sir J. J. Group of Hospitals and Grant Medical College, Mumbai, Maharashtra, India

## ABSTRACT

**Background:** The ultrasonic osteotome is a tissue-specific device that allows the surgeon to make precise osteotomies while protecting collateral or adjacent soft tissue structures. The recurring impacts pulverize the noncompliant crystalline structure resulting in a precise cut. The more compliant adjacent soft tissue is not affected by the ultrasonic oscillation. **Objective:** The purpose of this study is to present our experience of using this technology in osteotomies. **Materials and Methods:** We reviewed 96 patients, both male and female; of different ages in which ultrasonic osteotome was used to perform an osteotomy of different manners (Craniotomy, laminotomy, facetectomy, etc.). Patients with head injury, spine injury, degenerative spine diseases, and brain tumors were included in this study. **Results:** In all these patients, the bone cut was even with minimal surrounding bone loss. The time required for the osteotomy was reduced to half. There was no damage to underlying dura, cord or nerve structures. **Conclusions:** Ultrasonic osteotome is a safe and effective ultrasonic bone cutting device that can be used to facilitate osteotomies in various types of cranial and spinal surgeries. This device allows precision bone cutting with minimal surrounding bone loss and obviates the risk associated with the use of high-speed burrs and oscillating saws.

**Key words:** Bone loss, craniotomy, osteotomy, ultrasonic osteotome

## INTRODUCTION

Nature has protected nervous tissue in a highly compact way by enclosing it in a series of bones. Literature is full of references on the difficulties faced in approaching both brain and spine by physicians in the ancient times. It has been nullified to an extent with the advent of the surgical tools such as rotating burrs and thread wire saws, high-speed drills. Still these tools can result in significant damage to the underlying covering and the neural tissue if they are not handled properly. And to add to it is the time required to raise the osteotomy and blood loss that results during this procedure. If the surgeon is the sole operating hand, it invariably adds to the fatigue. The use of high-speed drills invariably leave a significant defect between two adjacent bones, resulting in poor cosmesis. The use of ultrasonic technology for bone removal offers the potential advantages over the

use of traditional hand instruments or cutting burrs of more precise bone resection and reduced soft tissue injury. In recent years, a novel ultrasonic osteotome has been introduced into the surgical field. This is a low-frequency ultrasonic device that selectively cuts dense mineralized tissue like bone, while theoretically causing little damage to the surrounding soft tissues. The device is comprised of a blunt ultrasonic blade that oscillates at over 22,500 cycles/s with an excursion ranging from 35 to 300  $\mu$ m depending on amplitude setting and blade geometry. The recurring impacts pulverize the noncompliant crystalline structure resulting in a precise cut. The more compliant adjacent soft tissue is theoretically not affected by the ultrasonic oscillation as the ultrasonic waves are transmitted peripherally.<sup>[1]</sup>

Ultrasonic devices originally developed for dentistry first appeared in 1952 and were quickly adapted, and their use was expanded. By the 1970s the technology allowed for effective debulking and removal of soft tissue tumors. Adaptations of this technology have developed enabling bone dissection with a narrow cutting blade, which has the advantage of reducing bone debris.<sup>[2]</sup>

The purpose of this study was to report our experience and safety of using this ultrasonic osteotome device

Access this article online	
Quick Response Code:	Website: www.ijns.in
	DOI: 10.4103/2277-9167.146829

**Address for correspondence:** Dr. V. Velho, Department of Neurosurgery, 4<sup>th</sup> Floor, Grant Medical College and Sir J. J. Group of Hospitals, Byculla, Mumbai - 400 008, Maharashtra, India. E-mail: hkharsekar@gmail.com

in a variety of cranial, as well as spinal neurosurgical procedures. Until now, no data in cranial neurosurgical procedures has been published.

### MATERIALS AND METHODS

We conducted a prospective study of 96 patients who underwent cranial and spine surgeries with the use of the ultrasonic osteotome from June 2012 to January 2014. Patient's age, gender, diagnosis and surgical procedure were documented. Surgical time, blood loss and intra-operative dural, bone loss and nerve injuries were recorded. All cases were performed at the same hospital by a single surgeon. Patients with head injury, spine injury, degenerative spine diseases and brain tumors were included in this study. Craniotomies, Osteotomies, laminotomies and one graft harvesting were performed using bone scalpel.

The ultrasonic osteotome used in our series has a long, narrow blade with a cutting surface of 7 mm and 10 mm in length and 0.5–1.0 mm in width. This is as disposable blade for single use. The device is comprised of a blunt ultrasonic blade that oscillates at over 22,500 cycles/s with an excursion ranging from 35 to 300 lm depending on amplitude setting and blade geometry. Each blade cost us 23000 Indian Rs. It was not a financial burden for patients in our study as blades were provided by government funded insurance scheme.

### RESULTS

Of the 96 patients included in our study, 58 were male, and 38 were females [Table 1]. The mean age of the patients in our study was 52 years of 96 procedures, 70 were craniotomies, 14 were laminectomies, 5 corpectomies, 5 bone graft harvesting and 2 were depressed fracture skull surgery [Figures 1-3] [Tables 2 and 3]. Average osteotomy time was 5–7 min, blood loss was <15 ml. Bone cut was 1–2 mm thickness, and there was no soft tissue injury or dural tear. In only one case of craniotomy superficial layer of dura as cut, deeper layer as intact [Table 4]. This patients age was 68 year and dura was adherent to bone. Neurovascular injury was not seen.

Table 1: Demographic data	
Type	Number
Sex	
Male	58
Females	38
Procedure	
Cranial	72
Spinal	24

Patients were followed-up up to 3 months; cosmetic results were good due to minimal bone loss, especially in pterional and frontal craniotomies (where the bone loss leads to significant cosmetic deformity).

Among the 14 laminectomies 8 were cervical and 6 were lumbar laminectomy. 5 cervical corpectomies were done. Use of ultrasonic osteotome made bone cutting easy, especially in tight canal stenosis and large osteophytes. Average time for laminectomy was reduced to 20 min (3 level) and 15 min for single level corpectomy (50% less).

We used Ultrasonic osteotome for suboccipital craniotomy in which we could cut across the sinus without injuring it and cosmetic outcome as very good as one loss was minimal. [Figure 4].

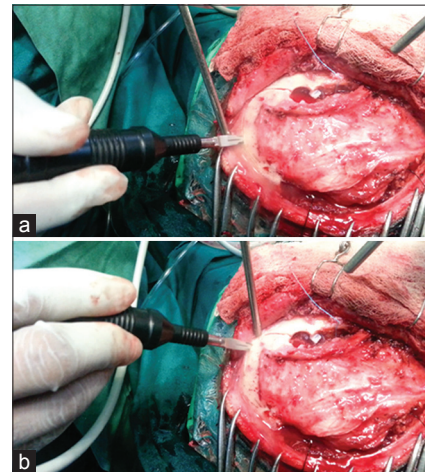


Figure 1: (a and b) Use of bone scalpel for pterional craniotomy

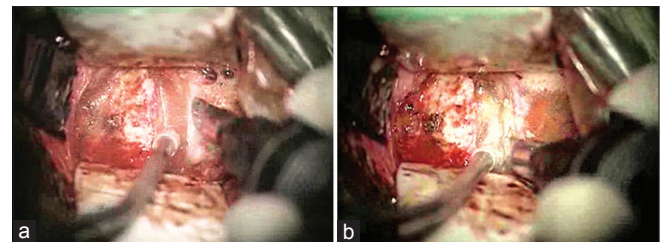


Figure 2: (a and b) Use for cervical corpectomy

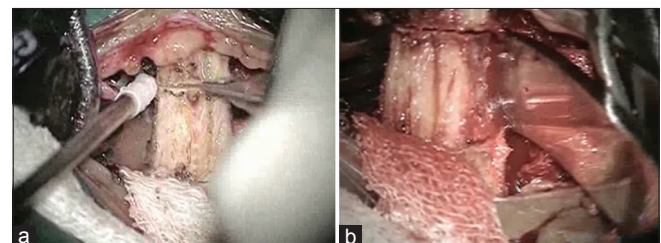


Figure 3: (a and b) Use for iliac crest grafting

## DISCUSSION

Bone removal is an essential step in neurosurgery which can sometimes be challenging. Traditional osteotomy instruments such as high-speed drills, rotating burrs and thread wire saws can produce considerable vibration and torque intra-operatively. In addition, manual osteotomes require malleting, which is accompanied by the risk of plunging into the soft tissues of the epidural space. Some reports have showed that there is an increased risk of durotomy and neural injury, especially when performing osteotomy in a deep area, in a narrow surgical field, or in a revision situation.

The use of ultrasonic vibration for the cutting of bone was developed several decades ago. However, it was only in the last several years that the tools and technique have been adopted in the surgical field, especially for oral and maxillofacial surgeries. The ultrasonic osteotome used in our series has a long, narrow blade with a cutting surface of 7 mm and 10 mm in length [Figure 5] and 0.5-1.0 mm in width. The device allows for bone dissection along a narrow cutting blade which vibrates longitudinally at high frequency. The surgeon can create narrow bone cuts with minimal bone debris and destruction. As soft tissue has greater elastic properties than osseous structures, it can thus withstand high amounts of impact energy

which help to create a well-controlled environment for bone removal and minimize the risk of dural and neural injury.<sup>[1]</sup>

In this study, we reported our experience with 96 consecutive cranial and spine surgeries with the use of an ultrasonic scalpel. In all cases, the ultrasonic osteotome was successfully used to create the needed osteotomies with high precision to facilitate the surgical procedure. We found that one of the major advantages (although difficult to objectively quantify) of this ultrasonic device is the reduction of bleeding that helps to create and maintain visibility in the surgical field. Sanborn *et al.* have also reported that there is a notable reduction in osseous bleeding in the ultrasonic scalpel group compared with the traditional technique in their series that may attribute to a local hemostatic effect. As a result improved precision, technically challenging osteotomy procedures can now be performed in less time with the ultrasonic scalpel. The ultrasonic scalpel uses a narrow blade with a self-irrigating system that provides lubrication and

**Table 2: Distribution of cases**

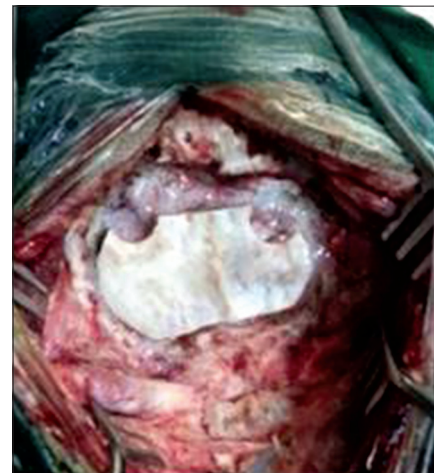Procedure	Number
Craniotomy	70
Laminectomy	14
Corpectomy	5
Bone graft harvesting (iliac crest)	5
Depressed fracture skull	2

**Table 3: Distribution of cranial surgeries**


Procedure	Number
Pterional craniotomy	18
Suoccipital craniotomy	15
Frontal craniotomy	14
Parietal craniotomy	13
Bifrontal craniotomy	10

**Table 4: Observed parameters**

Observation	Number
Operative time	7-10 min
Blood loss	<15 ml
Bone loss	1-2 mm
Vascular injury	Nil
Soft tissue injury	Nil
Dural tear	Nil



**Figure 4:** Bone flap raised in suboccipital craniotomy



**Figure 5:** Bone scalpel blade

cooling into the cutting cavity and limits the risk of mechanical and thermal injury.

In our study, we had 2 cases only with superficial/partial dural tear, less compared with 11 dural tear reported by Hu *et al.* This can be explained as our study had no Reexplorations while Hu *et al.* had maximum reexplorations.<sup>[1]</sup>

There is a learning curve to safely using this novel device till surgeon gets the haptic feel and control of the device. We suggest that surgeons who are new to this technique use particular care to avoid local temperature increases from the frictional effects. Generous irrigation should be applied to achieve effective cooling.

There are limitations in this study. We have presented case series review, and there is no control group. As there are many other surgical tools used together with the ultrasonic scalpel during the surgery, it is difficult

to evaluate the exact benefits of this osteotome device. Well-designed controlled studies can potentially be carried out in animal models. Future efforts could also be made to evaluate if the use of this ultrasonic device led to improved clinical outcome in the patients who had spine surgeries.

## REFERENCES

1. Hu X, Ohnmeiss DD, Lieberman IH. Use of an ultrasonic osteotome device in spine surgery: Experience from the first 128 patients. *Eur Spine J* 2013;22:2845-9.
2. Al-Mahfoudh R, Qattan E, Ellenbogen JR, Wilby M, Barrett C, Pigott T. Applications of the ultrasonic bone cutter in spinal surgery – our preliminary experience. *Br J Neurosurg* 2014;28:56-60.

**How to cite this article:** Velho V, Kharosekar H, Jasmit S, Valsangkar S, Palande DA. Ultrasonic osteotome: A cutting edge technology, our experience in 96 patients. *Indian J Neurosurg* 2014;3:150-3.

**Source of Support:** Nil, **Conflict of Interest:** None declared.

### Author Help: Reference checking facility

The manuscript system ([www.journalonweb.com](http://www.journalonweb.com)) allows the authors to check and verify the accuracy and style of references. The tool checks the references with PubMed as per a predefined style. Authors are encouraged to use this facility, before submitting articles to the journal.

- The style as well as bibliographic elements should be 100% accurate, to help get the references verified from the system. Even a single spelling error or addition of issue number/month of publication will lead to an error when verifying the reference.
- Example of a correct style  
Sheahan P, O'leary G, Lee G, Fitzgibbon J. Cystic cervical metastases: Incidence and diagnosis using fine needle aspiration biopsy. *Otolaryngol Head Neck Surg* 2002;127:294-8.
- Only the references from journals indexed in PubMed will be checked.
- Enter each reference in new line, without a serial number.
- Add up to a maximum of 15 references at a time.
- If the reference is correct for its bibliographic elements and punctuations, it will be shown as CORRECT and a link to the correct article in PubMed will be given.
- If any of the bibliographic elements are missing, incorrect or extra (such as issue number), it will be shown as INCORRECT and link to possible articles in PubMed will be given.