

Massive hemopericranium following trivial trauma in a child with hypofibrinogenemia: A case report and review of the literature

Rajeev Sharma, Rajkumar Raj¹, Laxmi Naraiian Gupta¹

Department of Neurosurgery, All India Institute of Medical Sciences, ¹Department of Neurosurgery, PGIMER, Dr. RML Hospital, New Delhi, India

ABSTRACT

Subgaleal hematoma is a potentially life-threatening extracranial bleed that occurs most commonly in neonates after difficult instrumental deliveries. Its occurrence beyond the neonatal period is rare and is often associated with head trauma involving tangential or radial forces applied to the scalp causing emissary veins traversing the subgaleal space to be ruptured. Large progressive subgaleal hematoma due to trivial head trauma in a 5-years-old child of hypofibrinogenemia with no reported literature is interesting to describe.

Key words: Bleeding disorder, hemopericranium, hypofibrinogenemia, scalp hematoma, trivial trauma

INTRODUCTION

Subgaleal hematoma is bleeding in the potential space between the skull periosteum and the scalp galea aponeurotica. They generally have low volume and often resolve spontaneously.^[1] Occasionally, they can achieve a large volume and may endanger the patient's life especially in neonates. Intracerebral hematoma does not correlate with the severity of subgaleal hematoma.^[2] This article describes a case of massive and progressive subgaleal hematoma due to a coagulation defect managed successfully by needle aspiration.

CASE REPORT

A 5-years-old boy who had undergone craniotomy for evacuation of a large left frontoparietal extradural hematoma following trivial trauma 2 years back had presented with a progressive increase in head size following a trivial fall over last 1 month. History of massive caput succedaneum at birth (full term normal vaginal delivery) and prolonged profuse bleeding from

minor injuries in the past was present, but there was no externally visible bleeding this time. There was no history suggesting a familial bleeding disorder. Clinically, child was active and alert without any neurological deficit. Head circumference was 62 cm, with fluctuant nontender circumferential scalp swelling [Figure 1a] with areas of crust formation (due to pressure necrosis) without any discharge. Question mark scar of the previous craniotomy on the left side of the head was present. There were no features of raised intracranial pressure, meningitis, or scalp infection. Computed tomography (CT) head [Figure 2] showed a left parieto-occipital extradural hematoma and massive circumferential extracalvarial hypodense scalp collection [Figure 2a] which was increasing on repeat scan [Figure 2b]. There was no brain parenchymal hematoma or skull fracture. Hemogram, peripheral smear, liver and renal function tests, and abdominal ultrasound were normal. Blood group was O positive. Both prothrombin time (PT) and activated partial thromboplastin time (aPTT) were deranged, but thrombin time was normal. Serum fibrinogen level was low - 156 mg/dL (normal 200–400 mg/dL). Factors V and VIII assays were normal. D-dimer assay was normal. Patient was managed by fresh frozen plasma (FFP) transfusion till correction of PT and aPTT followed by needle aspiration of scalp collection - 1300 ml of altered liquefied blood was aspirated (in three stages) and circumferential pressure head bandage was applied. Head circumference reduced to 48 cm [Figure 1b]. He is asymptomatic at 6 months follow-up and is advised to take precautions to avoid all sorts of injuries like contact sports.

Access this article online	
Quick Response Code:	Website: www.ijns.in
	DOI: 10.4103/2277-9167.146835

Address for correspondence: Dr. Rajeev Sharma, Department of Neurosurgery, All India Institute of Medical Sciences, New Delhi - 110 029, India. E-mail: rajufbd79@rediffmail.com

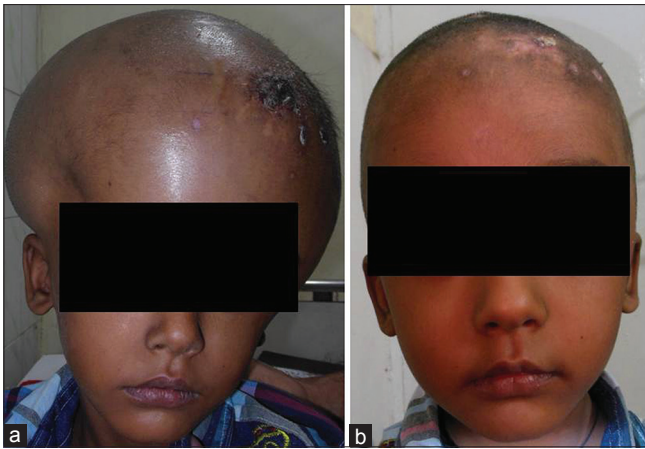

Figure 1: (a) Clinical photograph of the patient taken 35 days after trival trauma (before needle aspiration) showing large head due to circumferential scalp swelling. (b) Clinical photograph of the patient taken 10 days after needle aspiration of scalp collection showing reduction in head size

DISCUSSION

Fibrinogen is a 340-kDa protein synthesized primarily by hepatocytes. Normal plasma fibrinogen concentrations (FCs) typically range from 200–350 mg/dL, with a half-life of approximately 3 days.^[3] Fibrinogen molecules act during both cellular and fluid phases of coagulation. In the cellular phase, it facilitates the aggregation of platelets via binding of glycoprotein IIb/IIIa receptors on platelet surfaces. In the fluid phase, it is cleaved by thrombin to produce fibrin monomers, which polymerize to form the basis of the clot.^[4]

Afibrinogenemia represents total absence of fibrinogen and is an autosomal recessive disorder causing mainly mild-to-severe bleeding from the stump of umbilicus and mucosa. Hereditary defects of fibrinogen can affect either the quantity (afibrinogenemia and hypofibrinogenemia) or the quality (dysfibrinogenemia) of circulating fibrinogen.^[3] Hypofibrinogenemia shows decrease levels of fibrinogen with a milder or no bleeding.^[5] Dysfibrinogenemia represents a qualitative defect in fibrinogen molecule that causes a decrease in the rate of fibrin polymerization and is most commonly acquired due to liver disease or any cancer. Patients with hypofibrinogenemia and dysfibrinogenemia typically experience less frequent and less severe bleeding events, but are at risk for hemorrhage related to trauma, pregnancy, and surgery.^[3]

Fibrinogen levels may fall after injury due to brain tissue destruction, on-going hemorrhage, acidosis, or hypothermia.^[6] Hiiippala *et al.*^[7] in a prospective observation of plasma concentrations of clotting factors in patients undergoing major urologic or abdominal surgery ($n = 60$) showed that levels of prothrombin, Factor V, Factor VII, and fibrinogen were all significantly reduced

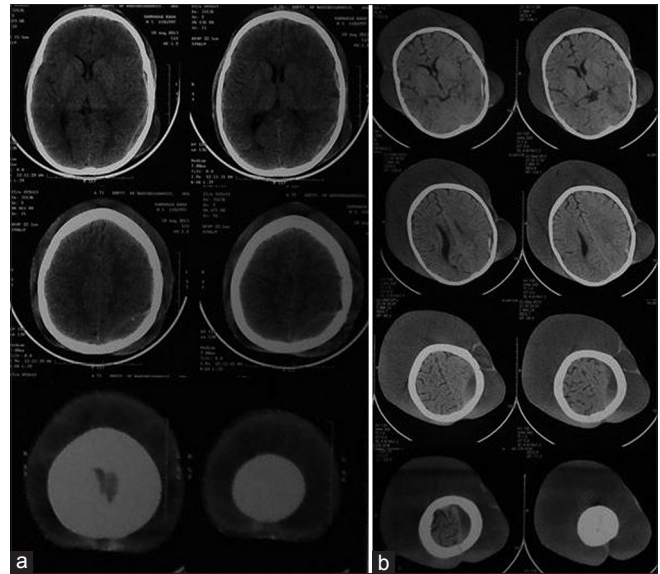


Figure 2: (a) Computed tomography (CT) head plain done at 5 days after trival trauma showing left parieto-occipital extradural hematoma and massive circumferential extracranial hypodense scalp collection. (b) Repeat CT head plain done at 30 days after trival trauma showing increase in circumferential extracranial hypodense scalp collection and resolving left parieto-occipital extradural hematoma

after blood loss and subsequent fluid replacement (red blood cells and colloids). Due to its relatively high initial plasma concentration, fibrinogen was the first clotting factor to decrease to critically low levels.

Treatment for fibrinogen deficiency is fibrinogen supplementation with fresh frozen plasma (FFP), cryoprecipitate (Cryo), or fibrinogen concentrate (FC). Unlike FC; FFP and Cryo require blood type matching and thawing before use. The use of FFP and Cryo has declined due to the risk of transfusion-associated complications like allergic reactions, volume overload, and transfusion-related acute lung injury (TRALI). In addition, thrombosis has been reported with fibrinogen replacement therapy.^[3,4] Human plasma-derived, viral-inactivated FCs are available worldwide. The revised European trauma guidelines (2010) recommend a trigger fibrinogen concentration of 1.5–2.0 g/L.^[8]

Nontraumatic subgaleal hematoma, although very rare, is sometimes associated with aneurysms of the superficial temporal artery, scalp arteriovenous fistula, and coagulation disorders.^[9] It often resolves spontaneously or with conservative treatment using a compression bandage and coagulopathy correction. However, aspiration or surgery may be mandatory in case of failure of conservative treatment.^[11]

Head trauma involving application of tangential or radial forces to the scalp causing rupture of emissary

veins traversing the subgaleal space can lead to the formation of subgaleal hematoma.^[10] Following trivial trauma, some emissary vein might have ruptured which would have continued to bleed internally due to the presence of an underlying coagulation disorder (hypofibrinogenemia) leading to the formation of massive subgaleal hematoma in our patient. Absence of spontaneous bleeding episodes in our patient is probably due to availability of slightly low levels of fibrinogen, which get reduced further following trivial trauma leading to prolongation of bleeding. Past history of massive caput succedaneum at birth and prolonged profuse bleeding from minor injuries in our patient is suggestive of the disorder most probably being present since birth.

CONCLUSION

Patients developing massive hemopericranium following trivial trauma should be investigated to rule out any coagulation pathway defect. Neonatal coagulation screening is useful for the diagnosis of congenital coagulation pathway defects.

REFERENCES

1. Kichari JR, Gielkens H. Massive traumatic subgaleal haematoma. *Emerg Med J* 2013;30:344.
2. Kilani RA, Wetmore J. Neonatal subgaleal hematoma: Presentation and outcome – radiological findings and factors associated with mortality. *Am J Perinatol* 2006;23:41-8.
3. Bornikova L, Peyvandi F, Allen G, Bernstein J, Manco-Johnson MJ. Fibrinogen replacement therapy for congenital fibrinogen deficiency. *J Thromb Haemost* 2011;9:1687-704.
4. Levy JH, Szlam F, Tanaka KA, Sniecinski RM. Fibrinogen and hemostasis: A primary hemostatic target for the management of acquired bleeding. *Anesth Analg* 2012;114:261-74.
5. Paolini R, Sartori MT, Fiorin F, Gorinati M, Boeri G, Girolami A. Perinatal intracranial hemorrhage as first manifestation of congenital hypofibrinogenemia. *Clin Appl Thromb Hemost* 1996;2:60-3.
6. Chhabra G, Rangarajan K, Subramanian A, Agrawal D, Sharma S, Mukhopadhyay AK. Hypofibrinogenemia in isolated traumatic brain injury in Indian patients. *Neurol India* 2010;58:756-7.
7. Hiiipala ST, Myllylä GJ, Vahtera EM. Hemostatic factors and replacement of major blood loss with plasma-poor red cell concentrates. *Anesth Analg* 1995;81:360-5.
8. Rossaint R, Bouillon B, Cerny V, Coats TJ, Duranteau J, Fernández-Mondéjar E, et al. Management of bleeding following major trauma: An updated European guideline. *Crit Care* 2010;14:R52.
9. Koizumi K, Suzuki S, Utsuki S, Nakahara K, Niki J, Mabuchi I, et al. A case of non-traumatic subgaleal hematoma effectively treated with endovascular surgery. *Interv Neuroradiol* 2010;16:317-21.
10. Panigrahi S, Mishra SS, Das S, Patra SK. Large subgaleal hematoma as a presentation of parahemophilia. *J Neurosci Rural Pract* 2013;4:240-2.

How to cite this article: Sharma R, Raj R, Gupta LN. Massive hemopericranium following trivial trauma in a child with hypofibrinogenemia: A case report and review of the literature. *Indian J Neurosurg* 2014;3:166-8.

Source of Support: Nil, **Conflict of Interest:** None declared.

New features on the journal's website


Optimized content for mobile and hand-held devices

HTML pages have been optimized of mobile and other hand-held devices (such as iPad, Kindle, iPod) for faster browsing speed. Click on **[Mobile Full text]** from Table of Contents page. This is simple HTML version for faster download on mobiles (if viewed on desktop, it will be automatically redirected to full HTML version)

E-Pub for hand-held devices

EPUB is an open e-book standard recommended by The International Digital Publishing Forum which is designed for reflowable content i.e. the text display can be optimized for a particular display device. Click on **[EPub]** from Table of Contents page. There are various e-Pub readers such as for Windows: Digital Editions, OS X: Calibre/Bookworm, iPhone/iPod Touch/iPad: Stanza, and Linux: Calibre/Bookworm.

E-Book for desktop

One can also see the entire issue as printed here in a 'flip book' version on desktops. Links are available from Current Issue as well as Archives pages. Click on  View as eBook