

Giant intracranial osteochondroma: A case report with review of literature

R. Amita, S. Sandhyamani, H. V. Easwer¹, Suresh Nair¹, A. Praveen², T. R. Kapilamoorthy²

Departments of Pathology, ¹Neurosurgery and ²Imaging Sciences and Interventional Radiology, Sree Chitra Tirunal Institute for Medical Sciences and Technology, Thiruvananthapuram, Kerala, India

ABSTRACT

Osteochondromas are rare tumors of skull and commonest site of intracranial involvement is skull base. Complete excision is usually curative. We report a case of giant osteochondroma of the fronto-sylvian, which we believe is the largest reported intracranial osteochondroma until date.

Key words: Intracranial, largest, osteochondroma

INTRODUCTION

Intracranial osteochondromas are very rare and represent 0.1–0.2% of all intracranial tumors.^[1] Base of skull is the most common site. Complete excision is usually curative. We report a case of giant osteochondroma of the fronto-sylvian region, which we believe is the largest reported intracranial osteochondroma until date.

CASE REPORT

A 17-year-old male with no comorbid illness presented with two episodes of generalised tonic-clonic seizures. He was started on antiepileptic drugs, but the seizure persisted. Meanwhile, he noticed progressive deviation of the angle of mouth toward right side over a period of 4–5 months, associated with holocranial headache and vomiting. On examination, he was conscious, alert with stable vitals. Except for the deviation of the angle of mouth to the right, there were no other neurological deficits. Systemic examination and blood investigations were normal. Magnetic resonance imaging (MRI) brain showed a large extra axial lobulated T1 hypointense lesion with multiple hyperintense areas [Figure 1a] suppressing on fat suppression, in the right fronto-sylvian

region. Computed tomography (CT) brain showed dense calcifications within the lesion [Figure 1b]. The lesion was broad based at inner skull vault and dura. The radiological differentials were between osteochondroma and a calcified meningioma. Right fronto-parietal craniotomy and Grade I excision of the lesion was done as shown [Figure 1c]. Postoperative period was uneventful. We received a hard nodular translucent mass measuring 7.1 cm × 7 cm × 4 cm [Figure 2a] and weighed 161.5 g with attached dura. Cut section showed a cartilaginous cap measuring 1–1.5 cm with underlying hard bone. Microscopy showed cartilaginous cap composed of lobules of mature cartilage containing chondrocytes within lacunar spaces, which merged into strands of mature bone containing marrow fat and cellular elements [Figure 2b]. There were no areas of necrosis, cellular pleomorphism, nuclear atypia, or binucleate chondrocytes. The diagnosis of osteochondroma was given.

The patient is doing well at follow-up after 3 months.

DISCUSSION

Osteochondromas are the most common benign bone tumors.^[2] They most commonly arise from the metaphyseal end of long bones, though any part of the skeletal system may be affected. Head and neck is an uncommon site, with only isolated case reports. Intracranial osteochondromas are still rare, the majority being from the base of the skull.^[3,4] There are only exceptional case reports^[1] of osteochondroma arising from the dura as in our case. The size of the tumor also makes our case unique. This we believe is the largest

Access this article online	
Quick Response Code:	Website: www.ijns.in
	DOI: 10.4103/2277-9167.146836

Address for correspondence: Dr. S. Sandhyamani,
Department of Pathology, Sree Chitra Tirunal Institute for Medical Sciences and Technology, Thiruvananthapuram - 695 011, Kerala, India.
E-mail: sandhyamani@gmail.com

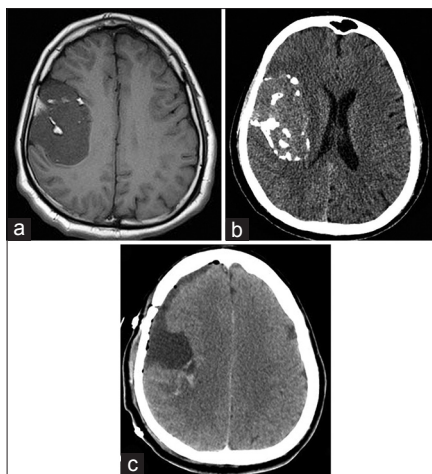


Figure 1: (a) Magnetic resonance imaging brain shows a large well defined lobulated extra axial lesion in right fronto-sylvian region with broad base to inner skull vault and dura. (b) Dense calcification seen in computed tomography. (c) Post-operative CT image showing grade I excision

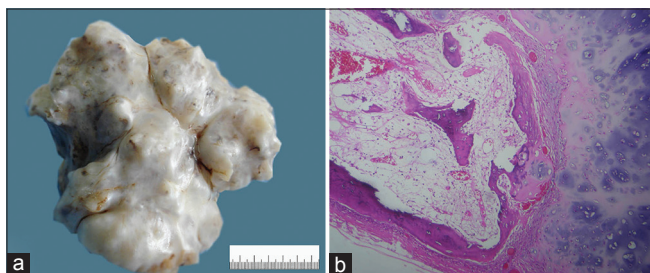


Figure 2: (a) Hard irregular nodular translucent mass. (b) Hyaline cartilaginous cap and strands of mature bone containing marrow fat and cellular elements (H and E, x100)

reported case of osteochondroma within the cranium till date.

The herniation of epiphyseal cartilage through a defect in the periosteal cuff of bone, (normally present in the region of the growth plate) is thought to develop into an osteochondroma in later life.^[2] Osteochondromas of the skull are hypothesized to occur when cartilaginous rests are trapped within ossifying suture lines; hence the middle cranial fossa where so many sutures converge is the commonest site for these.^[1]

X-ray images showing a sessile or pedunculated lesion located near to the joint is usually sufficient to diagnose osteochondromas. CT helps in determining if the marrow and cortices of the lesion are continuous with the bone. The thickness of the cartilage cap seen in MRI

helps in determining the risk of malignant transformation. Cartilage cap thickness >1.5–2 cm is indicative of malignant change.^[2]

Differential diagnosis includes chondroma, osteoma, chondrosarcoma, osteosarcoma, fibrous dysplasia, giant-cell tumor, and metastatic tumors.

The main histological differential diagnosis is low-grade chondrosarcoma, which shows cellular pleomorphism, nuclear atypia, and binucleate chondrocytes. Radiological correlation for the thickness of the cartilage cap is also helpful.

Osteochondromas are usually solitary but may occur as part of generalized hereditary multiple exostoses syndrome, which is an autosomal dominant condition. Complete surgical excision is curative. Transition to chondrosarcoma is rare.^[1]

In our case, the tumor was completely resected en mass and patient was relieved of all the symptoms. Follow-up of the patient with clinical examination and imaging studies showed no evidence of any recurrence.

CONCLUSION

We report a rare case of intracranial giant osteochondroma, which we believe is the largest reported case of an intracranial osteochondroma till date.

REFERENCES

1. Venkata RI, Kakarala SV, Garikaparathi S, Duttaluru SS, Parvatata A, Chinnam A. Giant intracranial osteochondroma: A case report and review of the literature. *Surg Neurol Int* 2011;2:118.
2. Padhya TA, Athavale SM, Kathju S, Sarkar S, Mehta AR. Osteochondroma of the skull base. *Otolaryngol Head Neck Surg* 2007;137:166-8.
3. Lin WC, Lirng JF, Ho DM, Chang FC, Shing-Su C, Luo CB, et al. A rare giant intracranial osteochondroma. *Zhonghua Yi Xue Za Zhi (Taipei)* 2002;65:235-8.
4. Bonde V, Srikant B, Goel A. Osteochondroma of basi-occiput. *Neuro India* 2007;55:182-3.

How to cite this article: Amita R, Sandhyamani S, Easwer HV, Nair S, Praveen A, Kapilamoorthy TR. Giant intracranial osteochondroma: A case report with review of literature. *Indian J Neurosurg* 2014;3:169-70.

Source of Support: Nil, **Conflict of Interest:** None declared.