Article published online: 2020-12-31

Relationship of angiogenic and apoptotic activities in soft-tissue sarcoma

Thin Thin Win, Hasnan Jaafar, Yusri Yusuf[1]

Abstract

Introduction: Angiogenesis and apoptosis play an essential role in tumor development and progression. Previous studies on apoptosis and angiogenesis of soft-tissue sarcoma (STS) were done separately. This is the first study of the relationship between apoptotic and angiogenic activity. Correlation of expression of anti-apoptotic protein (Bcl-2) and pro-apoptotic protein (Bax) in the tumor cells (TCs) with their expression in endothelial cell (EC) of the tumor blood vessels in STS were also carried out. **Materials and Methods:** 101 cases of STS; consisting liposarcoma, malignant fibrous histiocytoma, synovial sarcoma, fibrosarcoma, leiomyosarcoma, rhabdomyosarcoma and malignant peripheral nerve sheath tumor; were collected and immunohistochemical reaction of vascular endothelial growth factor (VEGF), Bcl-2 and Bax were examined. **Results:** Higher Bax expression in TCs (54.5%) was seen compared to Bcl-2 expression (44.6%). There was a significant association between Bcl-2 and Bax in TCs with ECs. Significant association was also seen between histological types of STS with Bcl-2 expression; however not with Bax expression. There was an association between VEGF and Bax with high VEGF expression and weak Bax expression. However, VEGF expression was not associated with Bcl-2 expression and histological types. **Conclusion:** This study supports the role of ECs of tumor blood vessels and apoptosis of TCs in tumor management. Increased angiogenesis may inhibit apoptosis of TCs and lead to tumor growth. Therefore, inhibition of ECs survival or activation of ECs death is promising prospect for tumor therapy. Immunohistochemical antibodies in this study might be potential useful marker for the prognosis of STS.

Key words: Angiogenesis, apoptosis, Bax, Bcl-2, soft-tissue sarcoma, vascular endothelial growth factor

Introduction

Soft-tissue sarcomas (STS) are a heterogenous group of tumors arising from mesenchymal tissue. Despite the relative rarity (less than 1% of all malignant tumors), incidence and mortality are increasing with a significant diagnostic and therapeutic challenges.

Angiogenesis and apoptosis play a critical role in tumor growth and progression. Neovascularization is an important process in tumor cell (TC) proliferation and also influences TC dissemination.[1] Apoptosis of the TCs and endothelial cells (ECs) of tumor blood vessels also play a role in TC survival and TC death. Studies on apoptotic and angiogenic activities of TCs in STS have been done separately,[2-4] however no study has been done on the expression of apoptotic markers in ECs. This study aimed to analyze the apoptotic and angiogenic activities in TCs and ECs of tumor blood vessels; and study their association in STS. Apoptotic and angiogenic activities were studied by using immunohistochemical markers. Meanwhile, the correlation of apoptotic activities in TCs and ECs of blood vessels that supply the tumour were also carried out. Background hypothesis of this study was that increased apoptosis of TCs and ECs of tumor blood vessels lead to TC death and regression of the tumor.

Materials and Methods

101 cases of STS which include liposarcoma, malignant fibrous histiocytoma (MFH), synovial sarcoma, fibrosarcoma, rhabdomyosarcoma, leiomyosarcoma (LMS) and malignant peripheral nerve sheath tumor (MPNST) were included in this study. Formalin-fixed paraffin-embedded tissue blocks of the resected specimens of STS without prior chemotherapy were collected from Pathology Department, Hospital Universiti Sains Malaysia. The study was funded under USM Short Term Grant and it was approved by board of research and ethical committee of School of Medical Sciences, Universiti Sains Malaysia.

Access this article online
Quick Response Code:
Website: www.sajc.org
DOI: 10.4103/2278-330X.136799

Department of Pathology, School of Medical Sciences, Universiti Sains Malaysia, 16150 Kubang Kerian, Kelantan, [1]Hospital Umum Sarawak, Jalan Hospital, 93586 Kuching, Sarawak, Malaysia
Correspondence to: Dr. Thin Thin Win,
E-mail: safiya@kb.usm.my

Immunohistochemistry

Paraffin-embedded tissue blocks were sectioned into 3-4 μm thickness, placed on poly-L-Lysine slides. After deparaffinization, antigen retrieval was carried out. Monoclonal mouse anti-human Bcl-2 (DAKO, Denmark), monoclonal rabbit antiserum of Bax (DAKO, Denmark) and rabbit polyclonal anti-human VEGF (Santa Cruz biotechnology) were used as primary antibodies. For secondary antibody and detection system, horseradish peroxidase polymer solution, buffered solution containing hydrogen peroxide and detector agent of di-amino benzidine were used. All slides were analyzed under microscope (Olympus C × 31) with × 400 magnification.

The scoring for expression of Bcl-2 and Bax was carried out based on combined score of qualitative and quantitative analysis. The intensity (qualitative) of the Bcl-2 and Bax immunostaining was evaluated by dividing the cytoplasmic staining reactions in four score groups: 1 = Weak cytoplasmic staining intensity; 2 = Moderate cytoplasmic staining intensity; 3 = Strong cytoplasmic staining intensity; and 4 = Very strong cytoplasmic staining intensity. The immunostaining was quantified from a total of 100 cells as follows: 0 = No positive staining; 1= <25% of TCs or vessels show cytoplasmic staining positivity; 2 = 25-50% of TCs or vessels show cytoplasmic reactivity; 3 = 50-75% of TCs or vessels showing cytoplasmic reactivity; 4= >75% of TCs or vessels showing cytoplasmic reactivity. A combined score for Bcl-2 and Bax immunostaining was obtained by adding the qualitative and quantitative score; these sums were then divided in three main groups: score = 0, no immunoreactivity; score = 1-4, weak immunoreactivity; and score = 5-8, strong immunoreactivity.[5] To simplify, the results were condensed into two categories only. Negative indicates no immunoreactivity and positive indicates weak and strong immunoreactivity.

The expression of VEGF was assessed based on the percentage of immunoreactive cells in total 1000 cells. Immunoreactivity was graded as follows; more than 10% of the cells staining graded as positive or unequivocal red staining in the TC cytoplasm; and less than 10% of cells staining or no detectable staining graded as negative.[6] Qualitative intensity of staining for VEGF was assessed using a scale between 0 and 3+, with 0 representing no detectable stain, 1 + as weak, 2 + intermediate or moderate and 3 + representing strongest stain. For analyses,

VEGF expression was assigned "negative" with a score of 0 and "positive" with a score of 1+ to 3+.

Statistical analysis

All the results were analyzed by using SPSS Inc. PASW Statistics for Windows, Version 18.0. Chicago, Released 2009. Association between expression of Bcl-2 and Bax in TCs with their expression in ECs were analyzed by using Mc-Nemar test. Association between expression of Bcl-2 and Bax in TCs with VEGF in TCs were analyzed by using Pearson's Chi-square test. Association between expression of Bcl-2, Bax and VEGF in TC with histological types was analyzed by using Fisher exact test. $P < 0.001$ was considered to be statistically significant.

Results

Bcl-2, Bax, VEGF expression in TCs and ECs

Bcl-2 expression in TCs was more than Bcl-2 in ECs. Among the positive Bcl-2 cases in TCs, 27.8% showed strong expression and 16.8% showed weak expression; whereas only 7.9% showed strong expression with 26% weak expression in ECs. As in expression of Bcl-2, the expression of Bax in TCs was stronger than in ECs. The positive staining were 54.4% and 48.5% in tumor and ECs respectively. Majority of the positive cases in both groups showed weak immunoreactivity. Both Bcl-2 and Bax in TCs were directly associated with both expression in ECs ($P < 0.001$) as shown in Table 1.

VEGF expression was done only in TCs as ECs served as internal positive control and comparison was not done between TCs and ECs. In TCs, 68.3% showed positivity with 54.5% of strong immunoreactivity. Positive immunoreactivities of Bcl-2, Bax and VEGF appear as cytoplasmic staining in tumour cells and in endothelial cells [Figure 1a and b].

Association between VEGF expression with Bcl-2 and Bax expression in TCs

There was no significant association between expression of VEGF and expression of Bcl-2 in TCs. However, significant association between VEGF and Bax expression in TCs was seen. More cases (30.7%) revealed weak or no Bax expression with high VEGF expression compared to only 23.8% of strong Bax expression with high VEGF expression. Results are summarized in Table 2.

Association between expression of Bcl-2, Bax and VEGF in TCs with histological types

The histological types of the STS showed a significant correlation with expressions of Bcl-2 in TCs [Table 3]. The Bcl-2 expression was very high in synovial sarcoma (100%) and LMS (71.4%); whereas liposarcoma, MFH and MPNST showed <40% of positive cases. There was also no association between expression of both Bax and VEGF with histological types of STS.

Discussion

Expression of Bcl-2 and Bax

In the development and progression of malignant tumor, two most important apoptosis regulating proteins are Bcl-2 and Bax. Both are functionally antagonistic proteins, which control apoptosis. To the best of our knowledge, this is the first attempt to study the expression of Bcl-2 and Bax in TCs of STS comparing with expression of both in ECs of the tumor blood vessels.

In this study, apoptotic activity was higher in the TCs compared to anti-apoptotic activity, which is consistent with the findings reported by Sabah *et al*.[2] Unlike Bcl-2 expression; many studies have not been done to evaluate the expression of Bax in STS by immunohistochemistry. Only few studies revealed Bax expression was a common finding in STS.[2,7] Bcl-2 and Bax are expressed differently in various tissue and cells populations and may respond differently to apoptotic stimuli.[8] Bcl-2 is expressed mostly in the peripheral proliferating tumor areas and decreased in the areas of cell death. However, Bax is highly expressed in the periphery (close to stroma) and remain unchanged or even increased in the areas of cell death.[9] This study showed slight higher expression of Bax compared to Bcl-2, as most of the cases were high-grade tumor with necrosis. It is supported by some research findings which showed a strong association between Bax and Bcl-2 expression; and a trend for high-grade tumors being more frequently Bax-positive.[10]

Association of the expression of Bcl-2 and Bax in TCs and in ECs

This study showed both expression of Bcl-2 and Bax were directly associated between TCs and ECs ($P < 0.001$). No report was seen in literatures on association between the expression of Bcl-2 and Bax in TCs with the ECs.

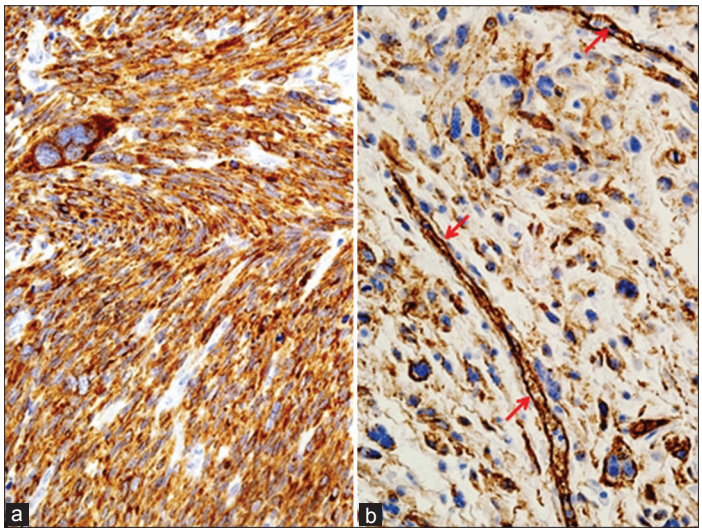

Figure 1: Positive immunoreactivities of Bcl-2, Bax and VEGF appear as cytoplasmic staining in tumour cells (a) and in endothelial cells (b)

Table 1: Association of Bcl-2 and Bax in tumour cells (TC) with Bcl-2 and Bax in endothelial cells

Variable	Bcl-2 (TC)		*P* value[c]	Variable	Bax (TC)		*P* value[c]
	Negative Freq (%)	Positive Freq (%)			Negative Freq (%)	Positive Freq (%)	
	Bcl-2 (EC)				Bax-2 (EC)		
Negative	56(55.4)	11(10.9)	<0.001	Negative	46(45.5)	6(5.9)	<0.001
Positive	0(0.0)	34(33.7)		Positive	0(0.0)	49(48.5)	

[c]Mc-Nemar test

Table 2: Association of Bcl-2 and Bax in tumour cells (TC) with VEGF in tumour cells (TC)

VEGF (TC)	Bcl-2 (TC)			*P* value[c]	Bax (TC)			*P* value[c]
	No	Weak	Strong		No	Weak	Strong	
No	29 (28.7%)	3 (3.0%)	0 (0%)		29 (28.7%)	3 (3.0%)	0 (0%)	
Weak	6 (5.9%)	3 (3.0%)	5 (5.0%)		10 (9.9%)	1 (1.0%)	3 (3.0%)	
High	21 (20.8%)	11 (10.9%)	23 (22.8%)		7 (6.9%)	24 (23.8%)	24 (23.8%)	

[c]Peason's Chi-square test

Table 3: Association between expression of Bcl-2, Bax, and VEGF in tumour cells (TC) with histological types

Types	Bcl-2 in TC		*P* value[d]	Bax in TC		*P* value[d]	VEGF in TC		*P* value[d]
	-ve Freq,%	+ve Freq,%		-ve Freq,%	+ve Freq,%		-ve Freq%	+ve Freq,%	
LPS	25(69.4)	11(30.6)		17(47.2)	19(52.8)		17(36.1)	19(63.9)	
MFH	13(65.0)	7(35.0)		8(40.0)	12(60.0)		8(35.0)	12(65.0)	
SS	0(0.0)	6(100.0)		0(0.0)	6(100.0)		0(0.0)	6(100.0)	
FS	4(44.4)	5(55.6)	0.009	4(44.4)	5(55.6)	0.250	4(22.2)	5(77.8)	0.099
RMS	5(55.6)	4(44.4)		5(55.6)	4(44.4)		5(33.3)	4(66.7)	
LMS	4(28.6)	10(71.4)		7(50.0)	7(50.0)		7(14.3)	7(85.7)	
MPNST	5(71.4)	2(28.6)		5(71.4)	2(28.6)		5(71.4)	2(28.6)	

[d]Fisher Exact Test (LPS: Liposarcoma; MFH: Malignant fibrous histocytoma; SS: Synovial sarcoma; FS: Fibrosarcoma; RMS: Rhabdomyosarcoma; LMS: Leiomyosarcoma; MPNST: Malignant peripheral nerve sheath tumour)

Apoptosis in ECs may play an important role in the biology of tumor blood vessels, as the survival of the ECs within the tumor stroma influences the survival of the TCs themselves. ECs isolated from tumor vessels are known to be more resistant to apoptosis than ECs isolated from vessels of corresponding normal tissues.[11] It supported our findings, which is a direct association of Bcl-2 expressions in TCs with Bcl-2 expression in ECs. Based on these results, the inhibition of endothelial survival factors or the activation of ECs death is an attractive anti-tumor strategy, especially when used to supplement strategies directed at the TCs themselves.[12] Several anti-angiogenic agents in clinical trials for cancer treatment appear to exert anti-tumor action by promoting ECs apoptosis.

The apoptosis in ECs may be the triggering factor that selectively causes an increased apoptosis in TCs. This might be the reason for our findings that the higher the expression of Bax, the higher apoptotic activity.

Association between the expression of Bcl-2, Bax and VEGF in TCs with histological types

The significant association was seen between the expressions of Bcl-2 in TCs with histologic types. In this study, the expression of Bcl-2 and Bax were 100% in synovial sarcoma. Bcl-2 expression was also commonly seen in LMS (71.4%) and fibrosarcoma (55.6%) whereas Bax expression was seen in MFH (60%), fibrosarcoma (55.6%), liposarcoma (52.8%) and LMS (50.0%). The other histologic subtypes were expressed less than 50% of Bcl-2 and Bax protein. These findings were consistent with previous report by Sabah *et al*.[2] No association was seen between Bax and VEGF expression with histological types in this study.

Expression of VEGF and its association with the expression of Bcl-2 and Bax in TCs

Angiogenesis has been shown to play a key role in the maintenance, growth and metastasis of many solid tumors.[13] Most solid tumors secrete and overexpress VEGF, which is one of the potent activators of angiogenesis. In this study, VEGF expression was seen in 69 cases (68.3%) with strong positivity which was almost consistent with findings by Chao *et al.*[3] Interestingly, diversity was seen in VEGF expression among the various histologic types of STS. In this study, all histological types showed >60% of VEGF expression with 100% for synovial sarcoma and 85.7% for LMS.

Association between angiogenesis and apoptosis is expected in human solid tumors. Because angiogenesis inhibitors can induce and sustain the dormancy of experimental primary tumors and micro-metastases by elevating the incidence of apoptosis in TCs, while the proliferation rate remains unchanged.[14] Incidence of spontaneous apoptosis in TCs is also inversely related to the extent of neovascularization.[15] In a study on colorectal carcinoma, colorectal carcinogenesis is related to the inhibition of apoptosis and proliferative activity.[16] VEGF is also able to induce Bcl-2 expression in ECs of human umbilical vein; which provide an important role of Bcl-2 in VEGF induced cell survival.[17]

This study hypothesized that VEGF expression was higher in association with strong Bcl-2 expression and weak Bax expression. There were no previous published literatures which indicate the association of Bcl-2 and Bax expression with VEGF expression particularly in STS. It showed significant association between VEGF expressions with Bax expression; but no significant association with Bcl-2 expression. It was also able to find that high VEGF expression was correlated with weak Bax expression in TCs. It was evidenced by more cases (30.7%) showing no or weak Bcl-2 expression compared to only 23.8% of strong Bcl-2 expression with high VEGF expression.

Conclusion

Angiogenic and apoptotic activity plays a pivotal role in the development and progression of STS. Findings in this study support the role of ECs of tumor blood vessels and apoptosis of TCs in tumor management. Increased angiogenesis may inhibit apoptosis of TCs and lead to tumor growth. Therefore, inhibition of ECs survival or activation of ECs death is promising prospect for tumor therapy. Immunohistochemical antibodies in this study might be potential useful marker for the prognosis of STS.

Acknowledgments

This study was funded under Universiti Sains Malaysia Short Term Grant (No: 304/PPSP/6139055).

References

1. Kumar V, Abbas AK, Fausto N, Aster JC. Robbins and Cotran Pathologic Basis of Disease. 8th ed. Philadelphia: Elsevier Saunders; 2010. p. 295-6.
2. Sabah M, Cummins R, Leader M, Kay E. Immunoreactivity of p53, Mdm2, p21(WAF1/CIP1) Bcl-2, and Bax in soft tissue sarcomas: Correlation with histologic grade. Appl Immunohistochem Mol Morphol 2007;15:64-9.
3. Chao C, Al-Saleem T, Brooks JJ, Rogatko A, Kraybill WG, Eisenberg B. Vascular endothelial growth factor and soft tissue sarcomas: Tumor expression correlates with grade. Ann Surg Oncol 2001;8:260-7.
4. Potti A, Ganti AK, Tendulkar K, Sholes K, Chitajallu S, Koch M, *et al*. Determination of vascular endothelial growth factor (VEGF) overexpression in soft tissue sarcomas and the role of overexpression in leiomyosarcoma. J Cancer Res Clin Oncol 2004;130:52-6.
5. Vakkala M, Lähteenmäki K, Raunio H, Pääkkö P, Soini Y. Apoptosis during breast carcinoma progression. Clin Cancer Res 1999;5:319-24.
6. Borre M, Nerstrøm B, Overgaard J. Association between immunohistochemical expression of vascular endothelial growth factor (VEGF), VEGF-expressing neuroendocrine-differentiated tumor cells, and outcome in prostate cancer patients subjected to watchful waiting. Clin Cancer Res 2000;6:1882-90.
7. Dan'ura T, Kawai A, Morimoto Y, Naito N, Yoshida A, Inoue H. Apoptosis and expression of its regulatory proteins in soft tissue sarcomas. Cancer Lett 2002;178:167-74.
8. Yang E, Zha J, Jockel J, Boise LH, Thompson CB, Korsmeyer SJ. Bad, a heterodimeric partner for Bcl-XL and Bcl-2, displaces Bax and promotes cell death. Cell 1995;80:285-91.
9. Shilkaitis A, Graves J, Mehta RR, Hu L, You M, Lubet R, *et al*. Bcl-2 and Bax are differentially expressed in hyperplastic, premalignant, and malignant lesions of mammary carcinogenesis. Cell Growth Differ 2000;11:437-45.
10. Veronese S, Mauri FA, Caffo O, Scaioli M, Aldovini D, Perrone G, *et al*. Bax immunohistochemical expression in breast carcinoma: A study with long term follow-up. Int J Cancer 1998;79:13-8.
11. Benjamin LE, Golijanin D, Itin A, Pode D, Keshet E. Selective ablation of immature blood vessels in established human tumors follows vascular endothelial growth factor withdrawal. J Clin Invest 1999;103:159-65.
12. Nair S, Boczkowski D, Moeller B, Dewhirst M, Vieweg J, Gilboa E. Synergy between tumor immunotherapy and antiangiogenic therapy. Blood 2003;102:964-71.
13. Weidner N, Folkman J, Pozza F, Bevilacqua P, Allred EN, Moore DH, *et al*. Tumor angiogenesis: A new significant and independent prognostic indicator in early-stage breast carcinoma. J Natl Cancer Inst 1992;84:1875-87.
14. Ueda M, Ueki K, Kumagai K, Terai Y, Okamoto Y, Ueki M, *et al*. Apoptosis and tumor angiogenesis in cervical cancer after preoperative chemotherapy. Cancer Res 1998;58:2343-6.
15. Lu C, Tanigawa N. Spontaneous apoptosis is inversely related to intratumoral microvessel density in gastric carcinoma. Cancer Res 1997;57:221-4.
16. Tsujitani S, Shirai H, Tatebe S, Sugamura K, Ohfuji S, Gomyo Y, *et al*. Apoptotic cell death and its relationship to carcinogenesis in colorectal carcinoma. Cancer 1996;77:1711-6.
17. Gerber HP, Dixit V, Ferrara N. Vascular endothelial growth factor induces expression of the antiapoptotic proteins Bcl-2 and A1 in vascular endothelial cells. J Biol Chem 1998;273:13313-6.

How to cite this article: Win TT, Jaafar H, Yusuf Y. Relationship of angiogenic and apoptotic activities in soft-tissue sarcoma. South Asian J Cancer 2014;3:171-4.

Source of Support: This study was funded under Universiti Sains Malaysia Short Term Grant (No: 304/PPSP/6139055). **Conflict of Interest:** None declared.

Announcements

32nd ICON Meeting 2014
Patna, Bihar
For further details please contact:
Dr. Khurshid Mistry
Email: khurshid.mistry@oncologyindia.org

News

FHNO 2014 - (Sept 25th - 28th 2014, JW Marriott, Chandigarh)
INDIAN HEAD NECK CANCER CONGRESS
www.fhno.org, www.fhno2014.com
Abstract submission closes July 31st.
Submit your Abstract to the largest annual gathering of Head - Neck Oncologists in the subcontinent
Present your Academic work at this multidisciplinary meeting
Submission are invited at : http://www.fhno2014.com/abstracts.html

Author Help: Reference checking facility

The manuscript system (www.journalonweb.com) allows the authors to check and verify the accuracy and style of references. The tool checks the references with PubMed as per a predefined style. Authors are encouraged to use this facility, before submitting articles to the journal.

- The style as well as bibliographic elements should be 100% accurate, to help get the references verified from the system. Even a single spelling error or addition of issue number/month of publication will lead to an error when verifying the reference.
- Example of a correct style
  Sheahan P, O'leary G, Lee G, Fitzgibbon J. Cystic cervical metastases: Incidence and diagnosis using fine needle aspiration biopsy. Otolaryngol Head Neck Surg 2002;127:294-8.
- Only the references from journals indexed in PubMed will be checked.
- Enter each reference in new line, without a serial number.
- Add up to a maximum of 15 references at a time.
- If the reference is correct for its bibliographic elements and punctuations, it will be shown as CORRECT and a link to the correct article in PubMed will be given.
- If any of the bibliographic elements are missing, incorrect or extra (such as issue number), it will be shown as INCORRECT and link to possible articles in PubMed will be given.