Article published online: 2020-12-31

Giant anterior ameloblastoma managed by wide excision mandibulectomy with intraoral primary mucosal closure and skin defect coverage by deltopectoral flap

DOI: 10.4103/2278-330X.136815

Dear Editor,

Odontogenic tumors comprise a complex group of lesions of diverse histopathological types and clinical behavior. Of all swellings of the oral cavity, 9% are odontogenic tumors and within this group, ameloblastoma accounts for 1% of lesions.[2] We report a case of giant anterior acanthotic variety of ameloblastoma in a 38-year-old male managed by surgery.

A 38-year-old patient came with the complain of gradually progressive painless swelling on lower jaw for 12 years [Figure 1]. There were skin ulcerations present over the swelling on the inferior aspect. A computed tomography (CT) scan with three-dimensional (3D) reconstruction was done, which showed multicystic expanding lesion 13 × 13 × 12 cm in size involving both the horizontal rami and central arch of mandible, with a typical "soap bubble" presentation. A trucut biopsy was consistent with ameloblastoma. Wide local excision of the tumor encompassing the part of both the ascending rami, horizontal rami, and the central arch was done. Primary intraoral mucosal closure was done. The external skin defect was covered by deltopectoral flap [Figure 2]. The deltopectoral flap was cut on the 22nd postoperative day, and patient was discharged on 30th postoperative day without any complications.

The average age of patients with ameloblastoma is 36 years. In developing countries, ameloblastomas occur in younger patients. Men and women are equally affected. The tumors appear to be larger in females. The ratio of ameloblastoma of the mandible to maxilla is five to one. Ameloblastomas of the mandible occur 12 years earlier than those of the maxilla. Ameloblastomas occur most frequently in the molar region of the mandible.[2] They are occasionally associated with unerupted third molar teeth.[1] The six different histopathological variants of ameloblastoma are desmoplastic, granular cell, basal cell, plexiform, follicular, and acanthomatous.[3] The acanthomatous variant is extremely rare.[4]

This study reports a case of giant acanthotic ameloblastoma that developed at the anterior mandible of a 38-year-old male. The term "giant" or "extreme" ameloblastoma is reserved for lesions that are truly large and that cause gross asymmetry and regional dysfunction. Patients with extreme ameloblastomas are usually from rural areas of developing countries who delay the treatment due to fear of surgery.[5]

Till date, there have been 11 reported cases of extreme ameloblastoma [Table 1]. The maximum size measured was 17 × 15 × 13 cm reported by Acharya *et al.*,[5] whereas present case measured 15 × 14 × 15 cm. All reports were of large tumors involving half of the mandible, and histological diagnosis in these 11 cases was either follicular or plexiform type of ameloblastoma.[5] We report a case of acanthotic type of ameloblastoma, which is a rare entity.

Table 1: A review of clinical features, tumor size, and histopathological type of giant ameloblastomas that were previously reported and the present case

Year	Age	Sex	Tumor size	Histopathological type
1977	57	M	Mental region to ramus of mandible	Follicular ameloblastoma
1977	62	F	Right wisdom tooth to left first premolar tooth region	Plexiform ameloblastoma
1985	30	F	15×14×12 cm	Plexiform ameloblastoma
1990	33	M	Right cuspid tooth to left mandibular condyle	Follicular ameloblastoma
1991	39	F	11×10×6 cm	Plexiform ameloblastoma
1995	73	M	11×11×14 cm	Plexiform ameloblastoma
1997	62	F	17×15×13 cm	Plexiform ameloblastoma
1999	53	F	15.2×11.4×12 cm	Plexiform ameloblastoma
2005	53	M	14×11×10 cm	Follicular ameloblastoma
2011	35	F	15×12×10 cm	Plexiform ameloblastoma
2013	39	F	12×9 × 10 cm	Granular cell ameloblastoma
2013	38	M	15×14×15 cm	Acanthotic ameloblastoma

M=Male, F=Female

Figure 1: Patient presenting with a mandibular swelling

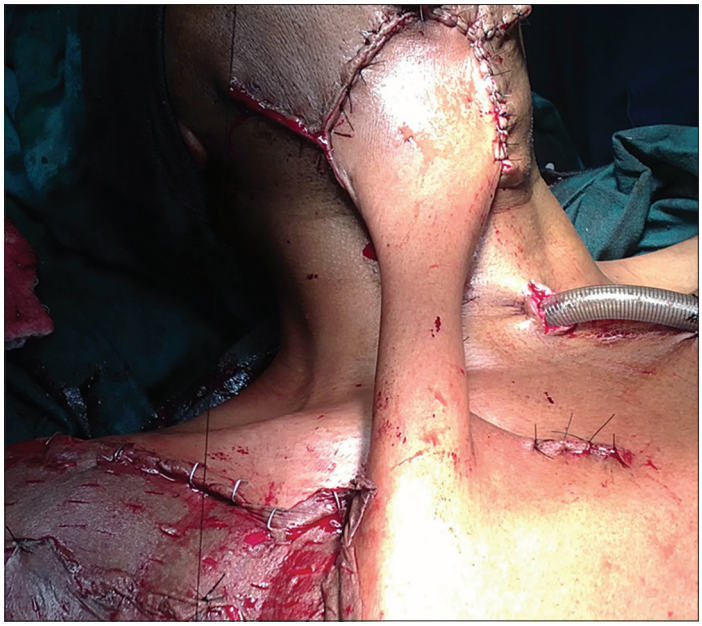

Figure 2: Final appearance after closure and deltopectoral flap placement

Abhishek Jain, Nayan Gupta, Hemant Shukla, Mahavir Tadaiya
Department of Surgical Oncology, Meghjibhai Pethrajbhai Shah Cancer Hospital, Gujarat Cancer and Research Institute, Ahmedabad, Gujarat, India
Correspondence to: Dr. Abhishek Jain,
E-mail: drabhishekonco@hotmail.com

References

1. Ogunsalu C, Daisley H, Henry K, Bedayse S, White K, Jagdeo B, *et al.* A new radiological classification for ameloblastoma based on analysis of 19 cases. West Indian Med J 2006;55:434-9.
2. Reichart PA, Philipsen HP, Sonner S. Ameloblastoma: Biological profile of 3677 cases. Eur J Cancer B Oral Oncol 1995;31B:86-99.
3. Gruica B, Stauffer E, Buser D, Bornstein M. Ameloblastoma of the follicular, plexiform, and acanthomatous type in the maxillary sinus: A case report. Quintessence Int 2003;34:311-4.
4. Walke VA, Munshi MM, Raut WK, Bobahate SK. Cytological diagnosis of acanthmatous ameloblastoma. J Cytol 2008;25:62.
5. Acharya S, Joshi A, Tayaar A, Gopalkrishnan K. Extreme ameloblastoma of the mandible with hypoproteinemia. A case report and review of clinicopathological features. J Clin Exp Dent 2011;3: e343-7.