

# Surgical controversies in the management of post-chemotherapy nonretroperitoneal residual disease in metastatic nonseminomatous germ cell tumors

Durgatosh Pandey<sup>1</sup>, Pankaj Kumar Garg<sup>1,2</sup>, Mukur Dipi Ray<sup>1</sup>, Ashutosh Mishra<sup>1</sup>

## Abstract

Following the advent of platinum-based chemotherapy, Surgery, excepting orchidectomy, has become an adjunct treatment in the management of metastatic non-seminomatous germ cell tumors (NSGCT). Role of surgery comes into play in metastatic NSGCT when residual disease persists following standard chemotherapy. Surgical excision of all post chemotherapy residual disease at all places, whenever surgically feasible with acceptable morbidity and mortality, should be undertaken. As histopathological examination of the excised postchemotherapy residue shows only necrosis and fibrosis in significant number of patients; surgical exercise in this group of patients seems futile and unwarranted retrospectively. This issue becomes more contentious when surgeons are confronted with multiple nonretroperitoneal post chemotherapy residues. This article aims to deal with the management of postchemotherapy nonretroperitoneal residues in metastatic NSGCT.

**Key words:** Germ cell tumors, metastasis, postchemotherapy, surgery

## Introduction

Germ cell tumors (GCTs) constitute 1% of all malignancies in men; however, they are the most common solid tumors in young men between the ages of 20 and 35 years.<sup>[1]</sup> There has been an increase in the incidence of GCTs worldwide; reasons for this upsurge are still open for speculations.<sup>[2]</sup> GCTs are conventionally divided into seminomatous and nonseminomatous GCTs (NSGCTs) because of the distinct epidemiology, natural history, management strategies and prognosis. Significant number of the patients presents with metastatic GCTs, especially in developing countries; however, over the last few decades, there has been remarkable improvement in the survival of these patients owing to the emergence of multimodality treatment. Following the advent of platinum based chemotherapy, surgery, excepting orchidectomy, has become an adjunct treatment in the management of metastatic GCTs. Role of surgery comes into play in metastatic GCTs when residual disease persists following standard chemotherapy and the markers have fallen to normal levels. As outlined earlier, there is difference in the management of seminomatous and NSGCTs. Surgical excision of all post chemotherapy residual disease (PCRD) (size >1 cm) at all places, whenever surgically feasible with acceptable morbidity and mortality, should be undertaken in NSGCTs.<sup>[3]</sup> As histopathological examination of the excised PCRD shows only necrosis and fibrosis in around half of the patients; this casts doubt retrospectively about the decision of surgery considering the high risk of perioperative morbidity and mortality even at high volume centers. There have been many attempts to find ways to predict necrosis in PCRD to avoid surgical excision; however, success is still far from sight. This article is an attempt to provide an algorithmic approach to the management of nonretroperitoneal PCRD in metastatic NSGCTs.

## Magnitude of Problem

Germ cell tumors are the classical example of success of multimodality treatment in solid cancers. The 5-year overall

survival of GCT in 1960s was to tune of 60–70%; the survival improved to more than 95% in 21<sup>st</sup> century. Even in metastatic NSGCT, the 5-year overall survival is 92% in good risk patients and 80% and 48% in intermediate and poor risk patients respectively.<sup>[4]</sup> At present, platinum-based chemotherapy is the standard of care in the primary management of metastatic NSGCT following high inguinal orchidectomy. Post chemotherapy, 30% of the patients has residual disease which may be in retroperitoneum and/or in extra retroperitoneal sites. In a international study involving 238 patients of advanced NSGCT, Fizazi *et al.*<sup>[5]</sup> reported that lungs (27%) and mediastinum (15%) were common extra-retroperitoneal sites; neck (4%), liver (2%) bones (1%) and brain (0.5%) were rare sites of PCRD.

## Rational of Surgical Excision of Nonretroperitoneal Postchemotherapy Residual Disease

Surgical excision of PCRD is the standard of care in metastatic NSGCT if tumor markers levels have fallen to the normal range. The objectives of surgical excision can be three-fold:

- Diagnostic, there are three different histologies seen in the resected residual disease – necrosis/fibrosis, mature teratoma, and residual cancer. No imaging modality has been successful in predicting the histology of the PCRD in NSGCT. Initial optimism with 18-Fluorodeoxyglucose positron emission tomography (FDG-PET) to help differentiate different histologies of PCRD soon waned; Pfannenber *et al.*<sup>[6]</sup> reported up to 40% of false negative rates of FDG-PET in PCRD. FDG-PET was negative in all patients of teratoma; so a negative FDG-PET fails to annihilate the role of surgical excision of PCRD in NSGCT. Presently, expert consensus is that there is no role of FDG-PET in the management of PCRD in NSGCT<sup>[3]</sup>
- Therapeutic, in case of teratoma and cancer – surgical excision of teratoma is warranted as they are chemoresistant and radioresistant, having potential for relentless growth “growing teratoma syndrome” causing compression to adjacent structures and carrying the risk of malignant transformation.<sup>[7-10]</sup> Surgical excision of the viable cancer cells also removes the relatively chemoresistant cancer cells and offers the advantage of additional chemotherapy to the patient<sup>[11,12]</sup>
- The prognostic - presence of residual cancer is a poor prognostic sign and associated with low survival rates as compared to other histologies of necrosis/fibrosis

### Access this article online

#### Quick Response Code:



Website: [www.sajc.org](http://www.sajc.org)

DOI: 10.4103/2278-330X.179702

<sup>1</sup>Department of Surgical Oncology, Dr BRA Institute Research Cancer Hospital, All India Institute of Medical Sciences, <sup>2</sup>Department of Surgery, University College of Medical Sciences and Guru Teg Bahadur Hospital, Delhi, India

**Correspondence to:** Dr. Pankaj Kumar Garg,  
E-mail: [dr.pankajgarg@gmail.com](mailto:dr.pankajgarg@gmail.com)

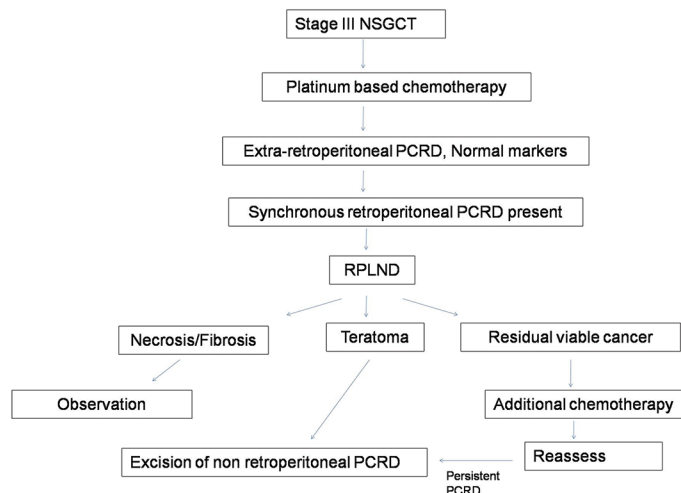
or teratoma.<sup>[2]</sup> In a study of 157 patients of metastatic GCT (153 non-seminomatous and 4 seminomatous) who underwent pulmonary resections for PCRD, Liu *et al.*<sup>[13]</sup> concluded that presence of viable cancer cells in the PCRD is an independent poor prognostic factor – overall 10-year survival of 43% for patients with viable cancer cells compared with 86% and 84% for patients with necrosis/fibrosis and mature teratoma, respectively ( $P = 0.0001$ ).

Though the presence of necrosis/fibrosis at residual sites is a good prognostic sign, it doubts the necessity of the surgery itself retrospectively in the minds of surgeons and patients. All these surgical procedures are highly complex; significant surgery-related morbidity and mortality cannot be denied even at expert hands in high volume centers.

### Approach to nonretroperitoneal postchemotherapy residual disease

Two scenarios can be seen when extra-retroperitoneal PCRD is encountered in metastatic NSGCT – whether synchronous retroperitoneal PCRD is present or not.

The presence of retroperitoneal PCRD provides us the opportunity to predict the likely pathology present at the extra-retroperitoneal site. If retroperitoneal lymph node dissection (RPLND) is done first; three histologies are seen – presence of teratomas, necrosis/fibrosis, and cancer. The first two histologies of RPLND specimen do not pose any confusion as teratoma dictates excision of other nonretroperitoneal PCRD while residual cancer warrants additional chemotherapy followed by reassessment; presence of necrosis in RPLND specimen poses a diagnostic dilemma of observation in the hope that nonretroperitoneal sites also harbor necrosis. In an international multicentric study involving six centers and 215 patients, Steyerberg *et al.*<sup>[14]</sup> addressed this question: They concluded that presence of necrosis at RPLND specimen was associated with 87% and 93% chances of finding the similar pathology at extra-retroperitoneal site in teratomas negative and teratomas positive (at initial orchidectomy specimen) patients respectively. This high concordance of necrosis at RPLND specimen with other extra-retroperitoneal sites inspires confidence to follow an algorithmic approach to the management of extra-retroperitoneal PCRD [Figure 1]. This algorithmic approach gains special significance in the presence of bilateral pulmonary metastasis. The contradictory approach has also been elucidated in the literature based of discordance of retroperitoneal and non-retroperitoneal PCRD histology; the discordance has been highlighted to vary from 25% to 50%.<sup>[15]</sup> However, it needs to be emphasized what concerns us is the probability of finding the worse histology in nonretroperitoneal PCRD as compared to retroperitoneum; merely highlighting the discordance is insufficient in itself.<sup>[16]</sup> Presence of teratoma or residual cancer in retroperitoneum does not worry us about discordance as they always dictate active treatment of nonretroperitoneal PCRD for obvious reasons as stated above; presence of necrosis/fibrosis in retroperitoneum brings in the dilemma as the possibility of worse histology (teratoma or residual cancer) at nonretroperitoneal PCRD needs to be weighed. Moreover, the fact that patient has to be in the close observation in the follow-up period further boosts the philosophy of observation of nonretroperitoneal PCRD following the finding of necrosis/fibrosis in retroperitoneum as the subsequent increase in the size of non-retroperitoneal PCRD



**Figure 1: Algorithmic approach to synchronous retroperitoneal and nonretroperitoneal post chemotherapy residual disease in stage III non seminomatous germ cell tumors**

can be taken care of without affecting the survival of this group of patients. It cannot be overstressed that each clinical scenario is different and so, treatment needs to be tailored to a particular clinical problem based on broad guidelines – retroperitoneal PCRD with limited resectable hepatic PCRD may be approached with simultaneous RPLND and liver resection in a given patient.

Bilateral pulmonary metastasis also poses a significant management dilemma – should both sides be addressed whether simultaneous or staged without histology at one side affecting the decision to address the other side? Kesler *et al.*<sup>[2]</sup> suggested observation policy may be adopted for a contralateral pulmonary PCRD if histology of unilateral pulmonary metastatectomy is detected to be complete necrosis/fibrosis. In a study of 39 cases of bilateral post chemotherapy NSGCT lung metastasis, Besse *et al.*<sup>[17]</sup> reported that there was only 5% discordance in histologic findings between two lungs. More importantly, when necrosis was seen in one lung, 19 out of 20 patients showed necrosis in the contralateral lung.

Patients who have nonpulmonary visceral metastasis are thought to have a poor prognosis.<sup>[18]</sup> Literature pertaining to nonpulmonary PCRD in NSGCT is scarce to draw conclusions; however, the basic tenet remains same that all nonthoracic PCRD should also be excised completely whenever technically possible. In their experience of 57 patients with hepatic metastasis in NSGCT following chemotherapy, operated at Indiana University, Hahn *et al.*<sup>[19]</sup> reported that hepatic resection is safe and efficacious; 89% of patients who had necrosis/fibrosis were alive at median follow-up of 47 months in comparison to 29% patients who had viable cancer. In a study of 37 patients who had hepatic metastatectomy for advanced GCT (35 non-seminomatous and 2 seminomatous GCT), Rivoire *et al.*<sup>[20]</sup> recommended the resection of residual hepatic masses in advanced GCT of 10–29 mm (greatest diameter) in male patients; they highlighted that lesions less than 10 mm were unlikely to harbor histology other than necrosis while patients with lesions more than 30 mm are too high risk to get benefitted from resection. Copson *et al.*<sup>[21]</sup> suggested a “wait and watch” approach to residual hepatic lesions in advanced GCT as: (1) If the residual lesion is necrosis, surgical excision is futile (2) if the residual lesion is viable cancer, surgery is unlikely to improve survival (3) if the residual lesion is teratoma,

salvage surgery is possible when lesion increases in size during observation. Based on these studies, a pragmatic approach would be to resect hepatic PCRD surgically if anticipated perioperative morbidity and mortality is within acceptable range; otherwise these patients can be observed with radiological imaging and salvage surgery may be undertaken for lesions which show increase in size with time. Needless to say, the hepatic disease may also be addressed simultaneously with RPLND provided the perioperative risk be acceptable; need of individualization of treatment based on scientific principles cannot be overstressed.

In a retrospective study of 34 patients with GCT metastatic to the neck who underwent postchemotherapy neck dissection between 1991 and 2009, Mehra *et al.*<sup>[22]</sup> showed no cervical region recurrence after 52 months of median follow-up. In a retrospective review of 45 patients of metastatic NSGCT who underwent 48 unilateral and 3 bilateral neck dissections, Weisberger and McBride<sup>[23]</sup> concluded that surgical resection of neck PCRD leads to surprisingly favorable prognosis. In the study of 9 patients with cervical node dissection for metastatic GCT (6 were post chemotherapy residual and 3 were late relapses), van Vledder *et al.*<sup>[24]</sup> reported no local recurrence with favorable outcome. Based on these studies, it can be concluded neck PCRD can be safely excised with acceptable perioperative risk and favorable oncological outcome.

## Conclusion

Surgery continues to be an integral part of multimodality management of metastatic NSGCT. Surgical excision of PCRD must be contemplated in all patients with a caveat of perioperative morbidity and mortality viz-a-viz oncological outcome.

## References

1. Vasdev N, Moon A, Thorpe AC. Classification, epidemiology and therapies for testicular germ cell tumours. *Int J Dev Biol* 2013;57:133-9.
2. Kesler KA, Kruter LE, Perkins SM, Rieger KM, Sullivan KJ, Runyan ML, *et al.* Survival after resection for metastatic testicular nonseminomatous germ cell cancer to the lung or mediastinum. *Ann Thorac Surg* 2011;91:1085-93.
3. Daneshmand S, Albers P, Fosså SD, Heidenreich A, Kollmannsberger C, Krega S, *et al.* Contemporary management of postchemotherapy testis cancer. *Eur Urol* 2012;62:867-76.
4. Gori S, Porrozzzi S, Roila F, Gatta G, De Giorgi U, Marangolo M. Germ cell tumours of the testis. *Crit Rev Oncol Hematol* 2005;53:141-64.
5. Fizazi K, Tjulandin S, Salvioni R, Germà-Lluch JR, Bouzy J, Ragan D, *et al.* Viable malignant cells after primary chemotherapy for disseminated nonseminomatous germ cell tumors: Prognostic factors and role of postsurgery chemotherapy – Results from an international study group. *J Clin Oncol* 2001;19:2647-57.
6. Pfannenber AC, Oechsle K, Bokemeyer C, Kollmannsberger C, Dohmen BM, Bares R, *et al.* The role of [(18) F] FDG-PET, CT/MRI and tumor marker kinetics in the evaluation of post chemotherapy residual

- masses in metastatic germ cell tumors – Prospects for management. *World J Urol* 2004;22:132-9.
7. Logothetis CJ, Samuels ML, Trindade A, Johnson DE. The growing teratoma syndrome. *Cancer* 1982;50:1629-35.
8. Motzer RJ, Amsterdam A, Prieto V, Sheinfeld J, Murty VV, Mazumdar M, *et al.* Teratoma with malignant transformation: Diverse malignant histologies arising in men with germ cell tumors. *J Urol* 1998;159:133-8.
9. Ahmed T, Bosl GJ, Hajdu SI. Teratoma with malignant transformation in germ cell tumors in men. *Cancer* 1985;56:860-3.
10. Donadio AC, Motzer RJ, Bajorin DF, Kantoff PW, Sheinfeld J, Houldsworth J, *et al.* Chemotherapy for teratoma with malignant transformation. *J Clin Oncol* 2003;21:4285-91.
11. Fox EP, Weathers TD, Williams SD, Loehrer PJ, Ulbright TM, Donohue JP, *et al.* Outcome analysis for patients with persistent nonteratomatous germ cell tumor in postchemotherapy retroperitoneal lymph node dissections. *J Clin Oncol* 1993;11:1294-9.
12. Sim HG, Lange PH, Lin DW. Role of post-chemotherapy surgery in germ cell tumors. *Urol Clin North Am* 2007;34:199-217.
13. Liu D, Abolhoda A, Burt ME, Martini N, Bains MS, Downey RJ, *et al.* Pulmonary metastasectomy for testicular germ cell tumors: A 28-year experience. *Ann Thorac Surg* 1998;66:1709-14.
14. Steyerberg EW, Keizer HJ, Messermer JE, Toner GC, Schraffordt Koops H, Fosså SD, *et al.* Residual pulmonary masses after chemotherapy for metastatic nonseminomatous germ cell tumor. Prediction of histology. ReHiT Study Group. *Cancer* 1997;79:345-55.
15. Katz MH, McKiernan JM. Treatment of nonretroperitoneal residual germ cell tumor masses. *Urol Oncol* 2005;23:431-9.
16. Lin DW, Lange PH. Editorial comment on "Treatment of nonretroperitoneal residual germ cell tumor masses". *Urol Oncol* 2005;23:439-40.
17. Besse B, Grunenwald D, Fléchon A, Caty A, Chevreau C, Culine S, *et al.* Nonseminomatous germ cell tumors: Assessing the need for postchemotherapy contralateral pulmonary resection in patients with ipsilateral complete necrosis. *J Thorac Cardiovasc Surg* 2009;137:448-52.
18. Katz MH, McKiernan JM. Management of non-retroperitoneal residual germ cell tumor masses. *Urol Clin North Am* 2007;34:235-43.
19. Hahn TL, Jacobson L, Einhorn LH, Foster R, Goulet RJ Jr. Hepatic resection of metastatic testicular carcinoma: A further update. *Ann Surg Oncol* 1999;6:640-4.
20. Rivoire M, Elias D, De Cian F, Kaemmerlen P, Théodore C, Droz JP. Multimodality treatment of patients with liver metastases from germ cell tumors: The role of surgery. *Cancer* 2001;92:578-87.
21. Copson E, McKendrick J, Hennessey N, Tung K, Mead GZ. Liver metastases in germ cell cancer: Defining a role for surgery after chemotherapy. *BJU Int* 2004;94:552-8.
22. Mehra S, Liu J, Gupta A, Sheinfeld J, Kraus D. Cervical metastasis of germ cell tumors: Evaluation, management, complications, and outcomes. *Laryngoscope* 2012;122:286-90.
23. Weisberger EC, McBride LC. Modified neck dissection for metastatic nonseminomatous testicular carcinoma. *Laryngoscope* 1999;109:1241-4.
24. van Vledder MG, van der Hage JA, Kirkels WJ, Oosterhuis JW, Verhoef C, de Wilt JH. Cervical lymph node dissection for metastatic testicular cancer. *Ann Surg Oncol* 2010;17:1682-7.

**How to cite this article:** Pandey D, Garg PK, Ray MD, Mishra A. Surgical controversies in the management of post-chemotherapy nonretroperitoneal residual disease in metastatic nonseminomatous germ cell tumors. *South Asian J Cancer* 2016;5:20-2.

**Source of Support:** Nil. **Conflict of Interest:** None declared.