

# Pulpectomy procedures in primary molar teeth

Hany Mohamed Aly Ahmed

Department of Restorative Dentistry, School of Dental Sciences, Universiti Sains Malaysia, Kubang Kerian, 16150, Kelantan, Malaysia

**Address for correspondence:**

Dr. Hany Mohamed Aly Ahmed,  
Department of Restorative Dentistry,  
School of Dental Sciences,  
Universiti Sains Malaysia, Kubang  
Kerian, 16150, Kelantan, Malaysia.  
E-mail: hany\_endodontist@hotmail.com

## ABSTRACT

Premature loss of primary molars can cause a number of undesirable consequences including loss of arch length, insufficient space for erupting premolars and mesial tipping of the permanent molars. Pulpectomy of primary molar teeth is considered as a reasonable treatment approach to ensure either normal shedding or a long-term survival in instances of retention. Despite being a more conservative treatment option than extraction, efficient pulpectomy of bizarre and tortuous root canals encased in roots programmed for physiologic resorption that show close proximity to developing permanent tooth buds presents a critical endodontic challenge. This article aims to provide an overview of this treatment approach, including partial and total pulpectomy, in primary molar teeth. In addition, the recommended guidelines that should be followed, and the current updates that have been developed, while commencing total pulpectomy in primary molars are discussed.

## Key words

Deciduous molars, partial pulpectomy, primary molars, total pulpectomy

## INTRODUCTION

The main objective of pulp therapy in the primary dentition is to retain every primary tooth as a fully functional component in the dental arch to allow for proper mastication, phonation, swallowing, preservation of the space required for eruption of permanent teeth and prevention of detrimental psychological effects due to tooth loss.<sup>[1,2]</sup> To fulfill this major goal, vital pulp therapy through pulpotomy, which refers to surgical removal of the entire coronal inflamed pulp leaving the vital radicular pulp intact within the canals, is the most widely accepted technique for treating primary teeth with irreversible inflammation affecting the pulp chamber. However, in cases of irreversibly inflamed and necrotic radicular canals, a successful pulpotomy cannot be achieved, and a partial or total pulpectomy is indicated.<sup>[1]</sup>

Pulpectomy is a conservative treatment approach to preventing the premature loss of primary teeth that

can result in loss of arch length, insufficient space for erupting permanent teeth, impaction of premolars, and mesial tipping of molar teeth adjacent to the lost primary molar.<sup>[1,3]</sup> In addition, pulpectomy is advantageous for retained primary molar teeth.<sup>[4,5]</sup> If not severed with a progressive root resorption or aligned in a severe infra-occlusion, the retained molar can be a functional component in the dental arch for many years<sup>[6-8]</sup> [Figure 1]. In several instances, an occlusal modification through direct or indirect restoration is ensured for normal alignment or it can be included as an abutment in a fixed bridge.<sup>[9]</sup> If this long-term survival method is not applicable, retaining primary molars until the patient becomes sufficiently mature (17-21 years old) for complete facial growth is one alternative. This technique preserves a sufficient alveolar ridge width and height for future implant treatment (if required).<sup>[10]</sup> Primary molars can also be included in an interdisciplinary treatment approach, either by reducing the mesiodistal width of the crown or hemisection for orthodontic space management.<sup>[10,11]</sup>

Thus, an appropriate pulpectomy of primary molars rather than extraction is a reasonable treatment option to ensure either normal shedding/eruption of the successor or a long-term survival in instances of retention.<sup>[12]</sup> As such, this article provides an overview of this treatment approach, including partial and total pulpectomy, in primary molar teeth. In addition, the recommended guidelines that should be followed, and the current

Access this article online	
Quick Response Code:	Website: www.ejgd.org
	DOI: 10.4103/2278-9626.126201

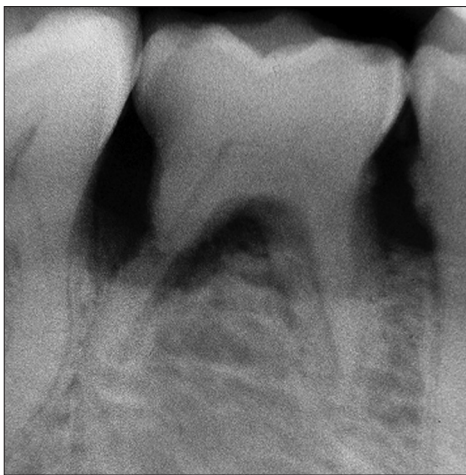updates that have been developed, while commencing total pulpectomy in primary molars are discussed.

## PULPECTOMY PROCEDURES IN PRIMARY MOLARS

### Partial pulpectomy

Decades ago, “pulpotomy” and “partial pulpectomy” were used interchangeably to refer to the excision or amputation of the pulp contents in the coronal portion of the pulp (pulp chamber) without disturbing the contents of the root canal.<sup>[13]</sup> At present, “partial pulpectomy” is widely used to refer to “an apical extension of the pulpotomy procedure” in which the coronal portion of the radicular pulp is amputated, leaving vital tissue in the canal that is assumed to be healthy.<sup>[1]</sup> The decision to implement partial pulpectomy in primary molars is made after removing the coronal pulp and encountering difficulty with hemorrhage control from the radicular orifice.<sup>[1]</sup> Teeth can be scheduled for partial pulpectomy regardless of history of pain; however, the canals should not show evidence of necrosis or suppuration.<sup>[14]</sup>

Endodontic broaches or Hedström files are the most commonly used instruments in partial pulpectomy.<sup>[1,14]</sup> One-third to one-half of the coronal portion of the radicular pulp tissue is removed from the canal(s). The canals and chamber are irrigated using diluted NaOCl and then dried with cotton pellets.<sup>[1]</sup> If hemorrhage cannot be controlled, the remaining radicular pulp tissue is removed and a complete pulpectomy is indicated. After a successful hemorrhage control, a cotton pellet dampened with formocresol is squeezed dry and then it is placed in the pulp chamber for 1-5 mins. The pellet is removed, and the root filling paste is packed into the chamber and canals.<sup>[1]</sup> The quality of filling is evaluated using a periapical radiograph.



**Figure 1:** Retained right primary mandibular second molar in a 45-year-old male patient. External resorption of the distal root is the fate of chronic periodontitis

In a recent randomized clinical study, Ruby *et al.*<sup>[15]</sup> demonstrated a comparable clinical and radiographic success rate of pulpotomy using 3% NaOCl to formocresol (Buckley’s FC dilution 1:5) at 6 and 12 months. These favorable clinical outcomes for NaOCl pulpotomy encourage other long-term clinical studies to investigate the ability of NaOCl to serve as a viable substitute to formocresol in both pulpotomy and partial pulpectomy.

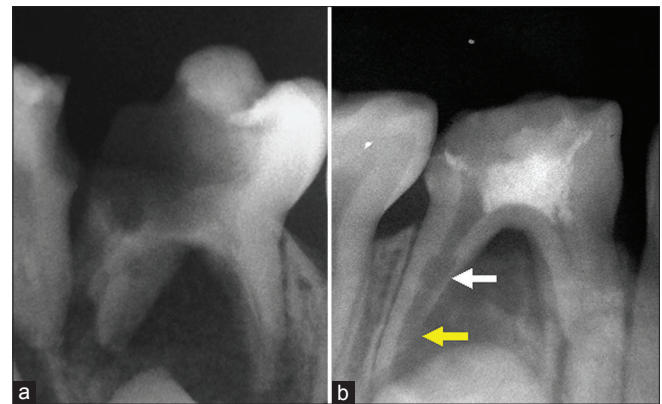
### Partial/total pulpectomy

Internal root resorption visible on radiographs and excessive external pathologic root resorption involving more than one-third of the root are usually reported as contraindications for total pulpectomy in primary teeth<sup>[1,2,16]</sup> [Figure 2]. However, in deciduous molars far from their shedding time, partial/total pulpectomy can be an alternative approach instead of extraction when a pathologic root resorption affects only one of the molar roots and the other root remains intact [Figure 3]. In such cases, the affected root can be treated by partial pulpectomy up to the level of resorption, and the intact root is treated normally via total pulpectomy. A well prepared coronal restoration is particularly important to achieve favorable outcomes [Figure 3].

### Total pulpectomy

#### Total pulpectomy versus non-vital pulpotomy

Different treatment approaches for non-vital/irreversibly inflamed pulps, rather than pulpectomy, have been examined. Non-vital pulpotomy using zinc oxide eugenol (ZOE)–formocresol paste was attempted, with a success rate of 84.8%.<sup>[17]</sup> This result was contradicted by Hill,<sup>[18]</sup> who observed that both the presence of a non-vital pulp and radiolucency are associated with a significantly reduced survival following pulpotomy of primary molars compared with vital teeth with no evidence of extensive pulpal disease. Thus, the persistence of necrotic pulp tissue and microbial irritants, together with the toxicity potential of formocresol which should be used with great caution,<sup>[19,20]</sup> can impair long-term healing.



**Figure 2:** Contra-indications for total pulpectomy. (a) Badly decayed primary molar. (b) Extensive root resorption (white arrow: Internal resorption, yellow arrow: External resorption)

Sterilization and tissue repair therapy or non-instrumentation endodontic therapy using a mixture of antibacterial drugs (metronidazole/ciprofloxacin/minocycline) has been advocated as a simple, safe, and cost-effective substitute for total pulpectomy in the primary dentition. This therapy is especially suitable in cases involving uncooperative children and in areas where the socio-economic status is low and endodontic treatment is not a valid treatment option.<sup>[21-24]</sup> However, in a recent long-term clinical study, Trairatvorakul and Detsomboonrat<sup>[25]</sup> reported only a 36.7% success based on radiographic evaluation, and 15.8% of the cases demonstrated internal root resorption despite the 75% clinical success. With these results considered, this treatment approach demonstrates an unsatisfactory success rate. As reported by the UK National Clinical Guidelines for pulp treatment in the primary dentition, “it would not be biologically acceptable to leave necrotic tissue in a root canal,”<sup>[26]</sup> especially with the wide bacterial diversity and microbial interactions identified in primary teeth having necrotic pulp with or without periapical pathosis.<sup>[27-29]</sup>

By the given information, the unpredictable outcomes of non-vital pulpotomy and the high failure rate of early extraction followed by space maintainers due to solder breakage, cement loss, bond failure, soft-tissue lesions, plaque accumulation, decalcification, or decay of the abutment,<sup>[30-35]</sup> no viable substitute for total pulpectomy for treating non-vital pulps is currently available.

### Challenges

Total pulpectomy of primary teeth is recommended when the criteria for a classical pulpotomy or partial pulpectomy cannot be met [Figure 4]. This procedure refers to the complete removal of irreversibly inflamed

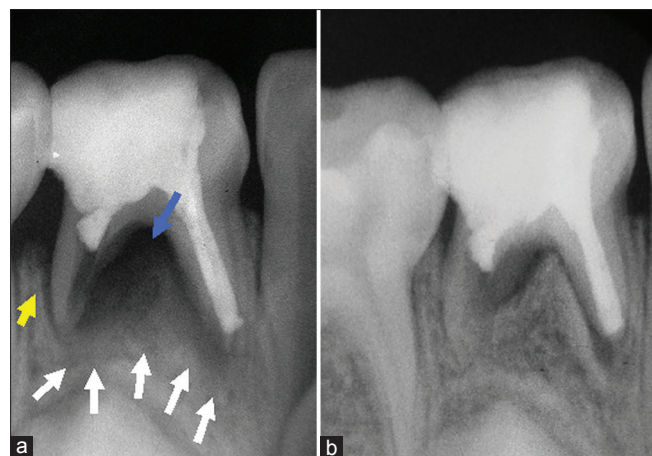
or necrotic pulp tissue in the canals, followed by filling using a resorbable paste in either single or double appointments.<sup>[1,36]</sup> Total pulpectomy in primary molars has been controversial since the question “Should deciduous teeth with non-vital pulps be treated?” raised by Kabnick<sup>[37]</sup> in 1933. The negative attitude toward complete pulpectomy in primary molars is mostly due to fear of damage on the developing permanent tooth buds, as well as the difficulty in negotiating, cleaning, shaping, and filling the bizarre and tortuous canal anatomy of these teeth with resorbing and open apices.<sup>[1,16,38]</sup> A number of dental practitioners prefer extraction of deciduous teeth having necrotic pulps with or without periapical affection and placement of space maintainers because of these anatomical challenges.<sup>[16]</sup> However, no better space maintainer can substitute the primary tooth, and the success rate of pulpectomy in primary teeth has been reported between 80% and 100%,<sup>[39-41]</sup> thus, every primary molar is worth saving.

## GUIDELINES FOR PULPECTOMY PROCEDURES

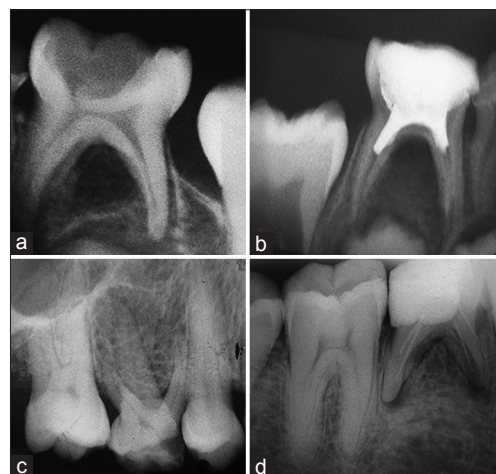
### Pre-operative assessment

Dental practitioners should be aware of:

1. The root and root canal morphology of deciduous molars shows wide anatomical variations, either in number or in shape.<sup>[12,42]</sup> Double rooted maxillary molars can be rather common<sup>[12]</sup> [Figure 5a], and primary molars with five and six root canals have been reported<sup>[12]</sup> [Figure 6]. The occasion of this aberrant internal anatomy might be attributed to secondary dentine formation and physiologic root resorption which are able to reconfigure the root canal system.<sup>[12]</sup>
2. The complex pulp and periodontal tissues



**Figure 3:** Partial/Total pulpectomy. (a) Total pulpectomy of the mesial root and partial pulpectomy of the distal root of primary 1<sup>st</sup> mandibular molar having radiolucencies in the periapical (white arrows) and bifurcation (blue arrow) areas. A vertical bone loss also was observed in the distal aspect of the distal root (yellow arrow). ZnO eugenol paste was used as a root canal filling. (b) Follow-up after 8 months shows favorable healing

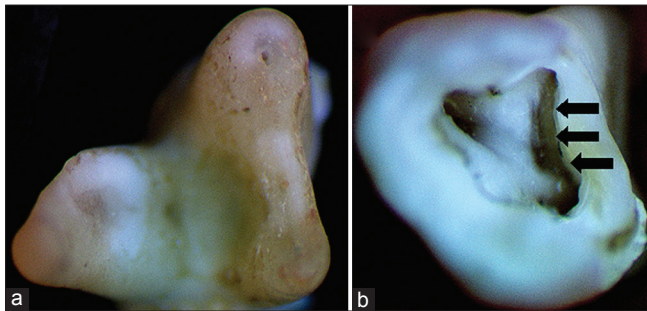


**Figure 4:** Indications for total pulpectomy in primary molars. (a) Non-vital pulp of a primary molar with a successor. (b) Failed pulpotomy/partial pulpectomy. (c) Retained primary molar with vital/non vital pulp; (d) Retreatment of a retained primary molar



inter-relationship in primary molars may result in the occasion of bone radiolucency anywhere along the root or in the furcation area.<sup>[12,43]</sup>

- Following the recommended guidelines for accurate pulp assessment is essential. Recent studies demonstrated the potential application of different diagnostic tools such as electric pulp testers,<sup>[12,44]</sup> pulse-oximeters,<sup>[45,46]</sup> and laser Doppler flow meters<sup>[45]</sup> for pulp assessment in primary teeth.



**Figure 5:** (a) A photograph of a double-rooted maxillary primary molar. (b) Cautious apical extension via a small tapered diamond bur (or a small ultrasonic tip) in the groove between the orifices of the fused distobuccal and palatal roots is recommended to exclude the occurrence of a third canal in the isthmus

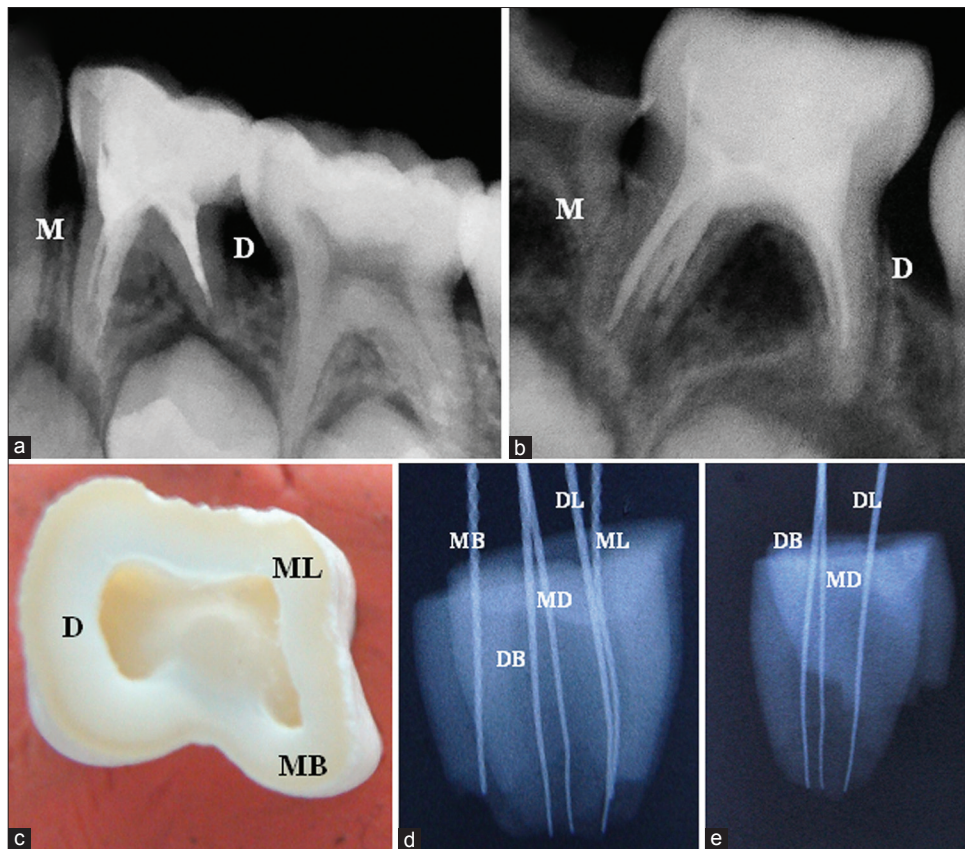
## Intra-operative management

### Root canal preparation

As recommended by the American Academy of Pediatric Dentistry,<sup>[47]</sup> and the UK National Clinical Guidelines for pulp treatment in the primary dentition,<sup>[26]</sup> the application of the rubber dam,<sup>[26,47]</sup> or equally effective isolation technique,<sup>[47]</sup> is mandatory.

Adequate extension of the access cavity and thorough exploration between the root canal orifices is essential [Figure 5b]. Utilizing some sort of magnification is useful.<sup>[12]</sup> Accurate determination of the working length is a crucial step prior to pulpectomy in primary molars. Due to limitations of radiographic interpretation and high possibility of over-instrumentation of the unevenly resorbed roots and subsequent overfilling, the application of electronic apex locators is recommended regardless of the stage of root resorption.<sup>[12]</sup>

During chemo-mechanical preparation, stainless steel hand files, usually not larger than size 30,<sup>[26]</sup> should be used carefully to prevent the occasion of broken segments. Flexible files are recommended in curved and S shaped canals. Rotary NiTi files can significantly reduce the instrumentation time of the root canals,<sup>[12]</sup> and the application of this innovation becomes



**Figure 6:** (a) Mandibular first primary molar having bizarre and tortuous canals in the mesial root. (b) Mandibular second primary molar having five canals. Three in the mesial and two in the distal root. (c-e) Extracted mandibular primary molar having five canals. The distal root encases three separate canals (MD: Middle distal)

more popular.<sup>[48]</sup> Apart from the high cost, Ahmed<sup>[12]</sup> mentioned some concerns regarding the application of this innovation in paediatric endodontics that requires further investigations. Likewise, dental practitioners/ paedodontists should carefully choose irrigating solutions due to possible chemical interactions among different irrigants<sup>[12,49]</sup> [Figure 7]. Intermediate solutions such as saline or sterile distilled water, followed by careful drying, can prevent the formation of toxic interactions<sup>[12,49]</sup> [Figure 7].


### Root canal filling

#### Exfoliating primary molars

Unreinforced ZOE paste is the first and most widely accepted root canal filling for primary teeth.<sup>[36,50,51]</sup> Moderate to high success rates (over 90%) have been

reported since 1930.<sup>[50,52,53]</sup> The disadvantages include the difference in rate of resorption compared with that of the root,<sup>[36,54]</sup> risk of deflection of the erupting successor teeth especially in an overfill,<sup>[52]</sup> and concerns regarding its antimicrobial activity, which may become limited once set.<sup>[55,56]</sup> To improve the anti-microbial properties of ZOE paste, additives such as formocresol, formaldehyde, paraformaldehyde and chlorhexidine dihydrochloride have been recommended;<sup>[50,57,58]</sup> however, concerns arise regarding the cytotoxic effects of formocresol, especially if the filling is introduced inadvertently into the periapical area closely related to the erupting successor tooth.

Calcium hydroxide paste is one of the most widely used intra-canal medicaments in endodontic therapy. However, its use as a filling material in pulpotomy for



**Figure 7:** Combination of irrigants advocated for the primary dentition. (a) 2.5% NaOCl + 2% CHX. (b) 1.5% NaOCl + 2% CHX. (c) 0.5% NaOCl + 2% CHX. (d) 0.5% NaOCl + 1% CHX. (e) 1.5% NaOCl + 6% citric acid (CA). (f) 18% EDTA + 1% CHX. (g and h) Intermediate irrigants between NaOCl and CHX blocked the formation of the brown precipitate, but the combinations turn cloudy



primary dentition was challenged because it can induce internal root resorption,<sup>[59]</sup> which may also limit its indication as a root canal filling in partial pulpectomy. Despite this concern, studies continue to support the use of calcium hydroxide pastes as filling material for totally pulpectomized primary teeth because of potent anti-bacterial effects and it can be easily resorbed.<sup>[60-63]</sup>

Iodoform-based pastes, such as KRI paste, were also recommended as root filling materials in primary molars.<sup>[64]</sup> These pastes satisfy most of the requirements of an ideal filling material for primary teeth because they are easily resorbed from the periapical area and possess potent germicidal properties.<sup>[65]</sup> Chlorhexidine digluconate is suggested as an additive to iodoform-based pastes instead of camphorated parachlorophenol to obtain a favorable biological profile while maintaining a potent anti-microbial activity.<sup>[66]</sup>

Vitapex (Neo Dental Chemical Products Co., Ltd., Tokyo, Japan), a combination of calcium hydroxide and iodoform, is another alternative that can be applied easily. This material showed a favorable rate of resorption, reduced void formation and satisfactory radiographic and clinical outcomes.<sup>[23,53,65,67-70]</sup> Similar observations were reported with Metapex (Metapex, Meta Dental, New York, USA).<sup>[71]</sup> However, this combination did not exhibit a potent anti-microbial activity,<sup>[57,72-74]</sup> which may be due to the strong inhibitory effect of dentine.<sup>[75]</sup> Endoflas F.S. (Sanlor and Cia. S. en C.S., Columbia, South America) is another iodoform-based paste containing calcium hydroxide, which also showed high clinical success rates.<sup>[41]</sup>

Overfill is a common clinical finding in the primary dentition, especially when apical resorption and/or the paste is applied through a pressure syringe. Johnson *et al.*<sup>[76]</sup> examined the use of a 2 mm × 2 mm collagen sponge (Collacote, Zimmer Dental, Texas, USA) as an apical barrier per canal. The results showed that the presence of a biological barrier significantly decreased, but not completely prevented, the risk of overfilling when pulpectomies were performed in primary molars.

#### Retained primary molars

The physiologic root resorption of primary dentition is initiated and coordinated by the dental follicle of the permanent tooth germ.<sup>[77]</sup> This programmed resorption may proceed even without the permanent successor. The reason may be that periodontal ligament cells in the primary dentition more strongly respond to inflammatory mediators and undergo resorption compared with those in the permanent dentition.<sup>[77]</sup> In addition, after the growth of the facial and masticatory muscles, these periodontal tissues may not withstand applied forces, which can induce resorption. No certain predictors for the survival of a deciduous tooth without a successor are known; however, a primary molar that is retained until

the age of 20 indicates a high probability for long-term survival<sup>[7,77,78]</sup> [Figure 1].

Likewise, no definitive landmarks for the survival of retained primary molars without root resorption are known. The literature continues to support the use of non-resorbable gutta-percha as root canal filling for such retained primary molars.<sup>[2,11,16,54,79,80]</sup> For patients below 20 years of age, the follow-up appointment should be scheduled regularly at 3-6 months. Removal of the root canal filling and the application of calcium hydroxide can be attempted if apparent signs of resorption occur. In case of severe resorption, tooth extraction and gutta-percha removal, if retained in the socket, are the last resort.

O'Sullivan and Hartwell<sup>[81]</sup> reported the short-term success following the use of ProRoot mineral trioxide aggregate (MTA) (Dentsply, USA) as a root filling material in a retained primary second molar of a 20-year-old patient. However, MTA is not widely advocated for such clinical application, probably because of the high cost of the material and difficulty in application into relatively narrow root canals. Moreover, it seems that the application of MTA would not reduce the high risk of root resorption in retained molars of younger patients.<sup>[82]</sup>

#### Post-endodontic considerations

Following filling and resolution of all symptoms (if any), the tooth should be restored with a suitable coronal restoration to prevent micro-leakage. The floor of the pulp chamber can be filled with either reinforced ZOE or glass ionomer cement if the coronal part is to be restored with resin composite.<sup>[11]</sup> A stainless steel crown is the treatment of choice for badly decayed primary teeth; this approach requires careful plaque control to maintain the health of the gingiva and inter-proximal bone.<sup>[40,83]</sup> Pre-veneered crown, a stainless steel crown with mechanically or chemically bonded aesthetic material covering one or more surfaces of the crown, can also be fabricated if the patient can maintain good oral hygiene.<sup>[84]</sup> However, if the pulpectomized tooth has a sufficient crown structure and only one surface is missing for less than 2 years before exfoliation, amalgam or resin composite are the materials of choice.<sup>[85]</sup>

#### CONCLUSIONS

Partial, partial/total and total pulpectomy procedures provide reasonable treatment options for primary molars having radicular canals with partial/total irreversibly inflamed or necrotic pulp. Adequate knowledge on the root anatomical variations and absolute awareness of the radiographic limitations, instrumentation procedures, chemical interactions among different endodontic irrigants and root canal filling techniques are essential prior to commencing pulpectomy procedures in exfoliating or retained primary molars.

## REFERENCES

- Dummett CO Jr, Kopel HM. Pediatric endodontics. In: Ingle JI, Bakland LK, editors. Endodontics. 5<sup>th</sup> ed. Hamilton: BC Decker Inc.; 2002. p. 861-902.
- Ounsi HF, Debaybo D, Salameh Z, Chebaro A, Bassam H. Endodontic considerations in pediatric dentistry: A clinical perspective. *Int Dent South Afr* 2009;11:40-50.
- Berk H, Krakow AA. A comparison of the management of pulpal pathosis in deciduous and permanent teeth. *Oral Surg Oral Med Oral Pathol* 1972;34:944-55.
- Nordquist I, Lennartsson B, Paulander J. Primary teeth in adults – A pilot study. *Swed Dent J* 2005;29:27-34.
- Aktan AM, Kara I, Sener I, Bereket C, Celik S, Kirtay M, *et al*. An evaluation of factors associated with persistent primary teeth. *Eur J Orthod* 2012;34:208-12.
- Ith-Hansen K, Kjaer I. Persistence of deciduous molars in subjects with agenesis of the second premolars. *Eur J Orthod* 2000;22:239-43.
- Sletten DW, Smith BM, Southard KA, Casco JS, Southard TE. Retained deciduous mandibular molars in adults: A radiographic study of long-term changes. *Am J Orthod Dentofacial Orthop* 2003;124:625-30.
- Bjerklin K, Al-Najjar M, Kårestedt H, Andrén A. Agenesis of mandibular second premolars with retained primary molars: A longitudinal radiographic study of 99 subjects from 12 years of age to adulthood. *Eur J Orthod* 2008;30:254-61.
- Robinson S, Chan MF. New teeth from old: Treatment options for retained primary teeth. *Br Dent J* 2009;207:315-20.
- Kokich VG, Kokich VO. Congenitally missing mandibular second premolars: Clinical options. *Am J Orthod Dentofacial Orthop* 2006;130:437-44.
- Jha P, Jha M. Management of congenitally missing second premolars in a growing child. *J Conserv Dent* 2012;15:187-90.
- Ahmed HM. Anatomical challenges, electronic working length determination and current developments in root canal preparation of primary molar teeth. *Int Endod J* 2013;46:1011-22.
- Gardner AF. Partial pulpectomy, an accepted treatment for primary and young permanent teeth. *Oral Surg Oral Med Oral Pathol Oral Radiol* 1950;3:498-503.
- McDonald RE, Avery DR, Dean JA. Treatment of deep caries, vital pulp exposure and pulpless teeth. In: Dean JA, Avery DR, McDonald RE, editors. McDonald and Avery's Dentistry for the Child and Adolescent. 9<sup>th</sup> ed. Missouri: Mosby Elsevier; 2011. p. 343-65.
- Ruby JD, Cox CF, Mitchell SC, Makhija S, Chompu-Inwai P, Jackson J. A randomized study of sodium hypochlorite versus formocresol pulpotomy in primary molar teeth. *Int J Paediatr Dent* 2013;23:145-52.
- Camp JH, Fuks AB. Pediatric endodontics: Endodontic treatment for the primary and young permanent dentition. In: Cohen S, Hargreaves K, editors. Pathways of the Pulp. 9<sup>th</sup> ed. St. Louis: Mosby Elsevier; 2006. p. 822-82.
- Roberts JF. Treatment of vital and non-vital primary molar teeth by one-stage formocresol pulpotomy: Clinical success and effect upon age at exfoliation. *Int J Paediatr Dent* 1996;6:111-5.
- Hill MW. The survival of vital and non-vital deciduous molar teeth following pulpotomy. *Aust Dent J* 2007;52:181-6.
- Zarzar PA, Rosenblatt A, Takahashi CS, Takeuchi PL, Costa Júnior LA. Formocresol mutagenicity following primary tooth pulp therapy: An *in vivo* study. *J Dent* 2003;31:479-85.
- Lucas Leite AC, Rosenblatt A, da Silva Calixto M, da Silva CM, Santos N. Genotoxic effect of formocresol pulp therapy of deciduous teeth. *Mutat Res* 2012;747:93-7.
- Takushige T, Cruz EV, Asgor Moral A, Hoshino E. Endodontic treatment of primary teeth using a combination of antibacterial drugs. *Int Endod J* 2004;37:132-8.
- Prabhakar AR, Sridevi E, Raju OS, Satish V. Endodontic treatment of primary teeth using combination of antibacterial drugs: An *in vivo* study. *J Indian Soc Pedod Prev Dent* 2008;26 Suppl 1:S5-10.
- Nakornchai S, Banditsing P, Visetratana N. Clinical evaluation of 3Mix and Vitapex as treatment options for pulpally involved primary molars. *Int J Paediatr Dent* 2010;20:214-21.
- Pinky C, Shashibhushan KK, Subbareddy VV. Endodontic treatment of necrosed primary teeth using two different combinations of antibacterial drugs: An *in vivo* study. *J Indian Soc Pedod Prev Dent* 2011;29:121-7.
- Trairatvorakul C, Detsomboonrat P. Success rates of a mixture of ciprofloxacin, metronidazole, and minocycline antibiotics used in the non-instrumentation endodontic treatment of mandibular primary molars with carious pulpal involvement. *Int J Paediatr Dent* 2012;22:217-27.
- Rodd HD, Waterhouse PJ, Fuks AB, Fayle SA, Moffat MA, British Society of Paediatric Dentistry. Pulp therapy for primary molars. *Int J Paediatr Dent* 2006;16 Suppl 1:15-23.
- Ruvière DB, Leonardo MR, da Silva LA, Ito IY, Nelson-Filho P. Assessment of the microbiota in root canals of human primary teeth by checkerboard DNA-DNA hybridization. *J Dent Child (Chic)* 2007;74:118-23.
- Rocha CT, Rossi MA, Leonardo MR, Rocha LB, Nelson-Filho P, Silva LA. Biofilm on the apical region of roots in primary teeth with vital and necrotic pulps with or without radiographically evident apical pathosis. *Int Endod J* 2008;41:664-9.
- Tavares WL, Neves de Brito LC, Teles RP, Massara ML, Ribeiro Sobrinho AP, Haffajee AD, *et al*. Microbiota of deciduous endodontic infections analysed by MDA and checkerboard DNA-DNA hybridization. *Int Endod J* 2011;44:225-35.
- Qudeimat MA, Fayle SA. The longevity of space maintainers: A retrospective study. *Pediatr Dent* 1998;20:267-72.
- Rajab LD. Clinical performance and survival of space maintainers: Evaluation over a period of 5 years. *ASDC J Dent Child* 2002;69:156-60, 124.
- Kargul B, Caglar E, Kabalay U. Glass fiber-reinforced composite resin as fixed space maintainers in children: 12-month clinical follow-up. *J Dent Child (Chic)* 2005;72:109-12.
- Moore TR, Kennedy DB. Bilateral space maintainers: A 7-year retrospective study from private practice. *Pediatr Dent* 2006;28:499-505.
- Subramaniam P, Babu G, Sunny R. Glass fiber-reinforced composite resin as a space maintainer: A clinical study. *J Indian Soc Pedod Prev Dent* 2008;26 Suppl 3:S98-103.
- Sasa IS, Hasan AA, Qudeimat MA. Longevity of band and loop space maintainers using glass ionomer cement: A prospective study. *Eur Arch Paediatr Dent* 2009;10:6-10.
- Allen KR. Endodontic treatment of primary teeth. *Aust Dent J* 1979;24:347-51.
- Kabnick LS. Should deciduous teeth with nonvital pulps be treated? *Int J Orthod Dent Child* 1933;19:1043-9.
- Tannure PN, Barcelos R, Portela MB, Gleiser R, Primo LG. Histopathologic and SEM analysis of primary teeth with pulpectomy failure. *Oral Surg Oral Med Oral Pathol Oral Radiol Endod* 2009;108:e29-33.
- Barr ES, Flatiz CM, Hicks MJ. A retrospective radiographic evaluation of primary molar pulpectomies. *Pediatr Dent* 1991;13:4-9.
- Moskovitz M, Sammara E, Holan G. Success rate of root canal treatment in primary molars. *J Dent* 2005;33:41-7.
- Moskovitz M, Yahav D, Tickotsky N, Holan G. Long-term follow up of root canal treated primary molars. *Int J Paediatr Dent* 2010;20:207-13.
- Cleghorn BM, Boorberg NB, Christie WH. Primary human teeth and their root canal systems. *Endod Top* 2012;23:6-33.

43. Ahmed HM. Different perspectives in understanding the pulp and periodontal intercommunications with a new proposed classification for endo-perio lesions. *ENDO (Lond Engl)* 2012;6:87-104.
44. Hori A, Poureslami HR, Parirokh M, Mirzazadeh A, Abbott P. The ability of pulp sensibility tests to evaluate the pulp status in primary teeth. *Int J Paediatr Dent* 2011;21:441-5.
45. Karayilmaz H, Kirzioğlu Z. Evaluation of pulpal blood flow changes in primary molars with physiological root resorption by laser Doppler flowmetry and pulse oximetry. *J Clin Pediatr Dent* 2011;36:139-44.
46. Pozzobon MH, de Sousa Vieira R, Alves AM, Reyes-Carmona J, Teixeira CS, de Souza BD, *et al.* Assessment of pulp blood flow in primary and permanent teeth using pulse oximetry. *Dent Traumatol* 2011;27:184-8.
47. AAPD. Guideline on pulp therapy for primary and immature permanent teeth. *Pediatr Dent* 2012;34:222-9.
48. Dunston B, Coll JA. A survey of primary tooth pulp therapy as taught in US dental schools and practiced by diplomates of the American board of pediatric dentistry. *Pediatr Dent* 2008;30:42-8.
49. Ahmed HM, Abbott PV. Discolouration potential of endodontic procedures and materials: A review. *Int Endod J* 2012;45:883-97.
50. Milledge JT. Endodontic therapy for primary teeth. In: Ingle JI, Bakland LK, Baumgartner JC, editors. *Ingle's Endodontics*. 6<sup>th</sup> ed. Hamilton: BC Decker Inc.; 2008. p. 1400-30.
51. Barcelos R, Santos MP, Primo LG, Luiz RR, Maia LC. ZOE paste pulpectomies outcome in primary teeth: A systematic review. *J Clin Pediatr Dent* 2011;35:241-8.
52. Coll JA, Sadrian R. Predicting pulpectomy success and its relationship to exfoliation and succedaneous dentition. *Pediatr Dent* 1996;18:57-63.
53. Mortazavi M, Mesbahi M. Comparison of zinc oxide and eugenol, and Vitapex for root canal treatment of necrotic primary teeth. *Int J Paediatr Dent* 2004;14:417-24.
54. Koshy S, Love RM. Endodontic treatment in the primary dentition. *Aust Endod J* 2004;30:59-68.
55. Ranly DM, Garcia-Godoy F. Current and potential pulp therapies for primary and young permanent teeth. *J Dent* 2000;28:153-61.
56. Barja-Fidalgo F, Moutinho-Ribeiro M, Oliveira MA, de Oliveira BH. A systematic review of root canal filling materials for deciduous teeth: Is there an alternative for zinc oxide-eugenol? *ISRN Dent* 2011;2011:367318.
57. Tchaou WS, Turg BF, Minah GE, Coll JA. *In vitro* inhibition of bacteria from root canals of primary teeth by various dental materials. *Pediatr Dent* 1995;17:351-5.
58. Praveen P, Anantharaj A, Karthik V, Prathiba R, Sudhir R, Jaya A. A review of obturating materials for primary teeth. *Streamdent* 2011;2:42-4.
59. Liu H, Zhou Q, Qin M. Mineral trioxide aggregate versus calcium hydroxide for pulpotomy in primary molars. *Chin J Dent Res* 2011;14:121-5.
60. Ozalp N, Saroğlu I, Sönmez H. Evaluation of various root canal filling materials in primary molar pulpectomies: An *in vivo* study. *Am J Dent* 2005;18:347-50.
61. Kielbassa AM, Uchtmann H, Wrbas KT, Bitter K. *In vitro* study assessing apical leakage of sealer-only backfills in root canals of primary teeth. *J Dent* 2007;35:607-13.
62. Sari S, Okte Z. Success rate of Sealapex in root canal treatment for primary teeth: 3-year follow-up. *Oral Surg Oral Med Oral Pathol Oral Radiol Endod* 2008;105:e93-6.
63. Dogra S. Comparative evaluation of calcium hydroxide and zinc oxide eugenol as root canal filling materials for primary molars: A clinical and radiographic study. *World J Dent* 2011;2:231-6.
64. Chen J, Jorden M. Materials for primary tooth pulp treatment: The present and the future. *Endod Top* 2012;23:41-9.
65. Cerqueira DF, Mello-Moura AC, Santos EM, Guedes-Pinto AC. Cytotoxicity, histopathological, microbiological and clinical aspects of an endodontic iodoform-based paste used in pediatric dentistry: A review. *J Clin Pediatr Dent* 2008;32:105-10.
66. Vargas-Ferreira F, Angonese M, Friedrich H, Weiss R, Friedrich R, Praetzel J. Antimicrobial action of root canal filling pastes used in deciduous teeth. *Rev Odonto Ciênc* 2010;25:65-8.
67. Nurko C, Garcia-Godoy F. Evaluation of a calcium hydroxide/iodoform paste (Vitapex) in root canal therapy for primary teeth. *J Clin Pediatr Dent* 1999;23:289-94.
68. Nurko C, Ranly DM, Garcia-Godoy F, Lakshmyya KN. Resorption of a calcium hydroxide/iodoform paste (Vitapex) in root canal therapy for primary teeth: A case report. *Pediatr Dent* 2000;22:517-20.
69. Trairatvorakul C, Chunlasikaiwan S. Success of pulpectomy with zinc oxide-eugenol vs calcium hydroxide/iodoform paste in primary molars: A clinical study. *Pediatr Dent* 2008;30:303-8.
70. Asokan S, Sooriaprakas C, Raghu V, Bairavi R. Volumetric analysis of root canal fillings in primary teeth using spiral computed tomography: An *in vitro* study. *J Dent Child (Chic)* 2012;79:46-8.
71. Subramaniam P, Gilhotra K. Endoflas, zinc oxide eugenol and metapex as root canal filling materials in primary molars – A comparative clinical study. *J Clin Pediatr Dent* 2011;35:365-9.
72. Amorim Lde F, Toledo OA, Estrela CR, Decurcio Dde A, Estrela C. Antimicrobial analysis of different root canal filling pastes used in pediatric dentistry by two experimental methods. *Braz Dent J* 2006;17:317-22.
73. Reddy S, Ramakrishna Y. Evaluation of antimicrobial efficacy of various root canal filling materials used in primary teeth: A microbiological study. *J Clin Pediatr Dent* 2007;31:193-8.
74. Gangwar A. Antimicrobial effectiveness of different preparations of calcium hydroxide. *Indian J Dent Res* 2011;22:66-70.
75. Portenier I, Haapasalo H, Rye A, Waltimo T, Ørstavik D, Haapasalo M. Inactivation of root canal medicaments by dentine, hydroxylapatite and bovine serum albumin. *Int Endod J* 2001;34:184-8.
76. Johnson MS, Britto LR, Guelmann M. Impact of a biological barrier in pulpectomies of primary molars. *Pediatr Dent* 2006;28:506-10.
77. Harokopakis-Hajishengallis E. Physiologic root resorption in primary teeth: Molecular and histological events. *J Oral Sci* 2007;49:1-12.
78. Bjerklin K, Bennett J. The long-term survival of lower second primary molars in subjects with agenesis of the premolars. *Eur J Orthod* 2000;22:245-55.
79. Canoglu H, Tekcicek MU, Cehreli ZC. Comparison of conventional, rotary, and ultrasonic preparation, different final irrigation regimens, and 2 sealers in primary molar root canal therapy. *Pediatr Dent* 2006;28:518-23.
80. Bolla N, Naik BD, Kavuri SR, Velagala LD. Obturation of a retained primary mandibular second molar with missing successor using gutta-percha: A case report. *J Indian Dent Assoc* 2011;5:194-5.
81. O'Sullivan SM, Hartwell GR. Obturation of a retained primary mandibular second molar using mineral trioxide aggregate: A case report. *J Endod* 2001;27:703-5.
82. Tunc ES, Bayrak S. Usage of white mineral trioxide aggregate in a non-vital primary molar with no permanent successor. *Aust Dent J* 2010;55:92-5.
83. Sharaf AA, Farsi NM. A clinical and radiographic evaluation of stainless steel crowns for primary molars. *J Dent* 2004;32:27-33.
84. Bin Alshaihab WM, Ahmed E-S, Abdo E-D, Reda AR. Comparative study on the microbial adhesion to veneered and stainless steel crowns. *Indian J Dent* 2011;2:123-8.
85. Stallaert KM. *A Retrospective Study of Root Canal Therapy in Non-vital Primary Molars*. Toronto: University of Toronto; 2011.

**How to cite this article:** Ahmed HM. Pulpectomy procedures in primary molar teeth. *Eur J Gen Dent* 2014;3:3-10.  
**Source of Support:** Nil, **Conflict of Interest:** None declared.