

# Transparent tooth model: A study of root canal morphology using different reagents

Bhavana Gupta, Babusha Tiwari, Vineet Raj, Bina Kashyap<sup>1</sup>, Shaleen Chandra<sup>2</sup>, Nidhi Dwivedi<sup>3</sup>

Department of Oral Pathology, Saraswati Dental College and Hospital, Lucknow, <sup>1</sup>Vishnu Dental College, Bhimavaram, Andhra Pradesh, <sup>2</sup>King George's Medical University, Lucknow, <sup>3</sup>Babu Banarasi Das College of Dental Sciences, Lucknow, Uttar Pradesh, India

Address for correspondence:

Dr. Nidhi Dwivedi,  
2/308, Vibhav Khand, Gomti Nagar,  
Lucknow, Uttar Pradesh, India.  
E-mail: nidhidwivedi2002@gmail.com

## ABSTRACT

**Background:** The complexity of root canal morphology has fascinated the imaginations of many. Several techniques have been tried in the past to view the three-dimensional anatomy of the pulp canal system with varied success. It has been hypothesized in the present study that a combination of decalcifying agent and clearing agent can be used to prepare transparent tooth model. **Aims:** The aim of the present study was to access the efficacy of two decalcifying agent (formic acid and nitric acid) and two clearing agents (methyl salicylate and eugenol) to prepare transparent tooth model. **Materials and Methods:** The study material included 80 freshly extracted teeth both maxillary and mandibular. After decalcifying and clearing of the specimen, they were graded for transparency and haziness criteria. **Results:** The results of the present study indicated that methyl salicylate when used as a clearing agent showed better transparency, lower level of haziness and good root canal morphology. On the other hand samples cleared by eugenol showed good root canal morphology but lesser transparency and higher degree of haziness and yellowing of samples, more so when used in combination with nitric acid. **Conclusion:** It was concluded by the present study that combination of nitric acid when used with methyl salicylate proved to be the best combination for the preparation of the transparent tooth model.

## Key words

Eugenol, formic acid, methyl salicylate, nitric acid, transparent tooth model

## INTRODUCTION

For many years, the anatomical study of the pulpal spaces (pulpal chambers and the root canals) for preclinical dental anatomy, conservative and endodontic purposes, as well as the study of their relationship to the exterior of the tooth for restorative purposes, has been somewhat restricted.

Previously used methods such as cross sections of the tooth gave a three-dimensional view of the pulpal spaces within the tooth, but the morphology of the exterior of tooth was destroyed in the process.<sup>[1]</sup>

A variety of technique has been proposed to permit visualization of the root canal system and the effect of biomechanical procedures on the tooth.<sup>[2]</sup> Processes for

rendering teeth transparent have been used to study root canal morphology and microvasculature. The procedures involve decalcifying in acid, dehydrating in alcohol and acetone, and rendering the tooth transparent using glycerin, silicone, clear casting resin, xylene, or methyl salicylate.<sup>[3]</sup>

Vulcanite replicas of the root canals in 1925 were made, which served as good teaching aids in their time, but they did not include the pulpal chambers.<sup>[4]</sup> Sommer *et al.* demonstrated a technique where sectioned longitudinally to give a sagittal view of pulpal space from coronal portion to apex. Exposed canal was filled with the opaque wax. This method rarely showed lateral canals.<sup>[5]</sup>

Rosenteil E established that root canals can be reproduced with radio-opaque material.<sup>[6]</sup> Pulpal residue removed by papain digesting solution, the material was introduced by digesting solution; the material was introduced by syringe through a previously drilled hole in the proximal surface of the tooth leading to pulpal chamber. Radiographs were taken and mounted together or superimposed on one another for study. In this technique, the three-dimensional aspect of pulp and depth was lost and only two-dimensional aspect was available as teaching aid.

| Access this article online  |                                  |
|---|----------------------------------|
| Quick Response Code:  | Website:<br>www.ejgd.org         |
|  | DOI:<br>10.4103/2278-9626.126215 |

Barber *et al.* reproduced teeth in clear polished resin and filled pulpal spaces with red epoxy resin, which was strong and resist fracture. This method was first successful attempt to give truly three-dimensional view of the pulpal spaces. It was criticized because the clear plastic specimens were mounted on Perspex pedestals in clear liquid paraffin. This method is extremely difficult to associate the pulpal spaces with the exterior of the tooth. The apical portion of tooth which is greater value to the endodontist was obstructed by the mounting.<sup>[7]</sup>

Transparent tooth model offers a convenient and useful method that can be used. The uses of transparent tooth model system are numerous. It can be used for studying the morphology of teeth. It provides a three-dimensional view of root canal system, which can be used as an aid in teaching dental anatomy. It was hypothesized that various decalcifying and clearing agents can be used to prepare transparent tooth model. The objective of the present study was to access the efficacy of different decalcifying agents and different clearing agents for preparation of transparent tooth model.

## MATERIALS AND METHODS

The study material included 80 freshly extracted teeth both maxillary and mandibular, which were selected randomly. The criteria for selection of teeth were that at least two-third of the entire crown with well-preserved root morphology should be present. The exclusion criteria were teeth with calcified canals, resorbed roots, or with any periapical pathology.

The teeth were decalcified using two decalcifying agents i.e. Nitric acid (10%) and Formic acid (20%). Then, they were cleared using two clearing agents; methyl salicylate and eugenol. The access of the extracted teeth was gained through the occlusal/lingual surface of the tooth. The patency of the pulp canal was checked using No. 8 endodontic file, and any remnant pulpal tissue was removed using a broach. Then, half of the specimens (40 teeth) were decalcified in 10% nitric acid solution for 3-4 days, and the other half of the specimens (40 teeth) were decalcified in 20% formic acid solution for 7-8 days.

The end point of decalcification was determined by careful piercing with the needle to check the end point of decalcification.<sup>[8]</sup> After completion of decalcification, the teeth were rinsed in running tap water for 4 hours.

The dehydration process consisted of a series of ethyl alcohol rinses starting from 80% solution overnight followed by 90% solution for one hour and three 100% (absolute alcohol) rinses for an hour each. Half of the dehydrated teeth (20 FA + 20 NA) were placed in methyl salicylate for 60-90 min, and the other half (20 FA + 20 NA) were placed in eugenol for clearing for 48 hours. Commercially available alcohol-soluble dye eosin and methylene blue

were injected into the pulp chamber using insulin syringes. The pulp cavity was filled with the dye drop by drop till the whole teeth were filled with dye solution. Then, the teeth were sealed with sticky wax. The appearance of the dye at apical end of the tooth indicated the end of the process. The excess dye was cleaned from the outside of the tooth with the gauze soaked in methyl salicylate. The teeth were left in the methyl salicylate solution indefinitely until they were examined.

The study included the following subgroups

1. NA/MS (decalcification by nitric acid and clearing with methyl salicylate) - Figure 1; 1a
2. NA/E (decalcification by nitric acid and clearing with eugenol) - Figure: 2
3. FA/MS (decalcification by formic acid and clearing with methyl salicylate) - Figure: 3
4. FA/E (decalcification by formic acid and clearing with eugenol) - Figure - 4, 4a.

All the teeth were graded for transparency and haziness using the following criteria.

## CRITERIA FOR GRADING TRANSPARENCY AND HAZINESS

### Transparency criteria

Whole of the root canal visible-+ + (double positive)  
Partially visible root canal- + (single positive)  
Not visible- - (negative).

### Haziness criteria

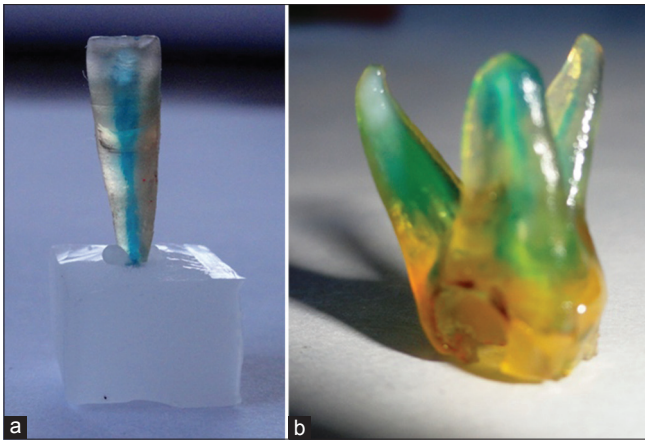
Present- + (positive)  
Absent- - (negative).

## RESULTS


The results of the present study revealed that nitric acid (NA) took lesser (3-4 days) time than formic acid (FA) (7-8 days) for decalcification. As a clearing agent, Methyl salicylate (MS) took approximately 90 minutes while eugenol (E) took 48 hours for decalcification. Though nitric acid caused discoloration of teeth as compared to formic acid, few samples decalcified with formic acid showed post-decalcification clogging of root canals as compared to nitric acid, which showed no clogging.

When transparency criteria were compared between two study groups, it was found that MS showed better transparency in combination with FA in 80% of samples while NA and FA combination showed average transparency with 70% of the samples [Figure 5].

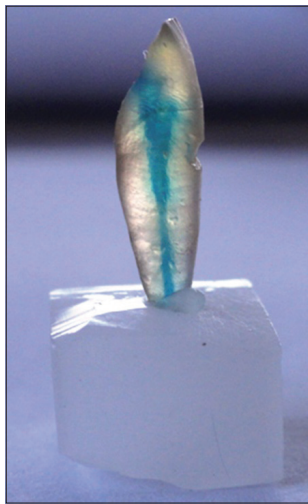
In 10% of samples with combination of with FA as decalcifying agent showed poor transparency irrespective of the clearing agents used (FA or E) [Figure 5].




**Figure 1:** (a) NA/MS combination used i.e. decalcification by nitric acid and clearing with methyl salicylate, (b) NA/MS combination used i.e. decalcification by nitric acid and clearing with methyl salicylate in multi-rooted teeth



**Figure 2:** NA/E combination used i.e. decalcification by nitric acid and clearing with eugenol



**Figure 3:** FA/ MS combination used i.e. decalcification by formic acid and clearing with methyl salicylate



**Figure 4:** (a) FA/E combination used i.e. decalcification by formic acid and clearing with eugenol, (b) FA/ E combination used i.e. decalcification by formic acid and clearing with eugenol in multi-rooted tooth

When haziness criteria was compared amongst study groups, it was found that it was absent in 70% of samples cleared with MS using NA as decalcifying agents. When eugenol was used as clearing agent, 100% of samples showed haziness irrespective of the decalcifying agents used i.e. NA or FA.

## DISCUSSION

A variety of techniques have been used to study root canal morphology including radiographic examination,<sup>[9]</sup> root sectioning,<sup>[10]</sup> and staining and clearing techniques.<sup>[11]</sup> It has been reported that fine details of the root canal system can be visualized by staining and clearing,<sup>[12]</sup> and this method was used in the present study.

The study of the complex root canal morphology is very important, and various techniques have been advocated. Vertical sectioning can be done, but this

does not allow a continuous view of the entire root canal system. Longitudinal sectioning compensates for it, but a three-dimensional picture is not possible. SEM studies too have a major disadvantage of limited area available.<sup>[13]</sup>

Till 1982, the clearing procedure was used for anatomical studies of the pulp cavity.<sup>[14]</sup>

In 1983, Tagger *et al.* put forward an improved method with methyl salicylate as the clearing agent for three-dimensional study on apical leakage.<sup>[15]</sup>

The clearing technique or transparent root canal makes three-dimensional assessments possible.<sup>[3]</sup> It also maintains the original form of the root canal even to its minute detail.<sup>[16]</sup> The specimen can also be preserved for a longer period of time.

Hasselgren G and Tronstad L used teeth that were

de-mineralized and then cleared and hardened in xylene, for teaching of preclinical endodontists. They found that out of 39 students attending the course, 30 students thought that the use of transparent teeth had facilitated the learning of endodontic techniques.<sup>[17]</sup> Thus, transparent tooth model can be used as a useful teaching aid for undergraduate teaching of dental anatomy and endodontics.

The root canal system appears in such a myriad variety of shapes, configuration, and patterns that it is virtually impossible to completely debride the system entirely. A variety of techniques has been used to study root canal morphology. The clearing technique was used to study root canal anatomy. It gives a three-dimensional view of the pulp cavity, in relation to the exterior of the tooth. In addition, it is not necessary to enter the specimen with instruments. Thus, the original form and relationships of the canals are maintained. The form of the canal, even its minute structures, can be drawn clearly. Failures in the preparation of specimens are rare. The specimens can be preserved for a long time.

Verma M subjected 27 teeth to the process of decalcification, dehydration, and clearing, which rendered them transparent. These teeth were then studied for their morphology, micro-leakage, broken instrument etc.; the author concluded that the tooth can be rendered transparent *in vitro* by a relatively easy and inexpensive method. This can be put to many uses like studying the pulpal anatomy, micro leakage studies, analysis of broken instruments and perforations, homogeneity, and adaptation of Gutta-percha, etc.<sup>[18]</sup>

In the present study, two decalcifying agents were used i.e. nitric acid and formic acid. Decalcification with nitric acid was faster with time period of 3-4 days while with formic acid, it took longer time duration of 7-8 days. Then, the teeth were decalcified with methyl salicylate and eugenol as clearing agents.

When the teeth were graded for transparency, the combination of nitric acid and methyl salicylate proved to be the best. Although nitric acid caused yellowish discoloration of teeth, there was minimal clogging observed in samples decalcified with nitric acid as compared to formic acid [Figure 1].

Also, the samples that were decalcified with nitric acid and cleared with formic acid showed absence of haziness in 70% of the samples as compared to other study groups. In haziness criteria, the combination of FA/E and NA/E showed 100% samples with haziness [Figure 6].

Till date, various techniques have been used to prepare transparent tooth model, but they have unavoidable drawbacks. Using this clearing technique, we got three-dimensional view of the pulp canal. This

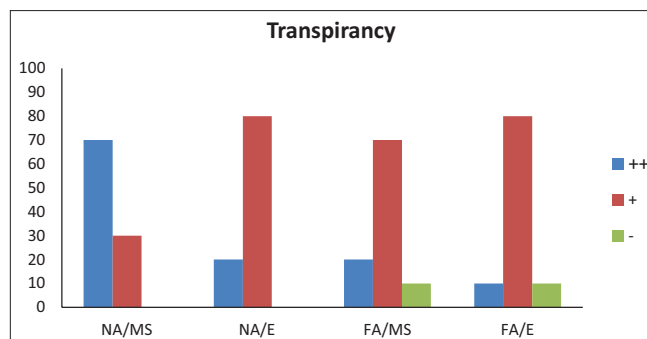


Figure 5: Transparency percentage of combination of decalcifying agents (nitric acid or formic acid) and clearing agents (methyl salicylate or eugenol)

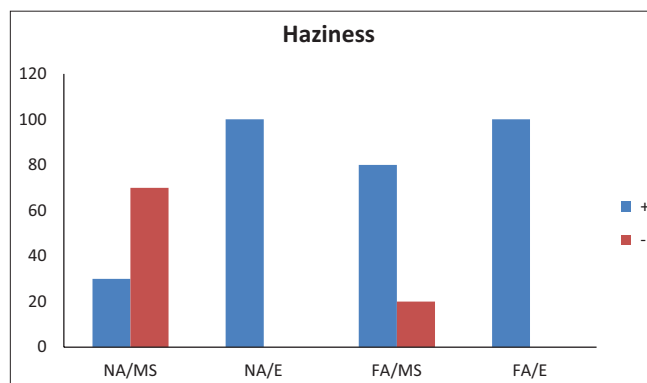


Figure 6: Haziness percentage of various study groups

is important to maintain the original form teeth. The drawback of this technique was some damage to the tooth structure because of the decalcification by acid.<sup>[19]</sup>

Other disadvantages observed with formic acid was decalcification resulted in post-decalcification clogging of the root canal, while those samples decalcified with nitric acid did not showed clogging. The disadvantage observed with nitric acid was yellowish discoloration of the teeth.

Shivapathasundharam *et al.* compared the efficacy of various clearing agents such as xylene, benzene, methyl salicylate, and eugenol. They further tried to select a suitable dye for the demonstration of root canal anatomy and have compared the efficacy of various mounting media such as D.P.X. medium, Canada balsam, and commercial plastic dissolved in benzene, in preserving the cleared state. The results of their study indicated that eugenol is a superior clearing agent and that oil-based dyes are better suited for root canal demonstration.<sup>[20]</sup> However, in our study, it was found that Methyl Salicylate was a better clearing agent than eugenol.

The results of our study revealed that in clearing agents, methyl salicylate (MS) showed better transparency, lower level of haziness, and good canal morphology as compared to eugenol (E). On the other hand, samples cleared by eugenol showed good root canal morphology but with lesser transparency and higher degree of

haziness and yellowing of the samples, more so when used in combination with nitric acid.

## CONCLUSION

Combination of nitric acid used with methyl salicylate proved to be the best for the preparation of the transparent tooth model. Transparent tooth model is an inexpensive and excellent technique for demonstration of three-dimensional view of root canal morphology and can be used as a teaching aid for undergraduate students.

## REFERENCES

1. Fisher DE, Ingersoll, Bucher JF. Anatomy of the pulpal canals: Three dimensional visualization. *J Endod* 1975;1:22-5.
2. Buchbinder M. A non-shrinking root canal material. *Dent Cosmos* 1931;73:14-6.
3. Robertson DC, Joel Leeb I. The evaluation of a transparent tooth model system for the evaluation of endodontically filled teeth. *J Endod* 1982;8:317-21.
4. Hess W, Zurcher E. The anatomy of the root canals of the teeth of the permanent and deciduous dentition. New York: Williumwood and Company; 1925.
5. Sommer RF, Ostrander FD, Crowley MC. Clinical endodontics. Philadelphia: W.B Saunders's Publication; 1956. p. 5-40.
6. Rosenteil E. Transparent model teeth with pulps. *Dent Digest* 1957;63:154.
7. Barker BC, Locket BC, Parsons KC. The demonstration of root anatomy. *Aust Dent J* 1969;14:37-41.
8. Bancroft DJ, Stevens A, Turner DR. Theory and practice of histological technique. London: Churchill Livingstone; 1996.
9. Kaffe I, Kaufman A, Littner MM, Lazarson A. Radiographic study of root canal system of mandibular anterior teeth. *Int Endod J* 1985;18:253-9.
10. Mauger MJ, Schindler WG, Walker WA. An evaluation of canal morphology at different levels of root resection in mandibular incisors. *J Endod* 1998;24:607-9.
11. Robertson D, Leeb J, McKee M, Brewer E. A clearing technique for the study of root canal systems. *J Endod* 1980;6:421-4.
12. Gulabivala K, Opananon A, Ng Y-L, Alavi A. Root and canal morphology of Thai mandibular molars. *Int Endod J* 2002;35:56-62.
13. Weine FS, Healey HJ, Gerstein H, Evanson L. Canal configuration in mesio-buccal root of maxillary first molar and its endodontic significance. *Oral Surg Oral Med Oral Pathol* 1969;28:419-25.
14. Tagger M. Clearing of teeth for study and demonstration of pulp. *J Dent Educ* 1976;40:172-4.
15. Tagger M, Tamse A, Katz A, Tagger E. An improved method of three-dimensional study of apical leakage. *Quintessence Int Dent Dig* 1983;10:981-98.
16. Al Shalabi RM, Omer OE, Glennon J, Jennings M, Claffey NM. Root canal anatomy of maxillary first and second permanent molars. *Int Endod J* 2000;33:405-14.
17. Hasselgren G, Tronstad L. The use of transparent teeth in the teaching of preclinical Endodontists. *J Endod* 1975;1:278-80.
18. Verma M. Clearing Technique and its potential applications-An *In Vitro* study. *Journal of Indian Dental Association* 2011;5:1122-3.
19. Culling CFA, Allison RT, Barr WT. Cellular Pathology Techniques. 4<sup>th</sup> edition (1985) Butterworths & Co., London. P. 412-13.
20. Shivapathasundharam B, Berti AE. Transparent tooth model system. An aid in the study of root canal anatomy. *Indian J Dent Res* 2000;11:89-94.

**How to cite this article:** Gupta B, Tiwari B, Raj V, Kashyap B, Chandra S, Dwivedi N. Transparent tooth model: A study of root canal morphology using different reagents. *Eur J Gen Dent* 2014;3:66-70.  
**Source of Support:** Nil, **Conflict of Interest:** None declared.