

## Pigmented natal teeth

Nesrin Saruhan, Tevfik Demirci<sup>2</sup>, Ertan Yalcin

Departments of Oral and Maxillofacial Surgery, <sup>1</sup>Paediatric Dentistry, Faculty of Dentistry, Atatürk University, Erzurum, Turkey

Address for correspondence:

Res. Assist. Nesrin Saruhan,  
Department of Oral and Maxillofacial  
Surgery, Faculty of Dentistry, Ataturk  
University, Erzurum, Turkey.  
E-mail: dt\_nesrin@yahoo.com

### ABSTRACT

The presence of teeth at birth or within a month post-delivery is a rare condition. The exact etiology has not been proved yet, but there is a correlation between natal teeth and hereditary, environmental factors and some syndromes. A newborn 3-day-old male, with two mandibular incisor natal teeth was examined. The teeth were mobile and were extracted because of the fear of aspiration and refusal to feed. In this report, we present a case of pigmented natal teeth in mandible and treatment with extraction.

### Key words

Mandibular incisor, natal teeth, pigmentation

### INTRODUCTION

Natal and neonatal teeth were classified by Massler and Savara, if teeth observed at birth are considered as natal teeth, if teeth observed within a month as neonatal teeth.<sup>[1]</sup>

The presence of teeth at birth or within after a month is a rare occasion.<sup>[2-5]</sup> The incidence of natal or neonatal teeth is 1:2000-1:3500.<sup>[6]</sup>

The exact etiology has not been elucidated yet. Many theories have been described about the cause of the occurrence of natal teeth. One of them includes dietary deficiencies or hypovitaminosis due to poor maternal health, endocrine disease and pyelitis during pregnancy.<sup>[7]</sup> Another theory apply to hormonal stimulation, meaning the excessive secretion of pituitary, thyroid or gonads.<sup>[1]</sup>

Natal and neonatal teeth are defined as conical or normal in size and shape, yellowish, with hypoplastic enamel and dentin and poor or absent root development.<sup>[3,8,9]</sup> The hypoplastic enamel might be associated with gingival covering and has a tendency to discolor. The incomplete

root formation is the reason for the great mobility of the natal and neonatal teeth.<sup>[6,10]</sup>

### CASE REPORT

A 3-day-old male infant was consulted to our department with two natal teeth in the lower jaw since birth, continuous crying and refusal to suck milk.

Clinical examination showed that pigmented two crowns of the teeth in the mandibular anterior region showing Grade III mobility [Figures 1 and 2]. The crowns size and gingiva were normal and natal teeth were diagnosed by clinical examination.

Immediate extraction is the treatment choice of natal teeth. Hence, these teeth were extracted under topical local anesthesia. The extracted teeth had a crown, but were without roots [Figure 3]. Patient was assessed after 3 days and the healing was found to be uneventful.

### DISCUSSION

The definitive etiology of natal teeth has not been explained yet.<sup>[6]</sup> Natal teeth formation is seen as a probable cause hereditary. Zhu and King have reported natal teeth as a familiar trait in 8-62% of cases.<sup>[8]</sup> Bodenhoff and Gorlin informed family association in 14.5% of cases,<sup>[11]</sup> while Kates *et al.* found a positive family history in 7 out of 38 cases of natal and neonatal teeth.<sup>[10]</sup>

Usually, the reason is superior placement of the tooth germ during the perinatal period but in most cases, a specific pathogenic factor cannot be determined.<sup>[12]</sup>

#### Access this article online

##### Quick Response Code:



Website:  
www.ejgd.org

DOI:  
10.4103/2278-9626.126218

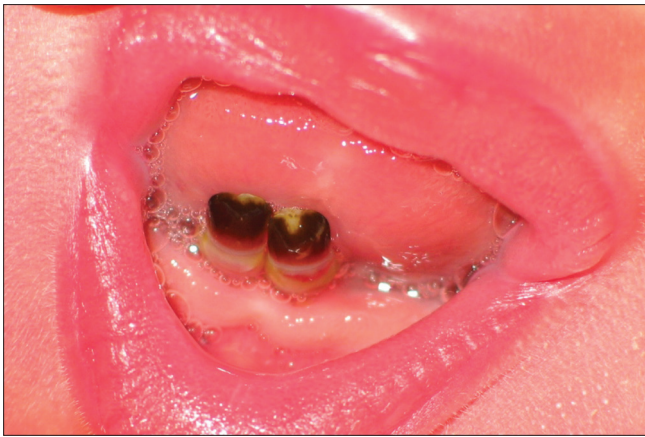

Figure 1: Intraoral appearance of natal teeth

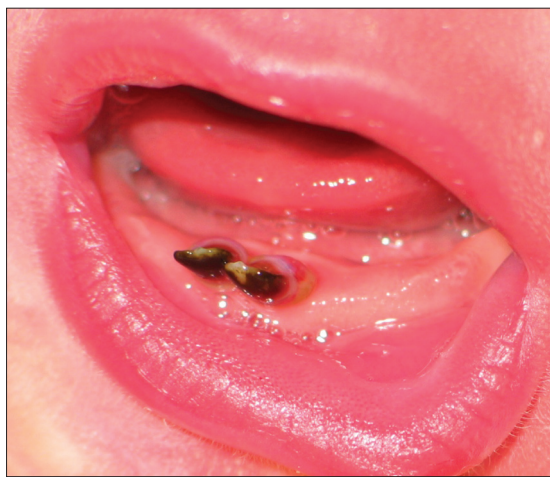

Figure 2: Grade III mobility

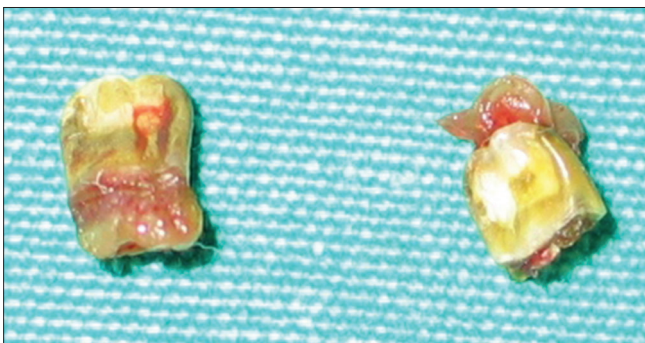


Figure 3: Extracted natal teeth

More than two teeth eruption is rare. Nevertheless, Masatomi *et al.* reported an 18-month-old Japanese boy with 14 natal teeth,<sup>[12]</sup> Gonçalves *et al.* presented the case of a newborn with 12 natal teeth<sup>[13]</sup> and Portela *et al.* reported a newborn with 11 natal teeth.<sup>[14]</sup>

Concerning clinical characteristics, the most affected teeth are the lower primary central incisors (85%), followed by the maxillary incisors (11%), mandibular canines and molars (3%) and maxillary canines and molars (1%).<sup>[8]</sup>

Hooley found that 67% of natal and neonatal teeth would exfoliate early, due to insufficient root formation and mobility.<sup>[15]</sup> Bjuggren published a report of 121 cases; he found that 38% of the natal and neonatal teeth exfoliated in the 1<sup>st</sup> year of life.<sup>[11]</sup>

Neonatal teeth extraction is usually a simple procedure. It is very important to recall preventions when the infant is younger than 10 days of life. Vitamin K administration is indicated for hemorrhage prevention.<sup>[16]</sup>

Many factors are taken into consideration in planning the treatment of natal and neonatal teeth. If the teeth are asymptomatic and not hinder to eating, treatment do not require.<sup>[1]</sup>

There is no need to remove the teeth if it is in a good way supported.<sup>[13,17]</sup> If the tooth is supernumerary or has a high mobility, poorly developed or is related with soft tissue growth or if it interferes with nasoalveolar molding or presents an abscess, the treatment of the option is extraction.<sup>[18,19]</sup>

Riga-Fede disease is known as a complication that is common with natal teeth and ulceration of the tip or the ventral surface of the tongue. The ulceration consist after repetitive tongue thrusting not only in newborns, but also to elder infants with the eruption of the primary mandibular central incisors and in children with familiar dysautonomia.<sup>[20]</sup>

As a result, natal and neonatal teeth are rare conditions in infancy. The exact etiology has not been proved yet. Management of natal and neonatal teeth should consist of concern to prevent any complication, to make early diagnosis and supply adequate treatment. Treatment and periodic follow-up should be conducted by a pediatric dentist.

## REFERENCES

1. Massler M, Savara BS. Natal and neonatal teeth; a review of 24 cases reported in the literature. *J Pediatr* 1950;36:349-59.
2. Alvarez MP, Crespi PV, Shanske AL. Natal molars in Pfeiffer syndrome type 3: A case report. *J Clin Pediatr Dent* 1993;18:21-4.
3. Rusmah M. Natal and neonatal teeth: A clinical and histological study. *J Clin Pediatr Dent* 1991;15:251-3.
4. Chawla HS, Subba Reddy VV. A follow-up study of 25 cases of natal/ neo-natal teeth. *J Indian Soc Pedod Prev Dent* 1988;6:57-61.
5. Barfiwala DR. Natal and neonatal teeth: A review of 50 cases. *J Indian Soc Pedod Prev Dent* 1996;14:21-3.
6. Markou IK, Arhakis A. Natal and neonatal teeth: A review of literature. *Balk J Stom*, 2012;16:132-140.
7. Vucicevic Boras V, Mohamad Zaini Z, Savage NW. Supernumerary tooth with associated dentigerous cyst in an infant. A case report and review of differential diagnosis. *Aust Dent J* 2007;52:150-3.
8. Zhu J, King D. Natal and neonatal teeth. *ASDC J Dent Child* 1995;62:123-8.

9. Galassi MS, Santos-Pinto L, Ramalho LT. Natal maxillary primary molars: Case report. *J Clin Pediatr Dent* 2004;29:41-4.
10. Kates GA, Needleman HL, Holmes LB. Natal and neonatal teeth: A clinical study. *J Am Dent Assoc* 1984;109:441-3.
11. Bodenhoff J, Gorlin RJ. Natal and neonatal teeth: Folklore and fact. *Pediatrics* 1963;32:1087-93.
12. Masatomi Y, Abe K, Ooshima T. Unusual multiple natal teeth: Case report. *Pediatr Dent* 1991;13:170-2.
13. Gonçalves FA, Birman EG, Sugaya NN, Melo AM. Natal teeth: Review of the literature and report of an unusual case. *Braz Dent J* 1998;9:53-6.
14. Portela MB, Damasceno L, Primo LG. Unusual case of multiple natal teeth. *J Clin Pediatr Dent* 2004;29:37-9.
15. Jasmin JR, Jonesco-Benaiche N, Muller-Giamarchi M. Natal and neonatal teeth. Management. *Ann Pediatr (Paris)* 1993;40:640-1.
16. Brandt SK, Shapiro SD, Kittle PE. Immature primary molar in the newborn. *Pediatr Dent* 1983;5:210-3.
17. Nik-Hussein NN. Natal and neonatal teeth. *J Pedod* 1990;14:110-2.
18. Ziai MN, Bock DJ, Da Silveira A, Daw JL. Natal teeth: A potential impediment to nasoalveolar molding in infants with cleft lip and palate. *J Craniofac Surg* 2005;16:262-6.
19. Singh S, Subba Reddy VV, Dhananjaya G, Patil R. Reactive fibrous hyperplasia associated with a natal tooth. *J Indian Soc Pedod Prev Dent* 2004;22:183-6.
20. Slayton RL. Treatment alternatives for sublingual traumatic ulceration (Riga-Fede disease). *Pediatr Dent* 2000;22:413-4.

**How to cite this article:** Saruhan N, Demirci T, Yalcin E. Pigmented natal teeth. *Eur J Gen Dent* 2014;3:79-81.

**Source of Support:** Nil, **Conflict of Interest:** None declared.