

Comparative evaluation of different obturation techniques in primary molars: An *in vivo* study

Monika Khubchandani, M. Sudhindra Baliga, Sudhir S. Rawlani¹, Shivlal M. Rawlani², Khushboo M. Khubchandani³, Nilima Thosar

Departments of Pedodontics and Preventive Dentistry and ¹Oral Medicine Diagnosis and Radiology, Sharad Pawar Dental College and Hospital, Wardha, ²Department of Public Health Dentistry, VSPM Dental College and Hospital, ³Department of Pediatrics, Government Medical College, Nagpur, Maharashtra, India

Address for correspondence:

Dr. Monika Khubchandani,
Department of Pedodontics and
Preventive Dentistry, Sharad Pawar
Dental College and Hospital, Wardha,
Maharashtra, India.
E-mail: monika.khubchandani
@gmail.com

ABSTRACT

Aim: The study was undertaken to compare the filling quality of a 30 gauge cannula (NaviTip™, Ultradent Inc., South Jordan, UT, USA) used on a pressure syringe with a lentulospiral in primary molars. **Materials and Methods:** Thirty mandibular first and second primary molars in 28 healthy children of both sexes in the age group of 4–8 years were included in the study. All pulpectomy procedures were performed by one investigator. Before obturation, the subjects were randomly selected for the two obturation techniques. Effectiveness of the two obturation techniques was assessed by three independent evaluators using postoperative radiographs taken immediately after each obturation. Filling quality was determined by analyzing presence or absence of voids, extent of fill and apical seal. **Results:** The results of the obturation quality of the tested techniques were collected and statistically analyzed using chi-square test. There was a significant difference for the presence of voids between the two groups. NaviTip group showed the best results for the number of voids (mesial $\chi^2 = 3.567$, $P = 0.0497$) (distal $\chi^2 = 5.058$, $P = 0.0269$). The lentulospiral group showed more number of optimal fillings. When results were compared in terms of apical seal, NaviTip showed better apical seal but statistically no difference ($P > .05$). **Conclusion:** Lentulospiral produced the best results in terms of length of obturation, while NaviTip syringe was efficient enough in controlling voids and produced the best results for apical seal.

Key words

Obturation techniques, primary teeth, pulpectomy

INTRODUCTION

Premature loss of deciduous teeth continues to be common, despite efforts to emphasize prevention of caries.^[1] The best space maintainer in both primary and mixed dentition is the primary tooth itself, not only because of the clinical crown but also due to the presence of roots and periodontium that guides the eruption of the succedaneous permanent tooth. Recognizing the importance of the primary teeth, pediatric dentistry has endeavored to preserve these teeth until they are

ready to be replaced.^[2] Thus, primary tooth pulpectomy should be done as a routine procedure after proper examination and diagnosis confirms its necessity. The term pulpectomy only refers to removal of pulp, but in practice, it has come to mean removal of caries along with inflamed/necrotic material from the pulp chamber and root canal/canals, followed by obturation of the root canal/canals using resorbable root canal filling material.^[3]

This is an open access article distributed under the terms of the Creative Commons Attribution-NonCommercial-ShareAlike 3.0 License, which allows others to remix, tweak, and build upon the work non-commercially, as long as the author is credited and the new creations are licensed under the identical terms.

For reprints contact: reprints@medknow.com

How to cite this article: Khubchandani M, Baliga MS, Rawlani SS, Rawlani SM, Khubchandani KM, Thosar N. Comparative evaluation of different obturation techniques in primary molars: An *in vivo* study. Eur J Gen Dent 2017;6:42-7.

Access this article online

Quick Response Code:



Website:
www.ejgd.org

DOI:
10.4103/2278-9626.198611

Several different products have been reported as successful filling materials for pulpectomies of primary teeth. Among the most common materials used are zinc oxide eugenol (ZOE), iodoform, calcium hydroxide, endoflas, and vitapex.^[4-9] Currently, ZOE paste is one of the most widely used materials for primary tooth pulpectomies.^[1,10,11]

Primary endodontic techniques provide treatment options to save teeth with advanced pulpal pathosis resulting from caries or trauma. The most common of these techniques use the pressure syringe and lentulospiral.^[12] Other techniques include condensing a thick mixture of the paste with an endodontic plugger or small amalgam condenser. The packing method has a high success rate in long, straight canals, such as those of primary anterior teeth. However, lentulospiral mounted on a slow-speed handpiece is superior in filling both straight and curved narrow canals.^[6]

A thin, flexible metal tip has been introduced to the market to deliver root canal sealers (NaviTip™, Ultradent Inc., South Jordan, UT, USA). NaviTips come in different lengths, and a rubber stop may be adapted to it so as to provide controlled delivery of the material to the apex.^[4]

Various studies have investigated different obturation techniques for primary teeth *in vivo* and *in vitro*. Most assessments, however, were limited to the anterior primary teeth. To fill the gap in our knowledge of the effectiveness of root canal filling techniques, the present study was planned to evaluate and compare the filling quality of two different delivery systems for root canal obturation, that is, motor-driven lentulospiral and a flexible 30 gauge stainless steel cannula (Navitip) used on a pressure syringe for pulpectomized primary molars.

MATERIALS AND METHODS

The study population consisted of 28 healthy, cooperative children (4–8 years) who had at least 1 infected primary mandibular molar indicated for pulpectomy. After an adequate explanation concerning the experimental rationale, clinical procedures and possible risks, parents of all volunteers were asked to read and sign consent form explaining the research protocol. Both the consent form and the research protocol were reviewed and approved by the ethical committee. A full-mouth dental examination and age-appropriate radiographs were taken of tooth with possible indication for pulpectomy before the start of the clinical study. 30 primary mandibular molars were included in this study if any one or more of the following was noted: History of spontaneous pain, presence of sinus tract, no pulp tissue remaining when the pulp chamber was accessed, pus discharge from the canal, and presence of inter-radicular or periapical radiolucency.

Teeth with internal resorption, physiologic root resorption greater than one-third of the root length, teeth which were unrestorable and patients with compromised general health were excluded from the study.

All pulpectomy procedures were performed by one investigator who was given adequate training before commencement of the study. The teeth were isolated with rubber dam after local anesthesia. Access to the pulp chamber was gained with a sterile round bur (ISO no. 001/012) in a high-speed handpiece. The exposed coronal pulp was amputated using a spoon excavator and irrigated with saline to view the orifice of the radicular pulp. Based on the radiographic measurement, the appropriate root canal stopper was placed in position on the broach and pulp was extripated from the root canals. Biomechanical preparation of the root canals was initiated with 15 size headstrom file used in pull back action and then sequentially increased up to size 35. The instrumentation length was kept 1 mm short of the radiographic apex. The root canal was irrigated with 1 ml of 3% sodium hypochlorite after each instrumentation size followed by 2 ml of normal saline. Following instrumentation, a final irrigation was made with physiologic saline solution and the canals were dried with sterile absorbent paper points before obturation. The teeth were randomly divided into two groups as:

- Group I: Fifteen teeth obturated using lentulospiral mounted in slow-speed handpiece.
- Group II: Fifteen teeth each obturated using NaviTip™.

The obturation material used was ZOE (PULPDENT Root canal sealer kit, PULPDENT Corporation Watertown, MA, USA) with consistencies as follows:

- Group I: ZOE one scoop
- Eugenol two drops
- Group II: ZOE one scoop
- Eugenol three drops.

Group I: A homogeneous mixture of ZOE was carried into the root canals using lentulospiral mounted to a slow-speed contra-angle handpiece. A rubber stopper was adjusted based on the radiographic measurement, staying 1 mm short of the radiographic apex. When backfill of the material into the pulp chamber occurred, the canal was assumed to be filled and the lentulospiral was withdrawn. Similar procedure was repeated in other canals.

Group II: NaviTip was used in conjunction with endodontic pressure syringe. The technique of obturating root canals with NaviTip was similar to the technique employed by Guelmann *et al.*^[4] The freshly mixed ZOE was loaded into the syringe and was expressed through the NaviTip by rotating the plunger of the syringe. After the rubber stopper was adjusted to the predetermined measurement, the metal tip was placed into the canal 1 mm short of the apex and the material was expressed.

Once backfill of the material occurred, the canal was assumed to be filled. Similar procedure was repeated in other canals.

Effectiveness of the two obturation techniques were assessed using postoperative intraoral periapical (IOPA) radiographs taken immediately after each obturation. The IOPA radiographs were viewed in an X-ray viewer with a magnifying lens. Three evaluators, blinded to the filling technique, assessed the presence of voids, extent of fill and apical seal in mesial and distal roots separately based on the following criteria.

- Score 0 - Complete absence of voids.
- Score 1 - Presence of one void.
- Score 2 - Presence of two voids.
- Score 3 - Presence of three voids.
- Score 4 - Presence of four voids.
- Score 5 - Presence of five voids.

The extent of fill was scored from grade A to D based on the following criteria:

- Grade A - Less than one-half of the canal obturated
- Grade B - Greater than one-half but less than optimal fill
- Grade C - Optimal fill
- Grade D - Extrusion of material beyond apex
- Grade D was a modification of the grading criteria employed by Subba Reddy and Shakunthala.^[5]

To evaluate the apical seal, postoperative IOPA radiographs were exposed for each tooth with 1 mm grid attached. All measurements were made by counting the squares shown on each radiograph. Using a standard Boley gauge, the extent of obturation in the mesial and distal roots was measured separately. All measurements were rounded to the nearest millimeter and were subtracted from the length of the respective root canals measured from the floor of the pulp chamber to the root apex. The difference in the measurements was considered to determine the adequacy of the apical seal.

The evaluators reviewed each radiograph individually for the presence of voids and extent of fill. If there was disagreement, then the case was reviewed again to reach a final judgment. If there was still disagreement, then

the lower score/grade was considered. The results were then tabulated and statistically analyzed.

RESULTS

A total of 28 healthy children (14 males and 14 females) with a mean ± standard deviation age of 5.3 ± 1.2 and a range of 4–8 years, received thirty single or multiple visit ZOE pulpectomies in primary molars. Of these 28 children, 14 (7 males and 7 females) with a mean age of 4.7 ± 0.58 received 14 pulpectomies in which ZOE was inserted into the canals with a lentulospiral mounted in a slow-speed handpiece. Another 14 patients (7 males and 7 females) with a mean age of 4.4 ± 1.1 received 16 ZOE pulpectomies in which the obturation material was inserted into the canals by NaviTip. Chi-square analysis was applied to the data to compare the two techniques with respect to the presence/absence of voids, extent of fill, and apical seal. For the presence of voids, Chi-square test detected a statistically significant difference between the two groups (mesial $\chi^2 = 3.567$, $P = 0.0497$) (distal $\chi^2 = 5.058$, $P = 0.0269$) [Table 1]. The difference for extent of fill was statistically insignificant (mesial $\chi^2 = 3.9960$, $P = 0.136$) (distal $\chi^2 = 0.7857$, $P = 0.675$) [Table 2]. Chi-square analysis for apical seal revealed that there was a statistically insignificant difference among the two obturation techniques (mesial $\chi^2 = 1.2919$, $P = 0.256$) (distal $\chi^2 = 1.2919$, $P = 0.256$) [Table 3].

DISCUSSION

Many investigations have evaluated and compared the success rate of different root canal filling techniques used for primary teeth. *In vivo* evaluation of the use of the NaviTip system to fill root canals in primary teeth, however, has been investigated in very few studies. For this reason, the authors carried out this *in vivo* investigation to compare the efficiency of NaviTip system and lentulospiral mounted in a slow-speed handpiece at providing optimal filling for the root canal of primary molars.

The ultimate goals of root filling are to adequately adapt the paste to the canal walls, completely fill the

Table 1: Presence of voids

	Mesial (%)			Distal (%)		
	Lentulospiral Group	NaviTip Group	Total	Lentulospiral Group	NaviTip Group	Total
0	2 (13.3)	8 (53.3)	10 (33.3)	2 (13.3)	9 (60.1)	11 (36.6)
1	9 (60.1)	6 (40.0)	15 (50.0)	10 (66.7)	4 (26.6)	14 (46.7)
2	4 (26.6)	1 (6.7)	5 (16.7)	3 (20.0)	2 (13.3)	5 (16.7)
Total	15 (100)	15 (100)	30	15 (100)	15 (100)	30
χ^2	3.567			5.058		
P	0.0497, S			0.0269, S		

S–Significant

Table 2: Extent of fill

	Mesial (%)			Distal (%)		
	Lentulospiral Group	NaviTip Group	Total	Lentulospiral Group	NaviTip Group	Total
A	0	0	0	0	0	0
B	7 (46.3)	4 (26.7)	11 (36.7)	5 (33.3)	3 (20)	8
C	6 (40)	4 (26.7)	10 (33.3)	4 (26.7)	4 (26.7)	8
D	2 (13.3)	7 (46.3)	9 (30)	6 (40)	8 (53.3)	14
Total	15	15	30	15	15	30
χ^2	3.9960			0.7857		
P	0.13, NS			0.67, NS		

NS – Not significant

Table 3: Apical seal

Apical seal	Mesial (%)			Distal (%)		
	Lentulospiral Group	NaviTip Group	Total	Lentulospiral Group	NaviTip Group	Total
Adequate	4 (26.7)	7 (46.3)	11 (36.7)	8 (53.3)	11 (73.3)	19
Inadequate	11 (73.3)	8 (53.3)	19	7 (46.3)	4 (26.7)	11 (36.7)
Total	15	15	30	15	15	30
χ^2	1.2919			1.2919		
P	0.25, NS			0.25, NS		

NS – Not significant

root throughout its length (apical sealing without overfilling), and avoid the creation of voids or gaps in the paste.^[13] Different laboratory approaches have been used to evaluate root canal filling quality, such as the penetration of dye, bacteria, or radioisotopes, clearing techniques following tooth sectioning, and radiographic assessment.^[12,14]

Clinical radiography is minimally invasive and the only clinical way to evaluate the quality of treatment.^[15] Hence, we used this technique to compare two different root canal filling methods.

Presence of voids in the obturation is one predicament which might provide pathways for leakage and the possibility of microorganism and toxin retention, leading to post-treatment failures.^[15-17] Factors that influence the location and size of the voids include the type, viscosity, and consistency of the paste, the method used to apply the paste, and operator skill and experiences.^[4,18]

The results of the present study showed that in Group I where the root canals were filled using lentulospiral, presence of voids was frequently observed [Figure 1]. It was probably due to thicker consistency (zinc oxide powder one scoop, eugenol two drops) smearing action of ZOE and repeated removal and reinsertion of the lentulospiral during the filling procedure. Since all the small irregularities in the canal cannot be completely obliterated, small air bubbles might get trapped creating voids.^[5,19-21] The NaviTip along with pressure syringe showed fewest number of voids in the obturation. The

possible reason could be the thin flexible metal tip provided better reach into the curved, narrow canals close to the apex and injects paste rapidly and uniformly, hence causing lesser voids. Similar findings were reported by Dandashi *et al.*, who found that the pressure syringe resulted in fewest voids but reported to be the most complex and time-consuming technique. Guelmann also found the least amount of voids with the NaviTip system compared to the lentulospiral. In another study by Subba Reddy and Shakunthala, presence of void was found to be highest with lentulospiral (30%), followed by pressure syringe (15%).

When both the techniques were compared in terms of extent of fill, it was observed that in Group I (Lentulospiral group), 40% of the mesial canals were optimally filled [Figure 2]. A total of 46.3% canals showed less than optimal fill [Figure 3]; and 13.3% of canals were overfilled [Figure 4]. However, in distal root canals, 26.7% were optimally filled, 33.3% showed less than optimal fill, and 40% canals were overfilled. In the present study, more number of overfilled canals were observed with the Navitip system. This may be related to excessive pressure placed while placing the material into the canal when the quarter turn of the screw was made. Furthermore, relatively thinner consistency of the ZOE mix (Zinc oxide powder one scoop, eugenol three drops) can bear the influence on the extent of fill thus leading to apical extrusion of the material.

In Group II, where NaviTip was used in conjunction with pressure syringe for root canal obturation, it was observed

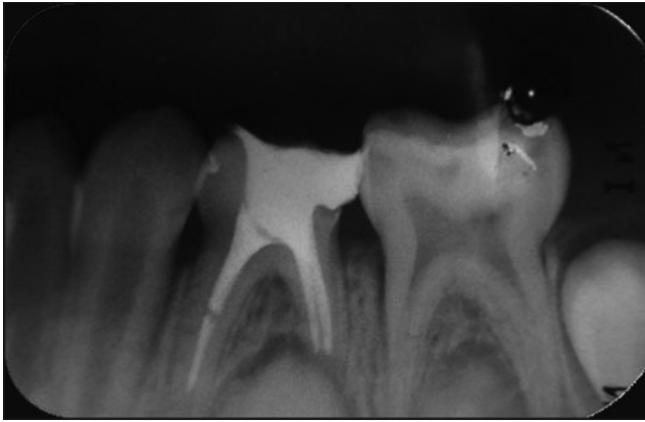


Figure 1: Presence of voids in the obturation

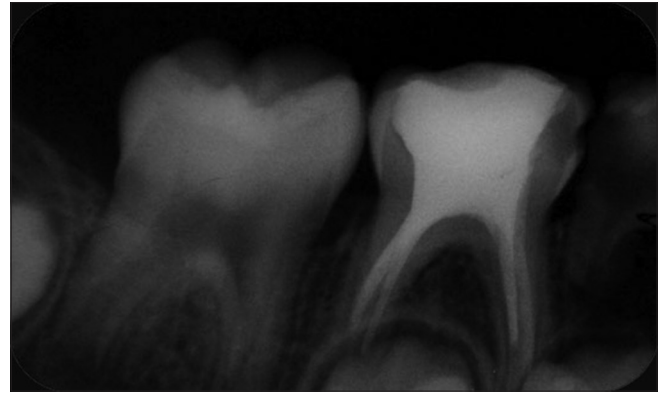


Figure 2: Extent of fill; Grade C in mesial and Grade B in distal root canals

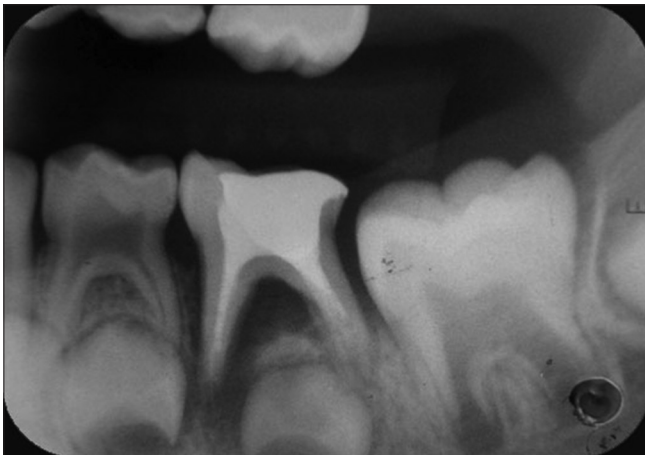

Figure 3: Extent of fill, Grade C

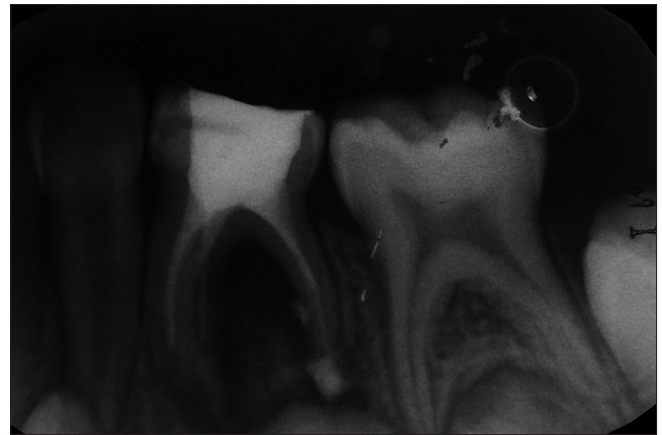


Figure 4: Extent of fill; Grade D in distal root canal

that 26.7% of the mesial and distal canals were optimally filled, the same percentage of the canals showed less than optimal fill in mesial root canals; however, 46.3% of mesial canals showed overfilling. In distal roots, 20% of the canals showed less than optimal fill and 53.3% of the root canals showed overfilling. Similar findings were observed by Aylard *et al.*,^[6] who reported lentulospiral to be the most effective technique for filling both the straight and curved canals. In this study, lentulospiral showed more number of optimal fillings with minimal extrusion of the material beyond the root apex, probably owing to the adequate flexibility of the instrument and thicker consistency of the mix being used. This was in accordance with the findings of Camps *et al.*^[22] Some studies^[4,11] have shown higher frequency of overfill with the lentulospiral technique. The discrepancies between our results and those of other studies probably reflect differences in the type of teeth, sample size, tip thickness, and operator experience.

When reports of the clinical investigation were analyzed for apical seal, no significant difference was observed among the two techniques ($P = 0.25$). This is consistent with the study by Dandashi *et al.*, who found no

statistically significant differences with respect to apical seal ($P = 0.24$).

In this study, assessment of voids was done using IOPA radiograph, which gave two-dimensional shadows, so it was difficult to find the exact location and number of voids present; this can be a drawback of our study. In a previous study by Dandashi *et al.*, voids were assessed using lateral and anterior/posterior radiographs; however, since it was an *in vitro* study, multiple views were taken. In the present study, multiple views were not possible.

The different consistencies of the ZOE mixture used in the present investigation were attributed to the physical limitations of two different techniques. Similar consistencies were employed in a previous study^[12] using endodontic plugger, motor-driven lentulospiral and pressure syringe.

Based on the clinical and radiographic evaluation, it was observed that NaviTip system demonstrated good apical seal and was efficient enough in controlling voids. Furthermore, the operator could negotiate the curved canals due to high flexibility of the tip. However, according to operator's experience, the technique was

relatively complex as the pressure syringe needs to be disassembled to load additional filling material. In addition, it requires immediate cleaning to prevent hardening of the filling material. On the other hand, lentulospiral showed more number of optimal fillings and was easy to use; however, the filling quality was compromised due to more number of voids present in the obturation.

CONCLUSION

Within the parameters of the present study and based on the standardized radiographic criteria, we conclude that both the traditional lentulospiral and the NaviTip system can be effectively used for obturation in primary dentition. NaviTip can be recommended as an alternative to other conventional obturation techniques.

Financial support and sponsorship

Nil.

Conflicts of interest

There are no conflicts of interest.

REFERENCES

1. Trairatvorakul C, Chunlasikaiwan S. Success of pulpectomy with zinc oxide-eugenol vs calcium hydroxide/iodoform paste in primary molars: A clinical study. *Pediatr Dent* 2008;30:303-8.
2. da Costa CC, Kunert GG, da Costa Filho LC, Kunert IR. Endodontics in primary molars using ultrasonic instrumentation. *J Dent Child (Chic)* 2008;75:20-3.
3. Bhandari SK, Anita, Prajapati U. Root canal obturation of primary teeth: Disposable injection technique. *J Indian Soc Pedod Prev Dent* 2012;30:13-8.
4. Guelmann M, McEachern M, Turner C. Pulpectomies in primary incisors using three delivery systems: An *in vitro* study. *J Clin Pediatr Dent* 2004;28:323-6.
5. Subba Reddy VV, Shakunthala B. Comparative assessment of three obturation techniques in primary molars – An *in-vivo* study. *Endodontology* 1997;9:13-6.
6. Aylard SR, Johnson R. Assessment of filling techniques for primary teeth. *Pediatr Dent* 1987;9:195-8.
7. O'Riordan MW, Coll J. Pulpectomy procedure for deciduous teeth with severe pulpal necrosis. *J Am Dent Assoc* 1979;99:480-2.
8. Guideline on Pulp Therapy for Primary and Immature Permanent Teeth. Reference Manual 2016;37:244-52.
9. Ozalp N, Saroglu I, Sönmez H. Evaluation of various root canal filling materials in primary molar pulpectomies: An *in vivo* study. *Am J Dent* 2005;18:347-50.
10. Gupta S, Das G. Clinical and radiographic evaluation of zinc oxide eugenol and metapex in root canal treatment of primary teeth. *J Indian Soc Pedod Prev Dent* 2011;29:222-8.
11. Bawazir OA, Salama FS. Clinical evaluation of root canal obturation methods in primary teeth. *Pediatr Dent* 2006;28:39-47.
12. Dandashi MB, Nazif MM, Zullo T, Elliott MA, Schneider LG, Czonstkowsky M. An *in vitro* comparison of three endodontic techniques for primary incisors. *Pediatr Dent* 1993;15:254-6.
13. Sari S, Okte Z. Success rate of Sealapex in root canal treatment for primary teeth: 3-year follow-up. *Oral Surg Oral Med Oral Pathol Oral Radiol Endod* 2008;105:e93-6.
14. Dultra F, Barroso JM, Carrasco LD, Capelli A, Guerisoli DM, Pécora JD. Evaluation of apical microleakage of teeth sealed with four different root canal sealers. *J Appl Oral Sci* 2006;14:341-5.
15. Aghdasi MM, Asnaashari M, Aliari A, Fahimipour F, Soheilifar S. Conventional versus digital radiographs in detecting artificial voids in root canal filling material. *Iran Endod J* 2011;6:99-102.
16. Kositbowornchai S, Hanwachirapong D, Somsopon R, Pirmsinthavee S, Sooksuntisakoonchai N. *Ex vivo* comparison of digital images with conventional radiographs for detection of simulated voids in root canal filling material. *Int Endod J* 2006;39:287-92.
17. Bodanezi A, Munhoz Ede A, Bernardineli N, Capelozza AL, de Moraes IG, Bramante CM. Radiographic analysis of root canal fillings: Influence of two sealers on the perception of voids. *Braz Dent J* 2010;21:142-7.
18. Kahn FH, Rosenberg PA, Schertzer L, Korthals G, Nguyen PN. An *in-vitro* evaluation of sealer placement methods. *Int Endod J* 1997;30:181-6.
19. Torres CP, Apicella MJ, Yancich PP, Parker MH. Intracanal placement of calcium hydroxide: A comparison of techniques, revisited. *J Endod* 2004;30:225-7.
20. Serene TP, Vesely J, Boackle RJ. Complement activation as a possible *in vitro* indication of the inflammatory potential of endodontic materials. *Oral Surg Oral Med Oral Pathol* 1988;65:354-7.
21. de Faria-Júnior NB, Massi S, Croti HR, Gutierrez JC, Dametto FR, Vaz LG. Comparative assessment of the flow rate of root canal sealers. *Rev Odontol Ciênc* 2010;25:170-3.
22. Camps J, Pommel L, Bukiet F, About I. Influence of the powder/liquid ratio on the properties of zinc oxide-eugenol-based root canal sealers. *Dent Mater* 2004;20:915-23.