

Transcranial Doppler-guided cerebral blood flow augmentation resulting in near complete resolution of cerebral infarct: A case report of intractable intracranial hypertension

Shashi Rao, Binesh Badyal¹, Kavita Sandhu¹, Bipin S. Walia¹

Abstract

Intractable intracranial hypertension is a nerve wrecking clinical challenge which is associated with high morbidity and mortality. Barbiturate coma therapy (BCT) is one of the recommended options for such a challenge but is associated with its own set of complications. Multimodality monitoring is a new advent in neurocritical care and provides a new vision to judiciously cater to such challenges. We hereby report a case of successfully treating intractable intracranial hypertension after maximal possible surgical decompression and evidence of well-formed cerebral ischaemic zones with intracranial multimodality monitoring guided BCT. The positive outcome was to the extent of almost complete reversal of cerebral ischaemic zones and return to normal life schedule.

Key words: Barbiturate coma therapy, cerebral ischaemia, intractable intracranial hypertension, multimodality monitoring, transcranial Doppler, traumatic brain injury

INTRODUCTION

Traumatic brain injury (TBI) is the most common cause of increased intracranial pressure (ICP) and is associated with high morbidity and mortality. Intractable intracranial hypertension is defined as ICP that fails to respond to first-line medical and surgical treatment and is associated with 92% mortality.^[1] Barbiturate coma therapy (BCT) is an option in such patients with intractable intracranial hypertension.^[2]

Departments of Neuroanesthesia and Neurocritical Care, Jaypee Hospital, Noida, Uttar Pradesh, ¹Max Hospital, Saket, New Delhi, India

Address for correspondence:

Dr. Shashi Rao, Flat No. 86, Siddharth Enclave, Ashram Chowk, New Delhi - 110 014, India.
E-mail: drshaashashi@gmail.com

We report a case of refractory ICP with transcranial Doppler (TCD) evidence of ischaemic cerebral blood flow and computed tomography (CT) scan showing well-formed ischaemic zone respectively, successfully treated with BCT using relevant available multiple modalities of neurophysiological monitoring with full recovery without any neurological deficits. Much of the data in the literature regarding refractory ICP treated with BCT is without TCD and CT scan evidence of ischaemia, more so complete resolution of dense ischaemic zones has never been reported.

CASE REPORT

A 32-year-old male was referred from another hospital after 3 days with a history of road traffic accident,

This is an open access article distributed under the terms of the Creative Commons Attribution-NonCommercial-ShareAlike 3.0 License, which allows others to remix, tweak, and build upon the work non-commercially, as long as the author is credited and the new creations are licensed under the identical terms.

For reprints contact: reprints@medknow.com

How to cite this article: Rao S, Badyal B, Sandhu K, Walia BS. Transcranial Doppler-guided cerebral blood flow augmentation resulting in near complete resolution of cerebral infarct: A case report of intractable intracranial hypertension. *J Neuroanaesthesiol Crit Care* 2016;3:141-4.

Access this article online	
Quick Response Code:	Website: www.jnaccjournal.org
	DOI: 10.4103/2348-0548.182331

head injury with a bifrontal contusion, and fracture both bone left forearm with the cast *in situ*. He was treated there conservatively with anti-oedema measure using mannitol. Non-contrast CT (NCCT) head at admission showed right frontal bone fracture with bifrontal and temporal haemorrhagic contusion with oedema [Figure 1a]. Glasgow Coma Scale (GCS) was E3V4M6 with normal pupil size and reaction. He was initially treated conservatively, both for head injury with anti-oedema measures and for fractures forearm. Two days after admission, sensorium deteriorated to GCS E2V2M4 and his pupils were both normal size with sluggish reaction. Repeat NCCT scan showed increased oedema with obliteration of basal cisterns [Figure 1b]. Bifrontal decompressive craniectomy (DC) was done. He was sedated and ventilated post-operatively. Anti-oedema measures this time were instituted with 3% hypertonic saline (HTS) pulsed therapy in a dose of 7 ml/kg. NCCT head done on the first postoperative day showed significant oedema without any haematoma. The same therapy was continued but by fourth postoperative day, craniotomy site bulge became tense and pupils anisocoric with sluggish reaction. Repeat NCCT head and magnetic resonance imaging brain with venogram was performed which revealed significant brain oedema with mass effect and ischaemic/infarcted zone in the right parieto-occipital region [Figure 2a]. TCD examination was performed in which right hemicranial vessels could not be insonated and left middle cerebral artery, anterior cerebral artery showed ischaemic blood flow velocities [Figure 3a] and left PCA had reverberating blood flow pattern indicating raised ICP. The vasopressor infusion was started to increase cerebral blood flow (CBF). Extended DC with right frontal lobectomy was performed, and Codman's intraparenchymal ICP probe put *in situ*. Sedation, ventilation and intermittent bolus hyperosmolar therapy with HTS, with an ICP threshold of 20 was continued postoperative. Within 24–36 h post second surgery ICP was refractory to HTS and mean ICP was in the range of 25–30 mmHg with little, short-lived response to HTS bolus. Repeat TCD examination revealed ischaemic blood flow velocities in both right and left hemicranial vessels. After suspending previous sedatives, BCT was initiated with thiopentone at a loading dose of 10 mg/kg over 30 min followed by 3–7 mg/kg/h continuous infusion. We adjusted barbiturate infusion rate at minimal dose to maintain ICP below 20 mmHg, stable haemodynamics, high normal CBF velocities in TCD [Figure 3b] and to maintain absence of response of patient to deep painful stimuli so as to correspond roughly with burst suppression of electroencephalography (EEG). ICP swings of more than 20 mmHg were treated by a minimal dose of HTS required to reduce ICP and increase in barbiturate infusion dose to prevent such swings. Cerebral perfusion pressure (CPP) was regulated to

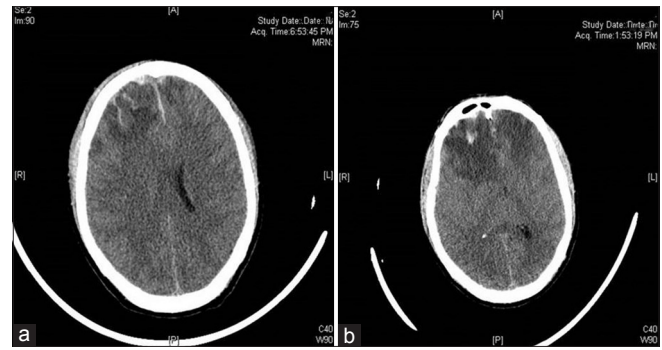


Figure 1: Preoperative computed tomography scans. (a) Admission computed tomography scan. (b) Preoperative computed tomography scan before first decompressive surgery

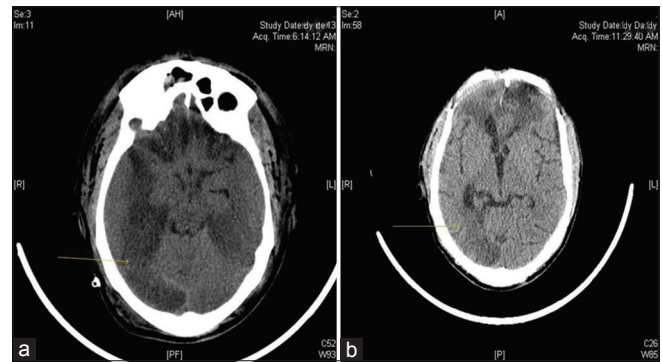


Figure 2: Postoperative Scans. (a) Computed tomography scan before second decompressive surgery and initiating barbiturate coma therapy. (b) Computed tomography scan after 2 weeks of barbiturate coma therapy and cerebral blood flow augmentation

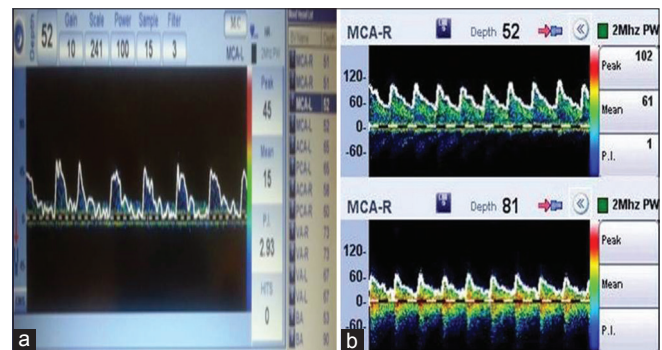


Figure 3: Transcranial Doppler images. (a) Middle cerebral artery cerebral blood flow velocity before second decompressive surgery and initiating barbiturate coma therapy. (b) Middle cerebral artery cerebral blood flow velocity during maintenance of barbiturate coma therapy

maintain high normal cerebral blood flow as evidenced by serial TCD examinations with volume replacement, inotropes/vasopressor infusions and optimal barbiturate infusion dose [Figure 4]. After ICP became stable for 48 h, that is, by the 5th day of BCT institution, we started to taper barbiturate infusion at a rate of 0.05 mg/kg/h. Total duration of barbiturate coma was 8 days. ICP probe was removed after 72 h of stopping BCT. The patient improved in sensorium and was discharged 25 days

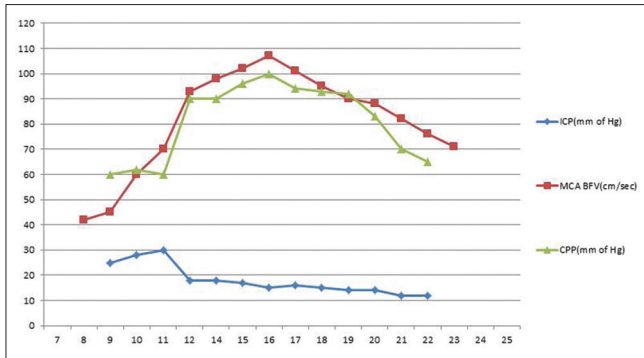


Figure 4: Intracranial haemodynamics during barbiturate coma therapy

after admission fully conscious, walking and without any neurological deficits. Follow-up scan 2 weeks after discharge showed bifrontal gliotic changes without any ischaemic/infarcted zones [Figure 2b]. Cranioplasty was done 2 months later, and the patient has resumed his normal professional and personal duties as before the accident.

DISCUSSION

Severe TBI is associated with intracranial hypertension in 53–80% of patients and is the most frequent cause of mortality and morbidity due to inadequate perfusion of the injured brain.^[3,4] Intracranial hypertension is defined as an episode of sustained ICP above 20 mmHg requiring treatment, and intractable intracranial hypertension is defined as ICP non-responsive to the first line of treatment.^[1] The first-line of therapy to control raised ICP may include sedation, moderate hypocapnia, hyperosmolar therapy, haematoma evacuation, etc. When these measures fail to control high ICP second-line therapies such as DC, BCT or moderate hypothermia are considered.^[4]

Hyperosmolar agents currently in clinical use for TBI are mannitol and HTS. Mannitol is the most commonly used hyperosmolar agent, but recently HTS also has been used in these circumstances. HTS for this purpose has been used in concentrations ranging from 3% to 23.4%.^[4] In some studies, HTS has been more effective at reducing ICP than mannitol and is an agent of choice in intractable intracranial hypertension.^[5] In our case as the ICP was refractory to mannitol clearly the choice of hyperosmolar agent was HTS and even such the response of HTS on raised ICP in our patient was suboptimal and short-lived making us coin ICP refractory to HTS.

BCT is used as second-line therapy for intracranial hypertension. Benefits of BCT are derived from vasoconstriction in normal brain areas thus shunting blood to ischaemic brain tissue and decrease in metabolic oxygen demand thus maintaining flow demand ratio

in ischaemic areas. Other proposed mechanisms also make barbiturates a good choice as an effective cerebral protective agent.^[2] BCT when instituted is guided by burst suppression ratio in EEG for optimal benefit. It is associated with numerous side effects which can be detrimental to patient outcome.^[6] If these risk factors are addressed appropriately, the optimal outcome can be expected. In our case though we did not do EEG monitoring for burst suppression but adjusted the dose to ICP readings, stable haemodynamics, high normal CBF velocities in TCD and no clinical response of the patient to supramaximal pain.

Multimodality monitoring in neurocritical care is a fast evolving concept primarily to accurately detect the physiological changes undergoing in the injured brain thus initiating early timely intervention to circumvent morbidity and mortality.^[7] Few of such monitoring armamentarium includes ICP, TCD, cerebral imaging microdialysis, EEG, jugular oximeter, brain tissue oxygen monitor, etc.^[7] Judicious use of these monitors with Integration of this information allows for more precise diagnosis and optimization of the management of these patients.^[7] TCD is valuable equipment providing a vast range of information involving CBF non-invasively. TCD CBF velocities in major cerebral vessels below 30 cm/s are defined as ischaemic and are associated with poor outcomes.^[8]

In our case, we used cerebral imaging to detect the cause, ICP monitor to regulate ICP and CPP, TCD to detect ischaemic CBF and regulate CBF to high normal during BCT. The combination of these helped us in being judicious in our approach including doing DC, diagnosing refractory intracranial hypertension, optimal use of hyperosmolar therapy, early initiation/maintenance of BCT, regulation of CBF ultimately leading to resolution of ischaemic infarct and thus good outcome. We suggest that, judicious use of multimodality monitoring (permutable combination of Cerebral Imaging, Intracranial Pressure monitor, CBF guide) can help neurointensivists in diagnosing life-threatening intracranial dynamics early and implementing corrective therapeutic procedures alongside monitoring their efficacy to surmount these challenges.

Financial support and sponsorship

Nil.

Conflicts of interest

There are no conflicts of interest.

REFERENCES

1. Miller JD, Butterworth JF, Gudeman SK, Faulkner JE, Choi SC, Selhorst JB, *et al.* Further experience in the management of severe head injury. *J Neurosurg* 1981;54:289-99.

2. Kim YI, Park SW, Nam TK, Park YS, Min BK, Hwang SN. The effect of barbiturate coma therapy for the patients with severe intracranial hypertension: A 10-year experience. *J Korean Neurosurg Soc* 2008;44:141-5.
3. Miller JD. Head injury. *J Neurol Neurosurg Psychiatry* 1993;56:440-7.
4. Brain Trauma Foundation; American Association of Neurological Surgeons; Congress of Neurological Surgeons. Guidelines for the management of severe traumatic brain injury. *J Neurotrauma* 2007;24 Suppl 1:S1-106.
5. Vialet R, Albanèse J, Thomachot L, Antonini F, Bourguoin A, Alliez B, *et al.* Isovolum hypertonic solutes (sodium chloride or mannitol) in the treatment of refractory posttraumatic intracranial hypertension: 2 mL/kg 7.5% saline is more effective than 2 mL/kg 20% mannitol. *Crit Care Med* 2003;31:1683-7.
6. Schalén W, Messeter K, Nordström CH. Complications and side effects during thiopentone therapy in patients with severe head injuries. *Acta Anaesthesiol Scand* 1992;36:369-77.
7. Wartenberg KE, Schmidt JM, Mayer SA. Multimodality monitoring in neurocritical care. *Crit Care Clin* 2007;23:507-38.
8. Sarkar S, Ghosh S, Ghosh SK, Collier A. Role of transcranial Doppler ultrasonography in stroke. *Postgrad Med J* 2007;83:683-9.