

Transorbital sonographic evaluation of normal optic nerve sheath diameter in healthy Nepalese adults

Gentle Sunder Shrestha

Abstract

Background: Sonographic evaluation of optic nerve sheath diameter (ONSD) is increasingly being used as a non-invasive technique for detecting raised intracranial pressure. **Aims:** The aim of this study is to find out the normal ONSD in healthy Nepalese adults. **Settings and Design:** It is a cross-sectional observational study. **Subjects and Methods:** ONSD was measured 3 mm behind the globe using 6–13 MHz linear probe. Subjects were examined in the supine position with their eyes closed and in neutral position. Transducer was placed horizontally and in each eye, an average of three readings were documented. **Statistical Analysis Used:** Data were represented as mean and standard deviation. Paired *t*-test was used to compare ONSD between the right and left eye. Independent *t*-test was used to compare ONSD between males and females. Pearson correlation coefficient was used to assess the correlation between age and ONSD. **Results:** Eighty-eight healthy subjects above 18 years of age were enrolled in the study. The median ONSD was 4.1 mm with 95% of subjects in the range of 3.1–4.6 mm. There was no significant difference in ONSD measurement between males and females ($P = 0.09$) and between the right and left eye ($P = 0.72$). There was no relationship between ONSD and age ($R^2 = 0.06$, $P = 0.55$). **Conclusions:** The range for normal ONSD in healthy adult Nepalese subjects is 3.1–4.6 mm with no significant relationship with gender, age and side of the body.

Key words: Nepalese adult, optic nerve sheath diameter, ultrasonography

INTRODUCTION

Many neurological emergencies are complicated by raised intracranial pressure (ICP). If not recognised early, it is associated with poor outcome and secondary brain damage.^[1] Multimodal neuromonitoring has contributed significantly to improved treatments for critically ill neurologic patients.^[2] Invasive method is the gold standard for ICP measurement, but it carries the inherent

risk of intracerebral haemorrhage and infection.^[3] Availability of invasive ICP monitoring may be limited in developing countries due to constrained resources, lack of trained man power and equipped Intensive Care Units.^[4,5] Non-invasive ICP monitoring may be helpful in the management of patients when invasive monitoring is not immediately available and to choose patients who need invasive monitoring.^[6]

Among the various non-invasive methods, ultrasonographic measurement of optic nerve sheath diameter (ONSD) has been extensively studied. ICP has a linear relationship with ONSD.^[7] When ICP increases, changes in ONSD occur before changes in nerve are visible on fundoscopic examination.^[8] It is increasingly

Department of Anaesthesiology, Tribhuvan University Teaching Hospital, Maharajgunj, Kathmandu, Nepal

Address for correspondence:

Dr. Gentle Sunder Shrestha, Department of Anaesthesiology, Tribhuvan University Teaching Hospital, Maharajgunj, Kathmandu, Nepal.
E-mail: gentlesunder@hotmail.com

Access this article online

Quick Response Code:



Website:

www.jnaccjournal.org

DOI:

10.4103/2348-0548.182343

This is an open access article distributed under the terms of the Creative Commons Attribution-NonCommercial-ShareAlike 3.0 License, which allows others to remix, tweak, and build upon the work non-commercially, as long as the author is credited and the new creations are licensed under the identical terms.

For reprints contact: reprints@medknow.com

How to cite this article: Shrestha GS. Transorbital sonographic evaluation of normal optic nerve sheath diameter in healthy Nepalese adults. *J Neuroanaesthesiol Crit Care* 2016;3:115-8.

being used in Emergency Departments and Intensive Care Units.^[9,10] ONSD has a good level of diagnostic accuracy to detect intracranial hypertension.^[11] The sonographic measurement of ONSD is readily learned, reproducible technique with low intra- and inter-observer variation.^[12] By limiting the examination time and by keeping the ultrasound output power as low as reasonably achievable (ALARA principle), the technique can be performed safely.^[1,13]

Optimal ONSD cut-off value for raised ICP is controversial. Based on the first validation studies, most studies have used 5 mm as upper limit of normal for adults.^[14,15] However, the values are considerably different between 5 and 5.9 mm in recent studies.^[1] Knowledge of normal range of ONSD in healthy population is essential to interpret this measurement as a marker of ICP in clinical practice and research.^[9,16] ONSD can vary with ethnic origin. Studies in Asian countries have proposed various normal ranges in adults (3.7–4.7 mm in Hong Kong,^[17] 2.9–5.3 mm in Korea^[18] and 4.25–4.75 mm in Bangladesh).^[16] To the best of my knowledge, this is the first study to find the normal ONSD in Nepalese adults.

SUBJECTS AND METHODS

This cross-sectional observational study was conducted in a private setting hospital of Nepal after obtaining approval from hospital. Healthy hospital staffs and relatives of the patients above 18 years were enrolled in the study after obtaining written informed consent. Individuals with known ocular pathology were excluded from the study.

A single investigator measured ONSD using 6–13 MHz linear probe (MicroMaxx®; SonoSite, USA). The investigator had an experience of performing more than 200 ONSD measurements. Subjects were examined in the supine position with their eyes closed and in neutral position. Ultrasound gel was applied to the outside of each upper eyelid. Transducer was placed horizontally. Video of each reading was recorded for later analysis by another single blinded investigator. Electronic caliper was used to mark the point 3 mm behind the globe. ONSD was measured at that depth at right angle to the optic nerve [Figure 1]. The widest diameter visible was recorded. An average of three readings were documented in each eye.

RESULTS

Eighty-eight healthy subjects of both sexes and of Nepalese origin were enrolled in the study. The sample size was calculated from the pre-test of initial 20 cases, using the formula $z^2\Sigma^2/d^2$. The calculated Σ (standard deviation) from the pre-test was 0.24. Values of 1.96 for

z (reliability coefficient at 95% confidence interval) and 0.05 for d (maximum tolerable error) were applied.

Age of the subjects ranged from 19 to 83 years. Of them, 55 were males and 33 were females. The median ONSD was 4.1 mm with 95% of subjects in the range of 3.1–4.6 mm [Figure 2]. There was no significant difference in ONSD measurement between males (3.90 ± 0.54 mm) and females (4.09 ± 0.44 mm) ($P = 0.09$) as tested by independent t -test. ONSD of the right (3.97 ± 0.54 mm) and left eye (3.98 ± 0.50 mm) also did not differ significantly ($P = 0.72$). There was no relationship between ONSD and age ($R^2 = 0.06$, $P = 0.55$) [Figure 3].

DISCUSSION

This study indicates that 4.6 mm can be considered as the upper limit of normal for Nepalese healthy adults, which is similar to the cut-off of 4.75 mm in Bangladeshi people. However, the range was narrower in their study (4.25–4.75 mm) as compared to this study (3.1–4.6 mm), probably due to difference in the frequency of probe used (15 MHz probe in their study as compared to 6–13 MHz probe in our study).^[16] The range in this study is in similarity with the findings of Hong Kong population (3.7–4.7 mm),^[17] but varies from the findings in other populations – 2.5 to 4.1 mm in UK adults^[12] and 2.2–4.9 mm in Greek adults.^[19] Differences in normal ranges in various studies can be due to difference in ethnicities and methodology.^[16] Consistent with other studies, ONSD was independent of age, gender and side of the body.^[16,17]

There are few limitations in this study. The study was conducted in a single centre and by a single investigator. Interobserver variability could not be studied. Paediatric population was excluded in the

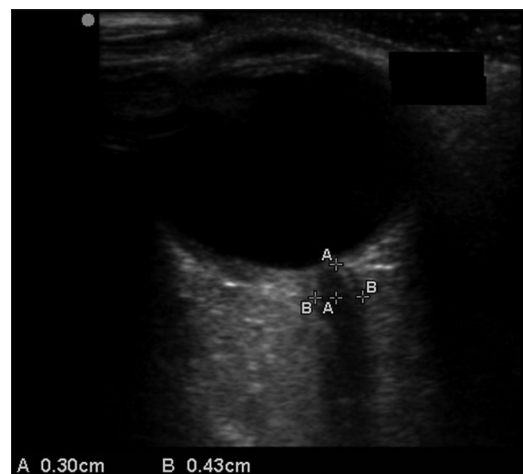

Figure 1: Optic nerve sheath diameter measured 3 mm behind the globe

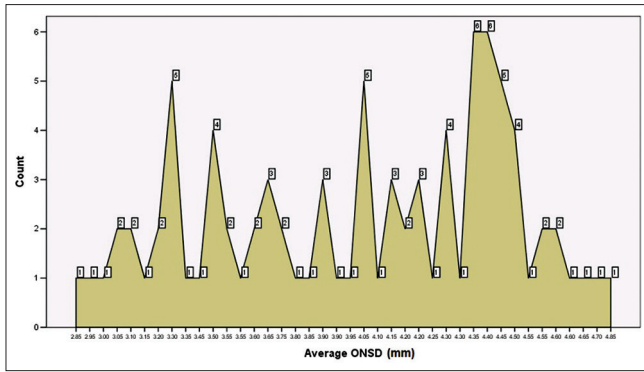


Figure 2: Distribution of optic nerve sheath diameter. The numbers in boxes represent the number of healthy volunteers with the corresponding optic nerve sheath diameter mentioned in X-axis

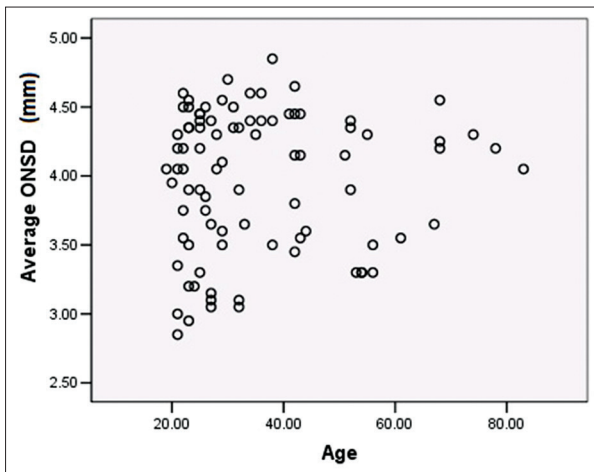


Figure 3: Relationship of optic nerve sheath diameter with age ($R^2 = 0.06$, $P = 0.55$)

study. Direct measurement of ICP was not performed. Hence, it is not known how well the ONSD above derived normal range predicts raised ICP. Systemic diseases such as diabetes and hypertension may affect optic disk and ONSD measurement. Fundoscopy to rule out the ocular effects of these disorders was not performed.

CONCLUSION

To conclude, ONSD in healthy adult Nepalese subjects ranges between 3.1 and 4.6 mm. There is no significant relationship of ONSD with gender, age and side of the body.

Acknowledgement

I would like to thank the hospital staffs, family members of patients and Alka Hospital authority for participating in the study. I would specially acknowledge the support and help from the staffs of Alka hospital ICU and Operation Theater, without

which, the study would not have been possible. I am thankful to Dr. Sanjeev Bhoi for encouragement and for sharing the concept of study.

Financial support and sponsorship

Nil.

Conflicts of interest

There are no conflicts of interest.

REFERENCES

- Moretti R, Pizzi B. Ultrasonography of the optic nerve in neurocritically ill patients. *Acta Anaesthesiol Scand* 2011;55:644-52.
- Suarez JI. Outcome in neurocritical care: Advances in monitoring and treatment and effect of a specialized neurocritical care team. *Crit Care Med* 2006;34 9 Suppl: S232-8.
- Zeng T, Gao L. Management of patients with severe traumatic brain injury guided by intraventricular intracranial pressure monitoring: A report of 136 cases. *Chin J Traumatol* 2010;13:146-51.
- Mateen FJ. Neurocritical care in developing countries. *Neurocrit Care* 2011;15:593-8.
- Shrestha RR, Vaidya PR, Bajracharya GR. A survey of adult intensive care units in Kathmandu valley. *PMJN* 2011;11:1-7.
- Rosenberg JB, Shiloh AL, Savel RH, Eisen LA. Non-invasive methods of estimating intracranial pressure. *Neurocrit Care* 2011;15:599-608.
- Liu D, Kahn M. Measurement and relationship of subarachnoid pressure of the optic nerve to intracranial pressures in fresh cadavers. *Am J Ophthalmol* 1993;116:548-56.
- Gangemi M, Cennamo G, Maiuri F, D'Andrea F. Echographic measurement of the optic nerve in patients with intracranial hypertension. *Neurochirurgia (Stuttg)* 1987;30:53-5.
- Blaivas M, Theodoro D, Sierzenski PR. Elevated intracranial pressure detected by bedside emergency ultrasonography of the optic nerve sheath. *Acad Emerg Med* 2003;10:376-81.
- Geeraerts T, Launey Y, Martin L, Pottecher J, Vigué B, Duranteau J, et al. Ultrasonography of the optic nerve sheath may be useful for detecting raised intracranial pressure after severe brain injury. *Intensive Care Med* 2007;33:1704-11.
- Dubourg J, Javouhey E, Geeraerts T, Messerer M, Kassai B. Ultrasonography of optic nerve sheath diameter for detection of raised intracranial pressure: A systematic review and meta-analysis. *Intensive Care Med* 2011;37:1059-68.
- Ballantyne SA, O'Neill G, Hamilton R, Hollman AS. Observer variation in the sonographic measurement of optic nerve sheath diameter in normal adults. *Eur J Ultrasound* 2002;15:145-9.
- Barnett SB, Ter Haar GR, Ziskin MC, Rott HD, Duck FA, Maeda K. International recommendations and guidelines for the safe use of diagnostic ultrasound in medicine. *Ultrasound Med Biol* 2000;26:355-66.
- Helmke K, Hansen HC. Fundamentals of transorbital sonographic evaluation of optic nerve sheath expansion under intracranial hypertension. I. Experimental study. *Pediatr Radiol* 1996;26:701-5.
- Helmke K, Hansen HC. Fundamentals of transorbital sonographic evaluation of optic nerve sheath expansion under intracranial hypertension II. Patient study. *Pediatr Radiol* 1996;26:706-10.
- Maude RR, Hossain MA, Hassan MU, Osbourne S, Sayeed KL,

- Karim MR, *et al.* Transorbital sonographic evaluation of normal optic nerve sheath diameter in healthy volunteers in Bangladesh. PLoS One 2013;8:e81013.
17. Chan PY, Mok KL. Transorbital sonographic evaluation of optic nerve sheath diameter in normal Hong Kong Chinese adults. Hong Kong J Emerg Med 2008;15:197-204.
18. Lee JS, Lim DW, Lee SH, Oum BS, Kim HJ, Lee HJ. Normative measurements of Korean orbital structures revealed by computerized tomography. Acta Ophthalmol Scand 2001;79:197-200.
19. Soldatos T, Karakitsos D, Chatzimichail K, Papathanasiou M, Gouliamos A, Karabinis A. Optic nerve sonography in the diagnostic evaluation of adult brain injury. Crit Care 2008;12:R67.