

Airtraq® aided tracheal intubation in a patient of Down's syndrome with traumatic atlantoaxial dislocation

Obaid A. Siddiqi, Shahna Ali, Manazir Athar, Asad Mahmood¹

Abstract

Down's syndrome is a genetic disorder that is associated with multiple congenital anomalies having great impact on anaesthetic management. Apart from this, it also predisposes the patient to the atlantoaxial dislocation making the management of airway a difficult task. In our case, the child already had traumatic atlantoaxial dislocation that further makes the successful airway management without progression of any neurological injury a challenge. Hereby, we report the successful management of an 8-year-old child with Down's syndrome and traumatic atlantoaxial dislocation using Airtraq® optical laryngoscope.

Key words: Airtraq, atlantoaxial dislocation, Down syndrome, intubation

INTRODUCTION

Down's syndrome or trisomy 21 is a genetic birth disorder with an incidence of about 1:800 live births.^[1] The disorder affects almost all organ systems. About 20% of patients with Down's syndrome have ligamentous laxity of atlantoaxial joint. These patients, therefore, are vulnerable to dislocation of atlantoaxial joint during neck movements which may result in cervical spinal cord injury.^[2] Achieving an optimal sniffing position during conventional laryngoscopy is not prudent. The Airtraq® optical laryngoscope has been successfully

Departments of Anaesthesiology and Critical Care and ¹Neurosurgery, Jawaharlal Nehru Medical College and Hospital, Aligarh Muslim University, Aligarh, Uttar Pradesh, India

Address for correspondence:

Dr. Obaid Ahmad Siddiqi, Department of Anaesthesiology and Critical Care, Jawaharlal Nehru Medical College, Aligarh Muslim University, Aligarh - 202 002, Uttar Pradesh, India.
E-mail: obaidahmad2008@gmail.com

used in patients with restricted neck movements and does not require an optimal sniffing position. This case report describes the use of Airtraq® optical laryngoscope in managing airway in a patient of Down's syndrome with atlantoaxial dislocation.

CASE REPORT

An 8-year-old male child, American Society of Anesthesiologists Grade II, weighing 15 kg, and a known case of Down's syndrome presented with quadriparesis subsequent to fall from height. He was diagnosed as a case of traumatic atlantoaxial dislocation. The pre-operative assessment was normal except restricted neck movements, macroglossia and mallampati Class IV [Figure 1]. His radiograph and magnetic resonance imaging of the cervical spine showed atlantoaxial dislocation with fracture of the odontoid process [Figures 2 and 3]. The patient was planned for laminectomy and posterior fixation under general anaesthesia. All preparations for difficult airway

This is an open access article distributed under the terms of the Creative Commons Attribution-NonCommercial-ShareAlike 3.0 License, which allows others to remix, tweak, and build upon the work non-commercially, as long as the author is credited and the new creations are licensed under the identical terms.

For reprints contact: reprints@medknow.com

How to cite this article: Siddiqi OA, Ali S, Athar M, Mahmood A. Airtraq® aided tracheal intubation in a patient of Down's syndrome with traumatic atlantoaxial dislocation. J Neuroanaesthesiol Crit Care 2016;3:259-61.

Access this article online	
Quick Response Code:	Website: www.jnaccjournal.org
	DOI: 10.4103/2348-0548.190080

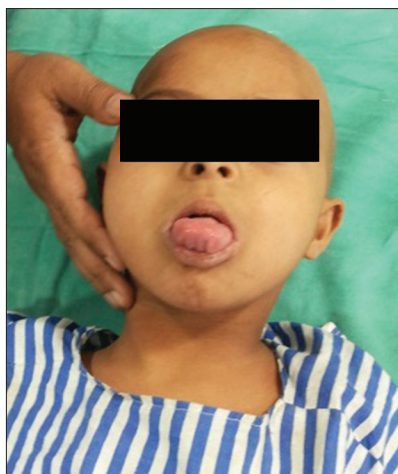

Figure 1: The restricted head and neck movement with macroglossia (source: Original)

were made in anticipation. Patient was premedicated with intravenous (IV) midazolam 0.05 mg/kg, glycopyrrolate 0.01 mg/kg and fentanyl 1 µg/kg. After preoxygenation for 3 min, anaesthesia was induced with propofol 2 mg/kg. Following confirmation of adequate bag-mask ventilation, neuromuscular relaxation was achieved with succinylcholine 1.5 mg/kg intravenously. The table was adjusted to the head down position with flexion of both the knees. The Airtraq[®] was introduced in the midline, over the base of the tongue and the tip positioned in the vallecula. The patient was successfully intubated using an Airtraq[®] optical laryngoscope (size-2) in a neutral position. A continuous flow of oxygen was maintained throughout the procedure via a nasal cannula to prevent hypoxia and defog the optical device. Anaesthesia was maintained with a mixture of nitrous oxide and oxygen in a ratio of 60:40, sevoflurane 1% and 0.1 mg/kg/h vecuronium infusion. The intra-operative course was uneventful, and the patient was extubated after reversal of neuromuscular blockade.

DISCUSSION

Patients with Down's syndrome are vulnerable to develop subluxation of C1–C2 joint. This may be as a result of ligamentous laxity. In addition to this, hypoplasia, malformation and absence of the odontoid process are other causes that predispose these patients to atlantoaxial subluxation.^[1] The airway management in such patients presents a unique challenge to the anaesthesiologist. The anaesthesiologist must be aware of the neurological manifestations of atlantoaxial dislocation. Movements of the head and neck must be restricted to avoid the aggravation of the spinal injury. Achieving an optimal sniffing position which requires an extension at atlanto-occipital joint and flexion at the lower cervical joint may not be possible. Conventional

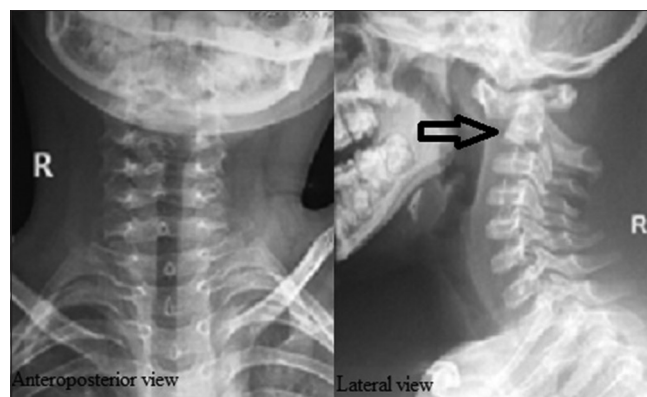


Figure 2: The fractured odontoid process and atlantoaxial dislocation (black arrow) in the cervical spine radiograph-anteroposterior and lateral view (source: Original)

laryngoscopy, therefore, may not be the most prudent approach in these patients. Awake fibre-optic intubation is considered to be the gold standard and the safest option in patients of the difficult airway. However, awake intubation is technically more difficult in children and a relatively painful procedure.^[3] Moreover, some patients remain apprehensive about the procedure and refuse to remain awake.

Other options available to secure the airway in such patients may be laryngeal mask airway (LMA), intubating LMA (ILMA), video laryngoscopes and surgical airway. LMA including ILMA has been widely used in cases of difficult intubation because its ease of insertion in a neutral position. We have avoided it due prone positioning and risk of aspiration.^[4,5] Recently, video laryngoscopes have been used to secure the airway in patients of cervical spine injury. However, there is relative scarcity of literature with the use of these devices in paediatric patients presenting with atlantoaxial dislocation.^[6]

Our patient had an adequate mouth opening, but the difficulty in conventional laryngoscopy was because of inability to achieve optimal sniffing position and align the three axes. Awake intubation was not planned as the child was not cooperative. Intubation with Airtraq[®] laryngoscope was therefore planned because of a number of advantages, it offers in these situations. Airtraq[®] (Prodol Ltd., Vizcaya, Spain) is an optical laryngoscope with great potential of managing the difficult airway. The extreme curvature of the blade and the optical components help to visualise the glottis without the need for aligning the three airway axes, i.e., oral, pharyngeal and laryngeal. It also does not obstruct the endoscopic view of the vocal cord during laryngoscopy because of its inbuilt conduit for the endotracheal tube. Many studies have reported the effectiveness and utility of the Airtraq[®] for tracheal




Figure 3: Atlantoaxial dislocation in the magnetic resonance imaging scan of the cervical spine of patient (source: Original)

intubation in patients with cervical spine immobilisation and in morbidly obese patients.^[7,8]

CONCLUSION

Airtraq® optical laryngoscope can be used for elective intubation in patients with atlantoaxial dislocation which require restriction of neck movements during laryngoscopy.

Declaration of patient consent

The authors certify that they have obtained all appropriate patient consent forms. In the form the patient(s) has/

have given his/her/their consent for his/her/their images and other clinical information to be reported in the journal. The patients understand that their names and initials will not be published and due efforts will be made to conceal their identity, but anonymity cannot be guaranteed.

Financial support and sponsorship

Nil.

Conflicts of interest

There are no conflicts of interest.

REFERENCES

1. Meitzner MC, Skurnowicz JA. Anesthetic considerations for patients with Down syndrome. *AANA J* 2005;73:103-7.
2. Moore RA, McNicholas KW, Warran SP. Atlantoaxial subluxation with symptomatic spinal cord compression in a child with Down's syndrome. *Anesth Analg* 1987;66:89-90.
3. Kandasamy R, Sivalingam P. Use of sevoflurane in difficult airways. *Acta Anaesthesiol Scand* 2000;44:627-9.
4. Brimacombe J, Berry A. Laryngeal mask airway insertion. A comparison of the standard versus neutral position in normal patients with a view to its use in cervical spine instability. *Anaesthesia* 1993;48:670-1.
5. Nakazawa K, Tanaka N, Ishikawa S, Ohmi S, Ueki M, Saitoh Y, *et al.* Using the intubating laryngeal mask airway (LMA-Fastrach) for blind endotracheal intubation in patients undergoing cervical spine operation. *Anesth Analg* 1999;89:1319-21.
6. Suppan L, Tramèr MR, Niquille M, Groscurin O, Marti C. Alternative intubation techniques vs Macintosh laryngoscopy in patients with cervical spine immobilization: Systematic review and meta-analysis of randomized controlled trials. *Br J Anaesth* 2016;116:27-36.
7. Maharaj CH, Buckley E, Harte BH, Laffey JG. Endotracheal intubation in patients with cervical spine immobilization: A comparison of Macintosh and Airtraq laryngoscopes. *Anesthesiology* 2007;107:53-9.
8. Ndoko SK, Amathieu R, Tual L, Polliand C, Kamoun W, El Housseini L, *et al.* Tracheal intubation of morbidly obese patients: A randomized trial comparing performance of Macintosh and Airtraq laryngoscopes. *Br J Anaesth* 2008;100:263-8.