

Access this article online
Quick Response Code:

Website: www.jlponline.org
DOI: 10.4103/JLP.JLP_61_19

A case of myelodysplastic syndrome with t(10;18)(q26;q21)

Yusuke Ohba¹, Minami Yamada-Fujiwara^{2,3}, Tadanori Minagawa⁴, Suguru Watanabe⁴, Yoko Okitsu^{5,6}, Yoshihiko Izumi¹, Junichi Kameoka², Shinichiro Takahashi^{1,6}

Abstract:

An 82-year-old male was admitted. Pancytopenia, a slightly low white blood cell count (3400/ μ L), and low levels of red blood cells ($2.65 \times 10^6/\mu$ L), hemoglobin (10.4 g/dL), and platelets (118,000/ μ L) were observed. Bone marrow aspiration was performed, revealing hypocellular bone marrow and normal blast levels (0.6%) with no dysplasia. G-banding chromosome analysis revealed the karyotype 45,X,-Y[3]/45, idem, t(10;18)(q26;q21)[13]/46,XY[4]. The patient was diagnosed with myelodysplastic syndrome, unclassified (MDS-U). This is the first case report demonstrating a patient with the chromosomal translocation, t(14;18)(q32;q21), which is extremely rare. This chromosomal aberration was critical for the diagnosis of MDS in this patient.

Keywords:

Chromosome banding, myelodysplastic syndromes, t(10;18)(q26;q21)

Introduction

In the WHO 2008 criteria revised in 2016, for a patient with clinical and other laboratory features, a presumptive diagnosis of myelodysplastic syndrome (MDS) can be made if a specific clonal chromosomal abnormality is present. The balanced abnormalities included in the 2008 criteria were t(11;16)(q23;p13.3), t(3;21)(q26.2;q22.1), t(1;3)(p36.3;q21.1), t(2;11)(p21;q23), inv (3)(q21q26.2), and t(6;9)(p23;q34),^[1] while those further included in the 2016 criteria were t(5;12)(q32;p13.2), t(5;7)(q32;q11.2), t(5;17)(q32;p13.2), t(5;10)(q32;p21.2), and t(3;5)(q25.3;q35.1).^[2] Recently, we encountered a patient with pancytopenia and what appears to be an extremely rare chromosomal abnormality, t(10;18)(q26;q21). As there was no obvious dysplasia or increase in blasts, we considered this reciprocal translocation as a "balanced abnormality" and diagnosed the patient with MDS, unclassified (MDS-U) according to the WHO classification system.

This is an open access journal, and articles are distributed under the terms of the Creative Commons Attribution-NonCommercial-ShareAlike 4.0 License, which allows others to remix, tweak, and build upon the work non-commercially, as long as appropriate credit is given and the new creations are licensed under the identical terms.

For reprints contact: reprints@medknow.com

The following case report further describes this chromosomal abnormality.

Case Report

An 82-year-old male suffering from severe chest pain was taken by ambulance to a clinic. The day after, he received coronary angiography, and stenosis was observed in the right coronary artery. His chest pain persisted after angiography. Unstable angina was suspected, and the patient was transferred to the Cardiovascular Medicine Department at the Tohoku Medical and Pharmaceutical University Hospital to receive a percutaneous coronary intervention.

Upon admission to our hospital, the patient's white blood cell count was slightly low (3,400/ μ L), and low red blood cell ($2.65 \times 10^6/\mu$ L), hemoglobin (9.3 g/dL), and platelet (118,000/ μ L) levels were also observed [Table 1]. Echocardiography revealed severe aortic valve stenosis. Aortic valvuloplasty and coronary artery bypass graft surgery were performed.

How to cite this article: Ohba Y, Yamada-Fujiwara M, Minagawa T, Watanabe S, Okitsu Y, Izumi Y, *et al.* A case of myelodysplastic syndrome with t(10;18)(q26;q21). J Lab Physicians 2019;11:382-4.

Departments of ¹Clinical Laboratory, ²Hematology and Rheumatology, ⁴Cardiovascular Surgery and ⁵Blood Transfusion, Tohoku Medical and Pharmaceutical University Hospital, ⁶Division of Laboratory Medicine, Faculty of Medicine, Tohoku Medical and Pharmaceutical University, ³Division of Blood Transfusion and Cell Therapy, Tohoku University Hospital, Sendai, Japan

Address for correspondence:

Prof. Shinichiro Takahashi, Division of Laboratory Medicine, Faculty of Medicine, Tohoku Medical and Pharmaceutical University, 1-15-1, Fukumuro, Miyaginoku, Sendai 983-8536, Japan. E-mail: shintakahashi@tohoku-mpu.ac.jp

Submission: 08-04-2019

Accepted: 22-11-2019

Table 1: Laboratory findings at first visit and the result of bone marrow examination

Complete blood count	
WBC	3.4×10 ³ /μL
Seg	58.7%
Eosino	3.6%
Baso	0.6%
Lymph	25.8%
Mono	11.3%
RBC	2.65×10 ⁶ /μL
Hb	9.3g/dL
Ht	28%
MCV	105.4fL
PLT	18×10 ³ /μL
PT	14.4 sec
APTT	28.5 sec
D-dimer	2.91 μg/mL

Biochemistry test	
T-Bil	0.7 mg/dL
AST	33 U/L
ALT	28 U/L
LD	167 U/L
ALP	209 U/L
g-GTP	63 U/L
CK	41 U/L
CK-MB	<10 U/L
Troponin T	0.017 ng/mL
BUN	15mg/dL
CRE	1.2mg/dL
UA	5.3mg/dL
TP	6.2mg/dL
Alb	3.7mg/dL
T-CHO	154mg/dL
HDL-C	56mg/dL
LDL-C	85mg/dL
Na	141mEq/L
K	4.1mEq/L
Cl	111mEq/L
Ca	8.7mg/dL
IP	3.1mg/dL
Fe	92μg/dL
UIBC	131μg/dL
TIBC	223μg/dL
Ferritin	155ng/mL
Zn	62μg/dL
CRP	0.05mg/dL
BNP	58.6pg/mL
FBS	121mg/dL
HbA1c	5.5%

Bone marrow examination	
Cellularity	hypocellular marrow
M/E	2.6
Blast	0.6%
Promyelo	2.2%
Myelo	9.4%
Meta	11.4%
Stab	14.4%

Table 1: Contd...

Bone marrow examination	
Cellularity	hypocellular marrow
Seg	16.8%
Eosino	5.4%
Baso	0.2%
Mono	3.6%
Lymph	11.8%
Plasma	0.4%
Macrophage	0.8%
Proeryth	0%
Basoeryth	0.2%
Polyeryth	21.4%
Orthoeryth	0.2%

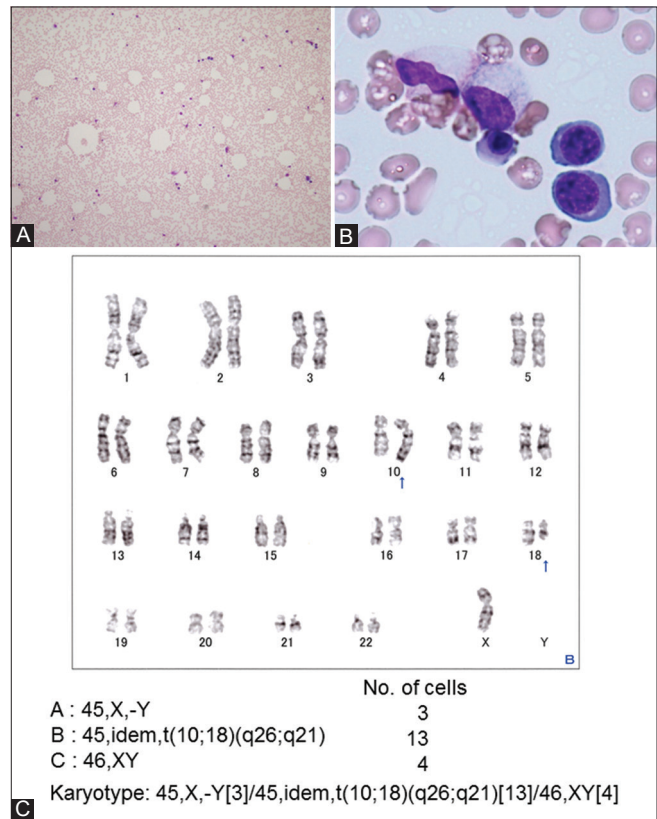


Figure 1: Morphological images of bone marrow aspirations at the initial diagnosis using Wright-Giemsa staining and a result of G-banding chromosomal analysis. (A) Morphological image with × 100 magnification. Hypocellular marrow with lipid droplets was observed. (B) Image at × 1000 magnification. No apparent dysplasia was observed. (C) A G-banded karyotype showing 45, X,-Y[3]/45, idem, t(10;18)(q26;q21)[13]/46, XY[4]. Arrows indicate translocated regions

During the surgery, bone marrow aspiration from the sternum was performed. The aspiration was examined morphologically and cytogenetically. The patient’s bone marrow was observed to be hypocellular with no obvious dysplasia [Figure 1a and b]. The blast percentage was within the normal range at 0.6% [Figure 1A and B, and Table 1]. G-banding analysis of the bone marrow sample revealed that the patient had a chromosomal translocation: among the 20 cells analyzed,

Contd.....

three cells were karyotype A (45,X,-Y), 13 cells were karyotype B (45, idem, t(10;18)(q26;q21), and four cells were karyotype C (46, XY) [Figure 1C]. The patient was diagnosed with MDS-U. The patient remains carefully observed in our hospital as an outpatient thereafter.

Discussion

We recently reported the usefulness of careful histogram analysis of automatic blood cell analyzer results for acute leukemia, which assists with rapid morphological findings for blasts and abnormal cells.^[3] However, not only morphologic but also cytogenetic studies are necessary to diagnose hematologic malignancies; this is common knowledge for clinical hematologists. A unique feature of the present case may be that the bone marrow aspiration and chromosome analysis were ordered and performed by cardiovascular surgeons rather than hematologists during the aortic valvuloplasty and coronary artery bypass graft surgery.

We speculate that the most likely gene playing a role in the pathogenesis of this patient's disease is BCL2. The BCL2 gene lies within 18q21.3 and is frequently translocated to the immunoglobulin heavy chain (IgH) gene enhancer region as a result of t(14;18)(q32;q21.3), which results in the over-expression of the BCL2 gene.^[4] BCL2 overexpression is involved in the pathogenesis of follicular lymphoma by preventing apoptosis of the germinal center B-cells.^[4] The t(14;18)(q32;q21.3) translocation can be detected by fluorescence *in situ* hybridization in 85% of all cases and is considered a molecular hallmark of this disease.

Not only follicular lymphoma but also several other hematopoietic malignancies are reported to be related to the aberrant expression of the BCL2 protein.^[5] In particular, in MDS patients, BCL2 expression is high, while in aplastic anemia patients, BCL2 expression is low.^[5] Previously, it was reported that progression to high-risk MDS correlates with elevated expression of BCL2 protein.^[6] Collectively, BCL2 expression and regulation may affect the pathophysiology of MDS.

Chromosome 10 and 18 translocations are very rare. To the best of our knowledge, only four studies have reported such translocations.^[7-10] In particular, the breakpoint we observed, t(10;18)(q26;q21), was unique

because it is not among these reported translocations. Although we could not identify what was fused with the gene residing in 18q21.3 (possibly the BCL2 gene), since this patient is too stable to perform further analysis, these results indicate that characterizing the gene (s) affected by this rare translocation may lead to further understanding of the biology of MDS.

Financial support and sponsorship

Nil.

Conflicts of interest

There are no conflicts of interest.

References

1. Vardiman JW, Thiele J, Arber DA, Brunning RD, Borowitz MJ, Porwit A, et al. The 2008 revision of the World Health Organization (WHO) classification of myeloid neoplasms and acute leukemia: Rationale and important changes. *Blood* 2009;114:937-51.
2. Arber DA, Orazi A, Hasserjian R, Thiele J, Borowitz MJ, Le Beau MM, et al. The 2016 revision to the World Health Organization classification of myeloid neoplasms and acute leukemia. *Blood* 2016;127:2391-405.
3. Saito R, Yokoyama H, Meguro K, Ohba Y, Izumi Y, Takahashi S. Rapid diagnosis of mixed phenotype acute leukemia after identifying a blood histogram abnormality. *Pract Lab Med* 2018;12:e00101.
4. Weiss LM, Warnke RA, Sklar J, Cleary ML. Molecular analysis of the t(14;18) chromosomal translocation in malignant lymphomas. *N Engl J Med* 1987;317:1185-9.
5. Mehta SV, Shukla SN, Vora HH. Overexpression of Bcl2 protein predicts chemoresistance in acute myeloid leukemia: Its correlation with FLT3. *Neoplasia* 2013;60:666-75.
6. Invernizzi R, Pecci A, Bellotti L, Ascari E. Expression of p53, Bcl-2 and ras oncoproteins and apoptosis levels in acute leukaemias and myelodysplastic syndromes. *Leuk Lymphoma* 2001;42:481-9.
7. Tuck-Muller CM, Dyken PR, Li S, Chen H, Labbé E, Wertelecki W. Translocation 10;18 in a patient with juvenile neuronal ceroid-lipofuscinosis (Batten disease). *Am J Med Genet* 1995;57:168-71.
8. Gomi K, Hamanoue S, Tanaka M, Matsumoto M, Kitagawa N, Niwa T, et al. Anaplastic sarcoma of the kidney with chromosomal abnormality: First report on cytogenetic findings. *Hum Pathol* 2010;41:1495-9.
9. Rethoré MO, Prieur M, de Blois MC, Naffah J, Ravel A, Villain E, et al. Reciprocal syndromes caused by deficiency duplication resulting from maternal t(10;18)(p12;q22) translocation. *Ann Genet* 1985;28:149-53.
10. Forabosco A, Bernasconi S, Giovannelli G, Dutrillaux B. Trisomy of the distal third of the long arm of chromosome 10. Report of a new case due to a familial translocation t(10;18) (q24;p11). *Helv Paediatr Acta* 1975;30:289-95.