

Homemade Cardiac and Vein Cannulation Ultrasound Phantoms for Trauma Management Training in Resource-Limited Settings

Ameer Al-Hadidi, Mukarram Amine¹, Amir Batman, Wael Hakmeh²

Beaumont Health, Royal Oak, MI, USA, ¹MacNeal Hospital, Berwyn, IL, USA, ²Department of Emergency Medicine, School of Medicine, Western Michigan University, Kalamazoo, MI, USA

Access this article online

Website: www.avicennajmed.com

DOI: 10.4103/ajm.ajm_196_20

Quick Response Code:



ABSTRACT

Ultrasound has become an essential skill for trauma management in resource-limited areas. Prohibitive costs of commercial ultrasound phantoms limit the abilities of many hospitals to adequately train health-care providers. We assessed the utility of homemade phantoms in a wartime setting. Thirty physicians and technicians enrolled in a medical training course, sponsored by the Syrian American Medical Society (SAMS). Ultrasound simulation models were created onsite by using psyllium, gelatin, a hotel coffee maker, and Pyrex dishes. Lamb hearts were used to teach visual diagnosis and subsequent drainage of pericardial effusions. Penrose drains were used to teach vein identification and cannulation under dynamic ultrasound guidance. Two phantoms with a total of 14 penrose drains were created, serving 30 health-care providers. Feedback from participants was positive and within one month of the course, two cases of pericardial tamponade were diagnosed and surgically treated in the largest trauma hospital operated by SAMS. **Context:** In resource-limited environments, ultrasound phantoms (models) are cost-prohibitive. **Aims:** We assessed the utility of homemade phantoms in a resource-limited wartime setting to train Syrian physicians and technicians in vein cannulation and limited cardiac ultrasonography. **Settings and Design:** Thirty physicians and technicians enrolled in a medical training course, sponsored by SAMS. **Methods:** Ultrasound simulation models were created onsite by using psyllium, gelatin, a hotel coffee maker, and Pyrex dishes. Lamb hearts were used to teach visual diagnosis and subsequent drainage of pericardial effusions. Penrose drains were used to teach vein identification and cannulation under dynamic ultrasound guidance. Two phantoms with a total of 14 penrose drains were created, serving 30 health-care providers. **Statistical Analysis Used:** N/A **Results:** Feedback from participants was positive and within one month of the course, two cases of pericardial tamponade were diagnosed and surgically treated in the largest trauma hospital operated by SAMS. **Conclusions:** Homemade ultrasound phantoms are a promising cost-effective means for meeting an educational gap in ultrasound training, particularly for resource-limited hospitals and possibly more broadly in residency education.

Key words: Cardiac, central line, education, effusion, phantom, SAMS, Syria, tamponade, ultrasound, vein, war

This is an open access journal, and articles are distributed under the terms of the Creative Commons Attribution-NonCommercial-ShareAlike 4.0 License, which allows others to remix, tweak, and build upon the work non-commercially, as long as appropriate credit is given and the new creations are licensed under the identical terms.

For reprints contact: reprints@medknow.com

Cite this article as: Al-Hadidi A, Amine M, Batman A, Hakmeh W. Homemade cardiac and vein cannulation ultrasound phantoms for trauma management training in resource-limited settings. *Avicenna J Med* 2021;11:42-5.

Address for correspondence: Dr. Wael Hakmeh, Department of Emergency Medicine, School of Medicine, Western Michigan University, 1000 Oakland Drive, Kalamazoo, MI 49008, USA. E-mail: whakmeh@yahoo.com

Key Messages: Homemade ultrasound phantoms provide a useful alternative to commercially available phantoms, which are cost-prohibitive for those in low-resource environments. Physicians and technicians were able to identify pericardial effusion and practice vein cannulation by using these homemade models, leading to improved trauma care.

INTRODUCTION

The use of ultrasound in the management of trauma has become an essential skill in emergency medicine and surgery, particularly in resource-limited areas of conflict. The extended Focused Assessment using Sonography for Trauma (eFAST) ultrasound exam can identify causes of shock, including pericardial tamponade, tension pneumothorax, and intraperitoneal hemorrhage. Ultrasound can also assist with IV access, particularly in vasoconstricted patients in shock or when central venous catheters and intraosseous needles are in shortage. Severe resource limitations and a lack of computed tomography have led to the expanded use of ultrasonography, particularly in field hospitals in Syria, currently the site of the largest humanitarian crisis in the world. Opportunities for education in ultrasound training are lacking, in great part due to prohibitive costs of commercial brand name ultrasound phantoms, such as the Blue Phantom, that range from \$449 to more than \$18,000 per device for venous cannulation and pericardiocentesis simulation.^[1] Functional, cost-effective, and high-fidelity models for training health-care providers in low-resource settings are lacking.

SUBJECTS AND METHODS

Thirty physicians and technicians enrolled in a three-day emergency medicine and critical care training course in Gaziantep, Turkey, sponsored by SAMS. Homemade ultrasound simulation models were created to teach participants ultrasonographic diagnosis of pericardial effusions that may cause pericardial tamponade, and vein identification and cannulation under dynamic ultrasound guidance.

For the vein cannulation phantom, the majority of ingredients were purchased from a nearby supermarket. A hotel coffee maker was used to boil water from a 0.5 L bottle, which was mixed with six packages (8.5 gm each) of sugar-free gelatin (which serves as a good acoustic window) and two tablespoons of sugar-free psyllium powder (which added echotexture to simulate tissue granularity). One 3-cm layer of this mixture was poured into a 15" × 10" × 2" (5.9 × 3.9 × 0.8 cm) Pyrex rectangular glass baking dish and was refrigerated until it congealed. Seven penrose drains

measuring 8 inch × 0.25 inch (45.7 cm × 0.64 cm) were cut in half, tied at one end, completely filled with water to minimize the presence of air (a poor acoustic window) that could obstruct visualization, tied at the other end, and placed side by side approximately 1 cm apart on top of the first layer of the mixture. A second layer of the gelatin–psyllium mixture was poured over the first layer and penrose drains and again refrigerated for another three to four hours [Figure 1].

For the cardiac phantom, a lamb heart purchased from a nearby butcher was placed inside a water-filled sterile glove, which simulated a pericardial effusion, whereas another lamb heart was placed adjacent to it simulating a normal subxyphoid ultrasound view of the heart. In a large bowl, both hearts were placed within the gelatin–psyllium mixture, which congealed in the refrigerator. Again, two layers were made, similar to the vein cannulation phantom described earlier [Figure 2].

RESULTS

Syrian technicians and physicians were trained to properly identify and practice vein cannulation by using a portable GE Vscan ultrasound. In addition, they learned how to differentiate a normal cardiac view from a pericardial effusion mimicking cardiac tamponade. Participants verbalized satisfaction with the ability to learn proper technique and practice on ultrasound phantoms. Within one month of the course, one of the study authors was informed of two cases of surgically confirmed pericardial tamponade diagnosed and surgically treated in the largest trauma hospital operated by SAMS in Northern Syria [Figure 2]. Both patients survived.

Total cost was approximately \$40 total for multiple ultrasound phantoms, much less than \$400 per unit as sold commercially. The majority of the cost was for the Pyrex glassware, which can be reused for phantoms or cooking, or often easily borrowed. The remainder of the ingredients can be used again (only four of 114 tablespoons of psyllium were used) or taken from hospital supplies (such as penrose drains).

DISCUSSION

Reliance on ultrasound in resource-limited environments, particularly those in areas of conflict lacking computed




Figure 1: Left upper: Supplies for homemade phantom. Right upper: Trainee practicing vein cannulation. Lower: Phantom vein at top of screen at 0.5-cm mark in middle of screen

tomography, continues to increase. This coincides with the proliferation of indications for ultrasound use in emergency medicine over the past 20 years, including peripheral IV cannulation under dynamic ultrasound guidance, which has become a best practice in the United States for most non-emergent central lines. The need for training phantoms for ultrasound-guided venous access and for identification of pericardial effusion in trauma is greater than ever. Resource limitations and budget constraints in academic emergency departments in conjunction with the cost-prohibitive prices of ultrasound phantoms on the market limit the ability of many residency programs to purchase ultrasound phantoms. The difficulty in obtaining such expensive technology is even more pronounced for resource-limited field hospitals serving patients with trauma.

We used 0.25-inch penrose drains, as this size is closer in diameter to larger antebraial veins. The 0.375- or 0.5-inch penrose drains would more accurately simulate larger central veins such as jugular or femoral veins. The models tolerated

about ten attempts per penrose drain using 18 g needles. Smaller gauge needles appeared to allow for more cannulation attempts before the penrose drain lost its structural integrity.

Darker-colored gelatin rendered the phantom opaque, limiting the participant's ability to visualize the location of the penrose drains without ultrasound guidance. Penrose drains can be utilized to simulate arteries by increasing the pressure (by inserting more water) within them. Sugar-free gelatin and psyllium are less prone to mold formation compared with their sugar-based counterparts.

Similar models have been described as using gelatin,^[2] silicone,^[3] ballistics gel,^[4] wax,^[5,6] and tofu.^[7] We believe that, for very low-resource environments, this is a highly functional, low-cost phantom using readily available products and low start-up costs.

In conclusion, homemade ultrasound phantoms are a promising cost-effective means for meeting an educational

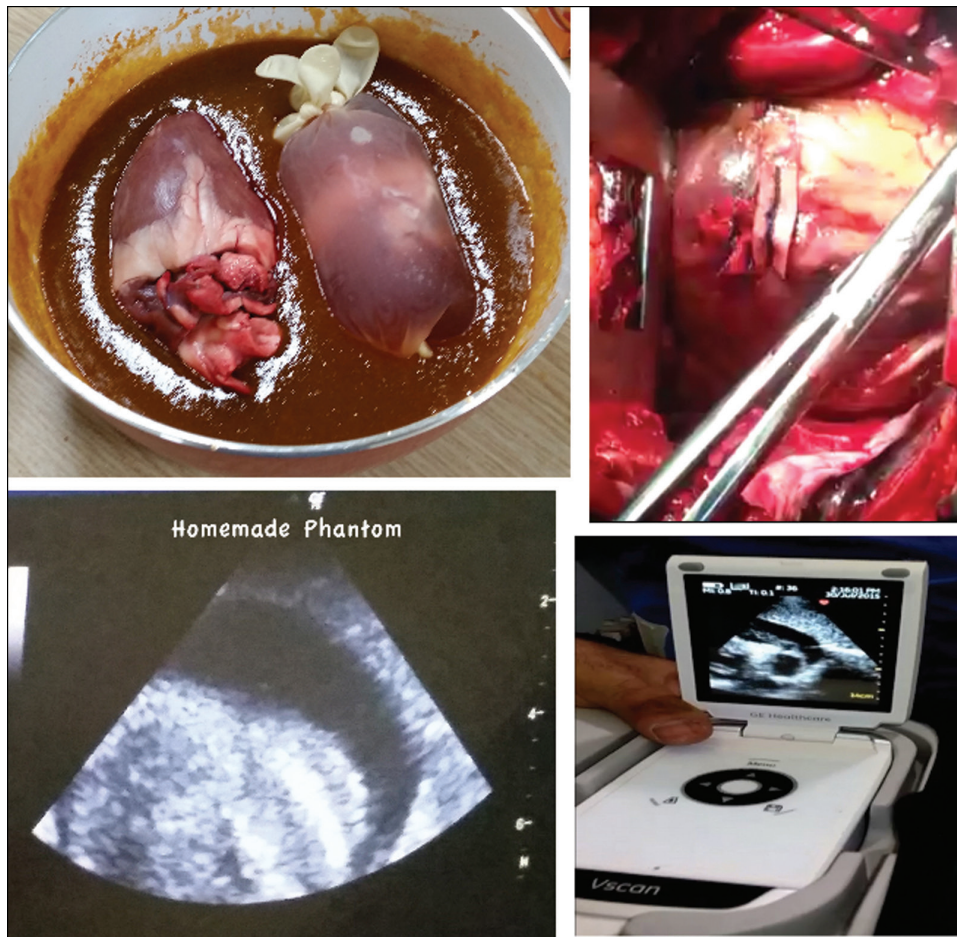


Figure 2: Left upper: Normal heart on left with heart simulating pericardial effusion on right. Left lower: Image of pericardial effusion on ultrasound phantom. Right lower: Image of pericardial effusion on real patient with cardiac tamponade. Right upper: Intra-operative picture of patient with cardiac tamponade from right lower picture

gap in ultrasound training, particularly for resource-limited hospitals and possibly more broadly in residency education. Further studies should quantify both subjective and objective benefits from such models.

Financial support and sponsorship

Nil.

Conflicts of interest

There are no conflicts of interest.

REFERENCES

1. By Phantom Type - Cardiac. Blue Phantom. https://www.bluephantom.com/category/By-Phantom-Type_Cardiac.aspx. Accessed July 30, 2020.

2. Kendall JL, Faragher JP. Ultrasound-guided central venous access: A homemade phantom for simulation. *CJEM* 2007;9:371-3.

3. Brown RF, Tignanelli C, Grudziak J, Sumerlin-Long S, Laux J, Kiser A, *et al.* A comparison of a homemade central line simulator to commercial models. *J Surg Res* 2017;214:203-8. doi:10.1016/j.jss.2017.02.071

4. Amini R, Kartchner JZ, Stolz LA, Biffar D, Hamilton AJ, Adhikari S. A novel and inexpensive ballistic gel phantom for ultrasound training. *World J Emerg Med* 2015;6:225-8. doi:10.5847/wjem.j.1920-8642.2015.03.012

5. Campo Dell'orto M, Hempel D, Starzetz A, Seibel A, Hannemann U, Walcher F, *et al.* Assessment of a low-cost ultrasound pericardiocentesis model. *Emerg Med Int* 2013;2013:376415.

6. Daly R, Planas JH, Edens MA. Adapting gel wax into an ultrasound-guided pericardiocentesis model at low cost. *West J Emerg Med* 2017;18:114-6.

7. Kalivoda EJ, Sullivan A, Bunting L. A cost-effective, rapidly constructed simulation model for ultrasound-guided pericardiocentesis procedural training. *J Emerg Med* 2019;56:74-9.