

Onychoptosis: a forgotten sign in syphilis infection

Ahmad A. Al-Awwad, Omar Abdelmaksoud¹, Abdulmawla Albirini

Department of Neurology, University of Oklahoma Health Sciences Center, Oklahoma City, USA, ¹Department of Neurology, Benha University, Benha, Egypt

Access this article online

Website: www.avicennajmed.com

DOI: 10.4103/ajm.ajm_215_19

Quick Response Code:



ABSTRACT

Onychoptosis is the periodic shedding and falling of one or more nails, in whole or part. It can be seen after fever, trauma, adverse reaction to medications, and in systemic illnesses including syphilis (syphilitic onychia). We report a case of 38-year-old man presented with subacute bilateral retrobulbar optic neuritis. Physical examination revealed diffuse onychoptosis which lead into the diagnosis of neurosyphilis. Symptoms significantly improved with appropriate treatment with intravenous penicillin G for 14 days.

Key words: Neurosyphilis, onychoptosis, syphilis, syphilitic onychia

Key messages:

- Patients with syphilis can present with wide spectrum of cutaneous manifestations including onychoptosis.
- Syphilis should be suspected in all patients with idiopathic persistent onychoptosis.
- Prolonged high-dose intravenous penicillin is the treatment of choice for neurosyphilis and should be initiated as early as possible to prevent devastating irreversible complications.

INTRODUCTION

Onychoptosis (from Greek onyx “nail” and ptôsis, “falling”) is a condition in which part or all of the nail sheds periodically and falls off the finger; it can affect one or more nails. Onychoptosis could happen as a result of fever, trauma, adverse reaction to medications, and in systemic illnesses. It also occurs in secondary syphilis infection where it is referred to “syphilitic onychia.”^[1,2] We discuss a case of 38-year-old man who presented with subacute bilateral retrobulbar optic neuritis that was preceded with 3 months of persistent onychoptosis and he was found to have neurosyphilis.

CASE SUMMARY

A 38-year-old man with history of high-risk sexual behavior presented with 6-week progressing vision loss in both eyes. Eye examination showed severe decrease in visual acuity in both eyes (20/400 in the right eye and 20/300 in the left) and mild-to-moderate swollen disk bilaterally. Physical examination

also revealed diffuse onychoptosis [Figures 1 and 2] which patient developed 3 months prior to his presentation. The rest of the physical examination was unremarkable. No other cutaneous or genital lesions were observed. Onychoptosis prompted sending sexually transmitted disease (STD) panel, which revealed positive syphilis immunoglobulin G (IgG)/immunoglobulin M (IgM) antibody. Rapid plasma reagin (RPR) was reactive with titer of 1:256. Serum fluorescent treponemal antibody absorption (FTA-ABS) was also reactive. The rest of STD panels including hepatitis C and HIV tests were negative. Neuroaxis magnetic resonance imaging (MRI) revealed equivocal T2 signal abnormality with contrast enhancement in the optic nerve bilaterally consistent with bilateral retrobulbar optic neuritis. Cerebral spinal fluid (CSF) testing showed normal glucose of 62 milligrams per deciliter (mg/dL) (reference range, 40–70), no red blood cells, elevated

This is an open access journal, and articles are distributed under the terms of the Creative Commons Attribution-NonCommercial-ShareAlike 4.0 License, which allows others to remix, tweak, and build upon the work non-commercially, as long as appropriate credit is given and the new creations are licensed under the identical terms.

For reprints contact: reprints@medknow.com

Cite this article as: Al-Awwad AA, Abdelmaksoud O, Albirini A. Onychoptosis: A forgotten sign in syphilis infection. *Avicenna J Med* 2020;10:122-4.

Address for correspondence: Dr. Ahmad A. Al-Awwad, Department of Neurology, University of Oklahoma Health Sciences Center, 920 Stanton L. Young Blvd. Williams Pavilion; Suite 2040, Oklahoma City, OK 73104, USA.
E-mail: a.alawwad@yahoo.com

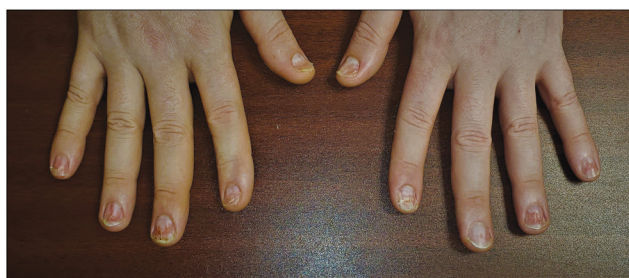


Figure 1: Diffuse onychoptosis involving all fingernails

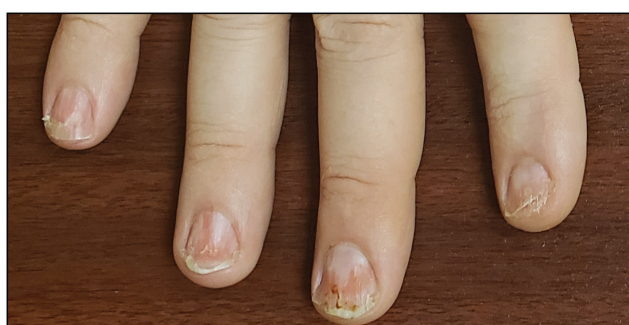


Figure 2: Onychoptosis involving all fingernails of the right hand. Periungual tissue remains intact

white blood cells of 32 cell per microliter (reference range, 0–5) of which 96% were lymphocytes, and elevated total protein of 57 mg/dL (reference range, 15–45). CSF culture and gram stain were unremarkable. Given the presence of pleocytosis and elevated total protein in CSF in the setting of active syphilis infection with optic nerve involvement, the diagnosis of neurosyphilis was made. Patient was treated with 4-million-unit aqueous penicillin G intravenously every 4h for 14 days. On 1-month follow-up, onychoptosis completely resolved, visual acuity improved to 20/300 in the right eye and 20/100 in the left, and fundoscopy revealed normal optic nerves bilaterally.

DISCUSSION

Syphilis, the “great imitator” of skin diseases, is a chronic systemic infectious disease caused by spirochete *Treponema pallidum*. It is an STD that can also be transmitted vertically.^[3,4] It is estimated that there are 5.6 million new cases every year with highest rate in Africa.^[3] Centers for Disease Control and Prevention (CDC) reported that in 2018 there were 115,000 cases of syphilis and ~1300 cases of congenital syphilis in the United States yielding 13.3% and 39.7% rate increase prospectively comparing with 2017.^[5] Although syphilis is a reportable condition in the United States, rates of neurosyphilis are not known partially due to surveillance definitions requiring data that are often unavailable. However, neurosyphilis generally develops more in patients with HIV, especially those who are untreated, have low CD4+ counts, or have detectable HIV RNA levels.^[4]

There are multiple stages of syphilis: Primary (painless chancre appears after 9–90 days following acquisition of *T. pallidum*) which progresses if untreated to secondary syphilis (presents 12 weeks–12 months after infection) which most often involves epithelial surfaces along with constitutional symptoms and signs (fever, malaise, and generalized lymphadenopathy). Similar to primary disease, the acute manifestations of secondary syphilis typically resolve spontaneously as known as latent syphilis where there is serological proof of infection but no symptoms. Syphilis will progress to tertiary disease in one-third of patients without treatment roughly 20–40 years after primary infection.^[6] Tertiary syphilis involves a severe and self-destructive immune response to a persistent low-level burden of *T. pallidum*. This can present as neurosyphilis, cardiovascular syphilis, or late benign syphilis (appears as granulomas, gummas, and psoriasiform plaques).^[6-8]

It is important to emphasize that neurological symptoms can occur during any phase of syphilis infection. Historically (in the pre-antibiotic era) neurosyphilis used to occur in 25%–35% of syphilis patients^[4,9] and symptomatic neurosyphilis developed in 4%–9% of patients.^[7] There are no standard tests for the diagnosis of neurosyphilis; hence, the diagnosis of neurosyphilis is based on clinical signs and symptoms and CSF findings.^[4] CSF abnormalities include mild pleocytosis (10–400 cells per microliter) and elevated protein concentrations (46–200 mg/dL). Venereal Disease Research Laboratory test in the CSF (CSF-VDRL) is highly specific but insensitive. When CSF-VDRL is negative, the diagnosis of neurosyphilis can be made based on the presence of clinical signs of neurosyphilis, reactive serologic test results, and abnormal CSF cell count and/or protein.^[9]

The eye is relatively uncommon site of syphilitic infection. However, syphilis can affect almost any eye structure with posterior uveitis and panuveitis are the most common place to be involved. When ocular syphilis occurs, it is often accompanied by optic nerve involvement including perineuritis, papillitis, optic neuritis, and retrobulbar neuritis (which is what happen in our case).^[10,11]

Despite its rarity, nail involvement in syphilis has been well established in medical literature. It can be divided into syphilitic onychia (changes on nail plate) and syphilitic paronychia (changes in periungual tissue). Syphilitic onychia involves multiple manifestations including nail pitting, onycholysis (detachment of the nail from its bed), onychogryphosis (one side of the nail to grow faster than the other), onychomadesis (proximal separation of the nail plate from the nail matrix due to a temporary

cessation of nail growth), and onychoptosis (as in our patient) where in syphilitic paronychia there is painful violaceous inflammatory indurations that appear around nail folds, rarely transforming into abscesses.^[2,12,13] Although ocular syphilis is treated with the same regimen used for neurosyphilis (IV aqueous penicillin G 18–24 million units per day for 10–14 days), syphilitic onychia is considered a form of secondary syphilis and hence the treatment would be shorter and consists of single dose of benzathine penicillin G 2.4 million units given intramuscularly.^[4,9]

CONCLUSION

Syphilis can present with a wide range of clinical manifestations involving various systems including eyes and nails. It is important for physicians to be aware of these possible manifestations on syphilis infection. The presence of onychoptosis on physical examination can help in reaching the diagnosis of syphilis where starting the proper treatment early can stop any further potentially irreversible damage.

Financial support and sponsorship

Nil.

Conflicts of interest

There are no conflicts of interest.

REFERENCES

1. Macleod JM. Syphilitic onychia. *Proc R Soc Med* 1910;3:59-60.
2. Dourmishev LA, Dourmishev AL. Syphilis: Uncommon presentations in adults. *Clin Dermatol* 2005;23:555-64.
3. Peeling RW, Mabey D, Kamb ML, Chen XS, Radolf JD, Benzaken AS. Syphilis. *Nat Rev Dis Primers* 2017;3:17073.
4. Ghanem KG, Ram S, Rice PA. The modern epidemic of syphilis. *N Engl J Med* 2020;382:845-54.
5. 2018 STD Surveillance Report. Available from: <https://www.cdc.gov/nchhstp/newsroom/2019/2018-STD-surveillance-report.html>. [Last accessed on 2019 Oct 8].
6. Clark EG, Danbolt N. The Oslo study of the natural history of untreated syphilis; an epidemiologic investigation based on a restudy of the Boeck-Bruusgaard material; a review and appraisal. *J Chronic Dis* 1955;2:311-44.
7. Hook EW 3rd, Marra CM. Acquired syphilis in adults. *N Engl J Med* 1992;326:1060-9.
8. Mattei PL, Beachkofsky TM, Gilson RT, Wisco OJ. Syphilis: A reemerging infection. *Am Fam Physician* 2012;86:433-40.
9. Workowski KA, Bolan GA; Centers for Disease Control and Prevention. Sexually transmitted diseases treatment guidelines, 2015. *MMWR Recomm Rep* 2015;64:1-137.
10. Moradi A, Salek S, Daniel E, Gangaputra S, Ostheimer TA, Burkholder BM, *et al.* Clinical features and incidence rates of ocular complications in patients with ocular syphilis. *Am J Ophthalmol* 2015;159:334-43.e1.
11. Oliver SE, Aubin M, Atwell L, Matthias J, Cope A, Mobley V, *et al.* Ocular syphilis – eight jurisdictions, United States, 2014–2015. *MMWR* 2016;65:1185-88.
12. Baran R, Dawber R, Tosti A, Haneke E. *A Text Atlas of Nail Disorders*. London, UK: Martin Dunitz; 1996.
13. Haneke E. *Histopathology of the Nail: Onychopathology*, 1st edition. Section: 4.4.1. CRC Press. 2017.