

Sporadic Cisternal Oculomotor Nerve Schwannoma: A Rare Case with Review of Literature

Abstract

Cranial nerve schwannomas usually arise from sensory nerve and the occurrence of schwannoma in a motor nerve is rare, especially in sporadic cases. Oculomotor nerve schwannomas (ONS) are rare and they are unique as they arise from motor nerve. ONS palsy may or may not be the presenting feature of oculomotor schwannoma. We present the case of a young male with ONS, presenting with oculomotor nerve palsy along with features of raised intracranial pressure. Oculomotor schwannoma is described in literature only as case reports, and oculomotor nerve is also a rare site for schwannoma as being a motor nerve. In this article, we describe a case of cisternal ONS with review of pertinent literature.

Keywords: Cisternal, oculomotor nerve, schwannoma, total excision

Introduction

Schwannomas account for 7%–8% of all intracranial tumors, they commonly arise from vestibulocochlear nerve followed by trigeminal, glossopharyngeal nerve, vagal, facial, accessory, hypoglossal, oculomotor, cochlear, and abducens nerves are in the descending order of frequency.^[1] Oculomotor and trigeminal nerves can be seen involved in neurofibromatosis type II, but isolated oculomotor nerve schwannoma (ONS) involvement in nonneurofibromatosis is extremely rare. They usually present with oculomotor nerve palsy, headache, and rarely long tract signs. Approximately 38 cases of isolated ONS have been reported in literature [Table 1].^[2] The cisternal and cavernous segments of third nerve are commonly involved. In this report, we present a sporadic case of cisternal ONS with review of literature.

Case Report

A 27-year-old male presented to our hospital with complaints of headache, vomiting, and blurring of vision for the past 3 months and imbalance and swaying toward the right side for the past 1 month. Examination showed dilated pupil with ptosis on the right side, decreased visual acuity of 6/24 on Snellen chart, and relative afferent pupillary defect. Magnetic resonance imaging head revealed

a well-defined suprasellar mass lesion approximately 3 cm × 2.5 cm × 3.5 cm, T1 isointense, T2 heterointense, homogeneous, contrast-enhancing mass lesion with lobulated appearance seen compressing the midbrain and pushing and lifting up the third ventricle upward to the opposite side with proximal ventriculomegaly and periventricular lucencies [Figure 1a-d]. The mass lesion is predominantly seen in the interpeduncular cistern with extension across midline and compressing the cerebral peduncle, which seems to efface and displace the aqueduct [Figure 2c and d]. It extends anteriorly along the cavernous sinus toward superior orbital fissure with compression of adjacent optic nerve. Differential diagnosis at that time included meningioma, schwannoma of cranial nerve, vascular pathology (thrombosed giant aneurysm), and lymphoma.

The patient was planned for right frontotemporal craniotomy with transsylvian and subtemporal approach for excision of the tumor. Right frontotemporal craniotomy with zygotomy was done, craniotomy was done flush with the temporal base, and dura was opened based on sphenoid ridge. Brain was seen bulging on opening the dura, and ventricular tap was done to release cerebrospinal fluid. Sylvian fissure was opened from lateral to medial side, and

Raghavendra Marutirao, Suyash Singh, Kamlesh Singh Bhasiora, Satyadeo Pandey, Jayesh Sardhara, Kuntal Kanti Das, Arun Kumar Srivastava, Sushila Jaiswal¹, Sanjay Behari

Departments of Neurosurgery and ¹Pathology, SGPGIMS, Lucknow, Uttar Pradesh, India

Address for correspondence:
Dr. Kamlesh Singh Bhasiora,
Department of Neurosurgery,
SGPGIMS, Lucknow,
Uttar Pradesh, India.
E-mail: drkamleshbhasiora@gmail.com

Access this article online

Website: www.asianjns.org

DOI: 10.4103/ajns.AJNS_104_18

Quick Response Code:



How to cite this article: Marutirao R, Singh S, Bhasiora KS, Pandey S, Sardhara J, Das KK, *et al.* Sporadic cisternal oculomotor nerve schwannoma: A rare case with review of literature. Asian J Neurosurg 2018;13:1269-72.

This is an open access journal, and articles are distributed under the terms of the Creative Commons Attribution-NonCommercial-ShareAlike 4.0 License, which allows others to remix, tweak, and build upon the work non-commercially, as long as appropriate credit is given and the new creations are licensed under the identical terms.

For reprints contact: reprints@medknow.com

right temporal lobe was retracted medially to expose the tentorium and the tumor. Tentorial notch divided posteriorly to widen the exposure. The tumor was whitish soft to firm, partly suckable, and moderately vascular seen attached intimately to tentorium, extending posteriorly to basilar artery and posterior cerebral artery (PCA). Total excision of the tumor was done [Figure 2a and b]. Intraoperatively, 4th cranial nerve was identified along the margin of tent, but the 3rd cranial nerve could not be identified separately from the tumor as it was involving the whole cisternal part of the 3rd nerve.

Histopathological examination of the tumor tissue showed tumor composed of spindle cells having hypocellular and hypercellular areas alternating with each other. The hypercellular areas were composed of cells displaying elongated nuclei with bland nuclear morphology, formation of verrucae bodies, focal areas of hemorrhage, and hemosiderin-laden macrophages [Figure 3].

Postoperative contrast computed tomography head revealed total excision of the tumor. Postoperatively, the patient had right 3rd nerve deficit. At 2-month follow-up, the patient had improvement in headache with partial recovery of the right 3rd nerve palsy.

Discussion

Schwannomas are slow growing, encapsulated, and arising from the Schwann cells. They grow in expansile fashion displacing the adjacent structures rather than invading

them. These may be sporadic or hereditary, sporadic schwannomas are most commonly seen in the fourth and fifth decades of life, while hereditary schwannomas occur relatively early in the second and third decades. There is no sexual preference. Depending on the size, origin, location, and extent of the tumor, schwannomas produce various signs and symptoms but are usually asymptomatic when small. The first report of an isolated oculomotor nerve was published by Kovacs at an autopsy in 1927.^[3] There are 38 cases of solitary oculomotor schwannoma which have been reported in the literature; among them, 15 are male and 23 are female patients aged 8–74 years. Preoperative oculomotor dysfunction was manifested in 29 out of 38 cases.^[4] Cranial nerve schwannomas usually arise from sensory nerve, superior division of vestibular nerve being the most common site. Schwannoma of oculomotor nerve is very rare in nonneurofibromatous cases.

The oculomotor nerve exits the brainstem from the medial aspect of cerebral peduncle into the interpeduncular cistern, from where it courses between superior cerebellar artery and (PCA) and goes medial to the uncus before piercing the roof of cavernous sinus. At the roof, it lies in oculomotor cistern. It then travels along the lateral wall of cavernous sinus and then enters the orbit through the superior orbital fissure.

There are four types of oculomotor schwannomas as follows:^[5]

1. Orbital – In the orbit
2. Cavernous – In the cavernous sinus

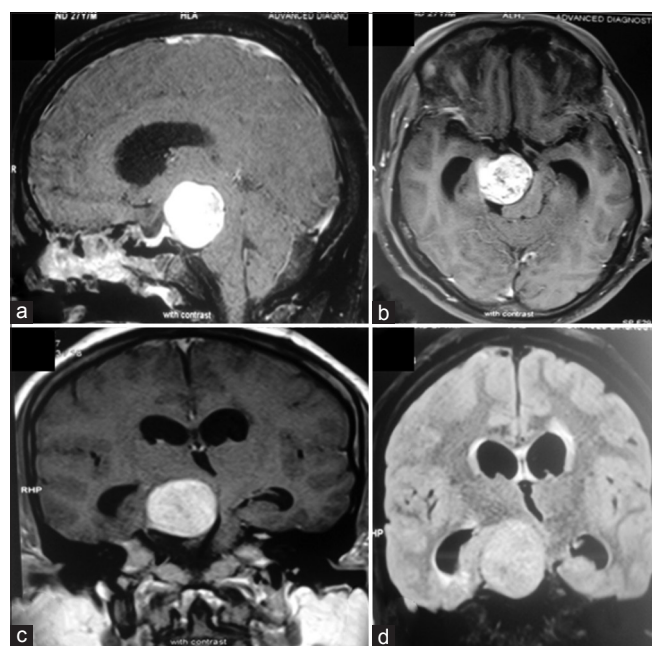


Figure 1: (a-d) Magnetic resonance imaging head axial cuts showing a well-defined oculomotor nerve schwannoma 3 cm × 2.5 cm × 3.5 cm, T1 isointense, T2 heterointense, homogeneous, contrast-enhancing mass lesion with lobulated appearance seen compressing the midbrain. (d) Coronal fluid-attenuated inversion recovery image with hyperintense, well-defined lesion

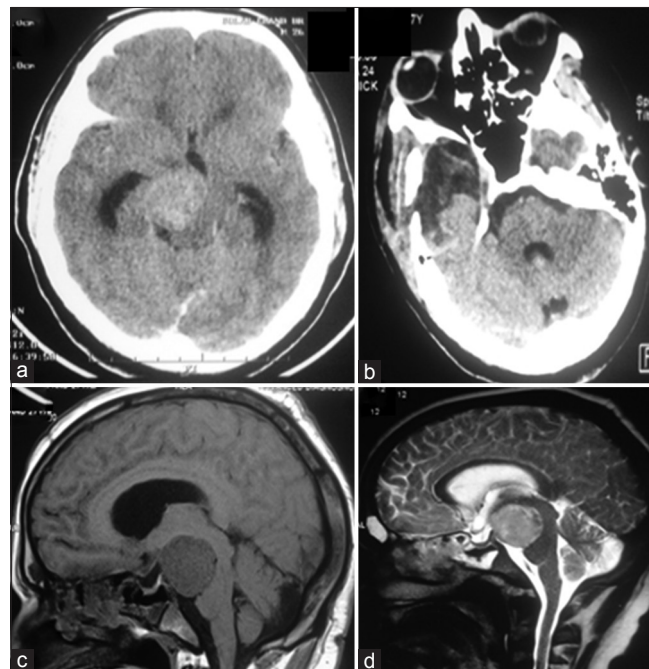


Figure 2: (a and b) Preoperative and postoperative computed tomography scan showing total excision of oculomotor nerve schwannoma. (c and d) Magnetic resonance imaging head sagittal cuts showing suprasellar mass lesion lifting up the third ventricle upward and to the opposite side with proximal ventriculomegaly and periventricular lucencies

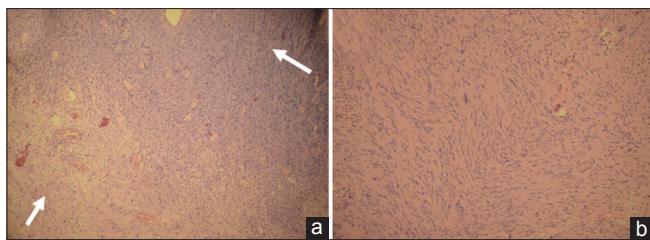


Figure 3: Histopathology section showing tumor displaying ($\times 200$: a) hypocellular, Antoni B (small arrow) and cellular, Antoni A (large arrow) area; ($\times 400$: b) spindle cells arranged in a palisading fashion or in an organoid arrangement (Verocay bodies)

3. Cisternocavernous – Extending from cavernous sinus to interpeduncular cistern
4. Cisternal – In the subarachnoid space.

Usually, cisternal segment is the most common site for oculomotor schwannoma (42%), followed by cavernous (31%) and cisternocavernous (21%). Orbital oculomotor schwannoma has been reported in only 6% of cases. Out of 38 cases reported in literature, the tumor was located in the orbit in four cases (solitary orbital type), in the subarachnoid space in 17 cases (cisternal type), in the cavernous sinus in 12 cases (cavernous type), and extending from the cavernous sinus to the cistern in five cases (cisternocavernous type).^[4] Most of the reported cases of oculomotor schwannoma are solid except three cases, which were cystic. The initial symptoms of oculomotor schwannoma include diplopia or ptosis (35%), headache or periorbital pain (29%), visual disturbance (13%), hemiparesis and gait disturbance (10%). Oculomotor nerve palsy was the most common preoperative neurological sign (87%). Other cranial nerves involved are trochlear nerve paresis (23%), trigeminal nerve (26%), and abducens nerve paresis (13%).^[5-9]

The accurate diagnosis is difficult, but clinical examination and radiological imaging with perioperative findings can help in diagnosing. Points favoring the diagnosis of oculomotor schwannoma are clinical examination revealing oculomotor nerve palsy and tumor location along the course of oculomotor nerve in the interpeduncular cistern. The common symptom of oculomotor schwannoma is headache with blurring of vision. Oculomotor palsy may not always be present and sometimes may present with visual deficits, so optic nerve masses such as glioma, schwannoma, or meningioma should be considered as preoperative diagnostic possibilities. In such cases, intraoperative findings help in confirming the origin of the tumor. In our case, the tumor was arising from the oculomotor nerve with compression of midbrain posteromedially and optic nerve anteromedially with stretching of trochlear nerve on the right side.

The frontotemporal craniotomy and zygotomy with transsylvian and subtemporal corridors provide adequate exposure for cisternal oculomotor schwannoma. After

opening dura, the sylvian fissure is opened wide and temporal lobe is retracted medially to expose the free margin of tentorium. In this approach, one gets wide exposure with minimum brain retraction, but there is risk of injury to trochlear attachment of superior oblique muscle with resultant diplopia, pulsatile exophthalmos. Tentorium is cut behind in the entrance of the fourth nerve. Subtemporal transzygomatic approach is better for tumor extending around interpeduncular cisterns. The excision of tumor should be started with internal decompression and, when tumor is sufficiently decompressed internally, then it should be dissected from all around. The surgical approach can be modified according to the extension of tumor.

The schwannomas are benign lesions, so total surgical resection of tumor is usual surgical goal. However, total resection of the oculomotor schwannoma may result in postoperative complete oculomotor palsy. Even partial or subtotal resection of tumor may lead to worsening of the oculomotor nerve function. Some authors recommend “wait-and-see” policy for asymptomatic patients with oculomotor schwannoma.^[10,11] Asoaka *et al.* recommended surgical removal only for large tumors with symptoms of mass effect.^[10] In patients with small tumors without mass effect, gamma Knife radiosurgery is very effective, safe, and minimally invasive treatment modality for treating not only oculomotor schwannomas, but also those arising from trochlear and abducens nerves without risking the nerve function.^[12] Netuka and Benes^[3] and Schultheiss *et al.*^[13] have reported total resection of oculomotor schwannoma without permanent 3rd nerve palsy. Location of tumor may influence the extent of tumor resection in a case of oculomotor schwannoma. Tanriover *et al.* described that the chance of oculomotor nerve injury after surgical resection may increase as the resection proceeds more anteriorly toward the superior orbital fissure.^[14]

Conclusion

Suprasellar tumors being an ONS is a very rare entity.^[15] Preoperative diagnosis of oculomotor schwannoma is often difficult because of nonspecificity of radiological findings in this region. Common differential diagnoses explaining this anatomical location are meningioma, trigeminal schwannoma, thrombosed aneurysm, and pericavernous tumors; in doubtful cases, tracing the anatomical substrate involved is of prime importance. To diagnose oculomotor schwannomas, intraoperative finding along with preoperative clinical examination and postoperative histopathological examination findings is needed. Total removal of tumors is usually followed by oculomotor nerve palsy, which may worsen the preoperative symptoms, so management decision in patients with intact or partially involved 3rd nerve function is difficult. Smaller tumor with preserved 3rd nerve function can be managed conservatively or with gamma knife; in cases with larger tumor, subtotal excision may be an option.

Table 1: Reported cases of cisternal oculomotor schwannoma in literature

Author	Age (years)/sex	Initial symptoms	Diameter (mm)	Resection	Postoperative 3 rd nerve palsy
Okamoto <i>et al.</i> (1985)	52/female	Exophthalmos, seizure	-	Subtotal resection	Yes
Katsumat <i>et al.</i> (1990)	47/male	Diplopia, ptosis	15	Total resection	ND
Lunardi <i>et al.</i> (1990)	60/female	Hemiparesis, ptosis	-	Total resection	Yes
Kadota <i>et al.</i> (1993)	41/male	Ptosis, diplopia	20	Total resection	ND
Schultheiss <i>et al.</i> (1993)	65/male	Incidental	8	Total resection	No
Niazi and Boggan (1994)	13/male	Hemiparesis, diplopia, headache, dysarthria	-	Subtotal resection	Yes
Asaoka <i>et al.</i> (1999)	64/female	Headache	15	Subtotal resection	No
Katoh <i>et al.</i> (2000)	66/female	No symptoms	-	Subtotal resection	Yes
Lingwai (2000)	53/male	Headache	5	Total resection	No
Hatakeyama <i>et al.</i> (2003)	33/male	Diplopia, ptosis	40	Total resection	No
Netuka <i>et al.</i> (2003)	12/female	Headache	28	Total resection	No
Tanriover <i>et al.</i> (2007)	34/female	Anisocoria, ptosis, headache, exotropia	20	Subtotal resection	No
Prabhu and Bruner (2009)	38/female	Headache, diplopia, ptosis, dizziness	35	Total resection	Yes
Iijima <i>et al.</i>	37/female	Cognitive impairment, anisocoria	50	Subtotal resection	Yes
Yang <i>et al.</i> (2013)	3/male	Irritability, confusion	13	Total resection	Yes
Present case	24/male	Headache, vomiting, blurring of vision	27	Total resection	Yes

ND – Not discussed

Prior consent of patient was taken to publish radiological and clinical data.

Declaration of patient consent

The authors certify that they have obtained all appropriate patient consent forms. In the form, the patient has given his consent for his images and other clinical information to be reported in the journal. The patient understands that his name and initial will not be published and due efforts will be made to conceal their identity, but anonymity cannot be guaranteed.

Financial support and sponsorship

Nil.

Conflicts of interest

There are no conflicts of interest.

References

- Kumar LP, Monica I, Uppin MS, Kotiyala VJ. Large oculomotor nerve schwannoma – Rare entity: A case report with review of literature. *J Cancer Res Ther* 2014;10:1098-100.
- Cho YH, Sung KS, Song YJ, Kim DC, Choi S, Kim KU, *et al.* Oculomotor nerve schwannoma: A case report. *Brain Tumor Res Treat* 2014;2:43-7.
- Netuka D, Benes V. Oculomotor nerve schwannoma. *Br J Neurosurg* 2003;17:168-73.
- Ohata K, Takami T, Goto T, Ishibashi K. Schwannoma of the oculomotor nerve. *Neurol India* 2006;54:437-9.
- Furtado SV, Hegde AS. Management of oculomotor nerve schwannomas in two different locations: Surgical nuances and comprehensive review. *Neurosurg Rev* 2012;35:27-34.
- Kurokawa Y, Uede T, Honda O, Honmou O. Successful removal of intracavernous neurinoma originating from the oculomotor nerve – Case report. *Neurol Med Chir (Tokyo)* 1992;32:225-8.
- Katsumata Y, Maehara T, Noda M, Shirouzu I. Neurinoma of the oculomotor nerve: CT and MR features. *J Comput Assist Tomogr* 1990;14:658-61.
- Suenaga J, Tateishi K, Takase H, Kanno H, Kawahara N. Oculomotor nerve schwannoma presenting as an entirely cystic homogeneous mass on magnetic resonance imaging: Case report. *Austin Neurosurg Open Access* 2014;1:1013.
- Hatakeyama H, Saito K, Nagatani T, Patel SJ, Yoshida J. Schwannoma in the crural cistern removed without permanent functional deficits – Case report. *Neurol Med Chir (Tokyo)* 2003;43:95-9.
- Asaoka K, Sawamura Y, Murai H, Satoh M. Schwannoma of the oculomotor nerve: A case report with consideration of the surgical treatment. *Neurosurgery* 1999;45:630-3.
- Katoh M, Kawamoto T, Ohnishi K, Sawamura Y, Abe H. Asymptomatic schwannoma of the oculomotor nerve: Case report. *J Clin Neurosci* 2000;7:458-60.
- Kim IY, Kondziolka D, Niranjana A, Flickinger JC, Lunsford LD. Gamma knife surgery for schwannomas originating from cranial nerves III, IV, and VI. *J Neurosurg* 2008;109 Suppl: 149-53.
- Schultheiss R, Kristof R, Schramm J. Complete removal of an oculomotor nerve neurinoma without permanent functional deficit. Case report. *Ger J Ophthalmol* 1993;2:228-33.
- Tanriover N, Kemerdere R, Kafadar AM, Muhammedrezai S, Akar Z. Oculomotor nerve schwannoma located in the oculomotor cistern. *Surg Neurol* 2007;67:83-8.
- Prabhu SS, Bruner JM. Large oculomotor schwannoma presenting as a parasellar mass: A case report and literature review. *Surg Neurol Int* 2010;1:15.