

Isolated Intraventricular Rosai–Dorfman Disease

Abstract

Rosai–Dorfman disease (RDD) is a benign histioproliiferative disorder characterized by generalized lymphadenopathy, weakness, anemia, and rarely extranodal involvement. The disease affects the central nervous system (CNS) very rarely and at a relatively older age. Isolated intracranial involvement is very rare. RDD tends to present as dural masses mimicking meningioma, though very rare case reports describe isolated parenchymal involvement in the CNS. Only one case of intraventricular RDD has been described so far to the best of our knowledge. We present a very rare presentation of this disease as an isolated intraventricular presentation in the region of the atria of the lateral ventricles.

Keywords: Extranodal, intraventricular, Rosai Dorfman

Introduction

Intracranial involvement of Rosai–Dorfman disease (RDD) is rare. Isolated intracranial involvement is very rare and presents most commonly as dural lesions. Only one case of isolated intraventricular RDD has been described involving the fourth ventricle. Our case is the first case of RDD presenting as an intraventricular mass along the atria of the lateral ventricles.

Case Report

A 40-year-old woman came with complaints of headache for 1 year. The patient was conscious and oriented in time, place, and person. She did not have any history of fever, vomiting, and loss of consciousness. There was no organomegaly or lymphadenopathy on general examination. The central nervous system (CNS) examination findings were within the normal limits. Magnetic resonance imaging (MRI) brain with contrast revealed 4.3 cm × 3 cm × 3.8 cm intensely enhancing lobulated mass expanding the atrium and the occipital horn of the lateral ventricle with mild perilesional vasogenic edema [Figure 1a]. The lesion was seen extending into the right parietotemporal white matter. The right temporal horn of the lateral ventricle was dilated, and there was a midline shift of 4 mm [Figure 1a and b].

The lesion was thought to be of neoplastic etiology, possibly meningioma on MRI.

Hence, a right temporoparietal craniotomy and excision of the right atrial mass were done. The tumor mass was firm, with few congested areas *in situ*. The excised tumor was sent for histopathological examination.

On gross examination, the mass was firm, nodular, gray white with few yellowish areas measuring 4 cm × 2.5 cm × 1.5 cm [Figure 2].

Microscopic examination showed a cellular tumor consisting of polymorphous population of cells. It consisted mainly of sheets of histiocytes of varying sizes with foamy to the granular cytoplasm and showing emperipolesis of lymphocytes [Figure 3a and b]. Furthermore, present was marked infiltration by mature lymphocytes, plasma cells, and many Russell bodies [Figure 3c]. Foci of fibrosis, congestion, and focal clustering of vessels were seen. Few psammoma bodies were also seen. On immunohistochemistry (IHC), the histiocytes were strongly positive for CD68 and S100 [Figure 3d and e]. The lymphocytic population was polymorphic and showed CD3, CD20 positivity [Figure 3f and g] and also Kappa and lambda reactivity [Figure 3h and i]. On the basis of the classical histomorphology and the supportive IHC, diagnosis of extranodal RDD was made.

The patient had improved after the surgery and was asymptomatic on follow-up.

How to cite this article: Patwardhan PP, Goel NA. Isolated intraventricular Rosai–Dorfman disease. *Asian J Neurosurg* 2018;13:1285-7.

Pranav Pramod Patwardhan, Naina Atul Goel

Department of Pathology, Seth G. S. Medical College and K. E. M. Hospital, Mumbai, Maharashtra, India

Address for correspondence:

Dr. Naina Atul Goel,
Department of Pathology, Seth
G. S. Medical College and
K. E. M. Hospital, Mumbai,
Maharashtra, India.
E-mail: nainakataria123@
hotmail.com

Access this article online

Website: www.asianjns.org

DOI: 10.4103/ajns.AJNS_134_18

Quick Response Code:



This is an open access journal, and articles are distributed under the terms of the Creative Commons Attribution-NonCommercial-ShareAlike 4.0 License, which allows others to remix, tweak, and build upon the work non-commercially, as long as appropriate credit is given and the new creations are licensed under the identical terms.

For reprints contact: reprints@medknow.com

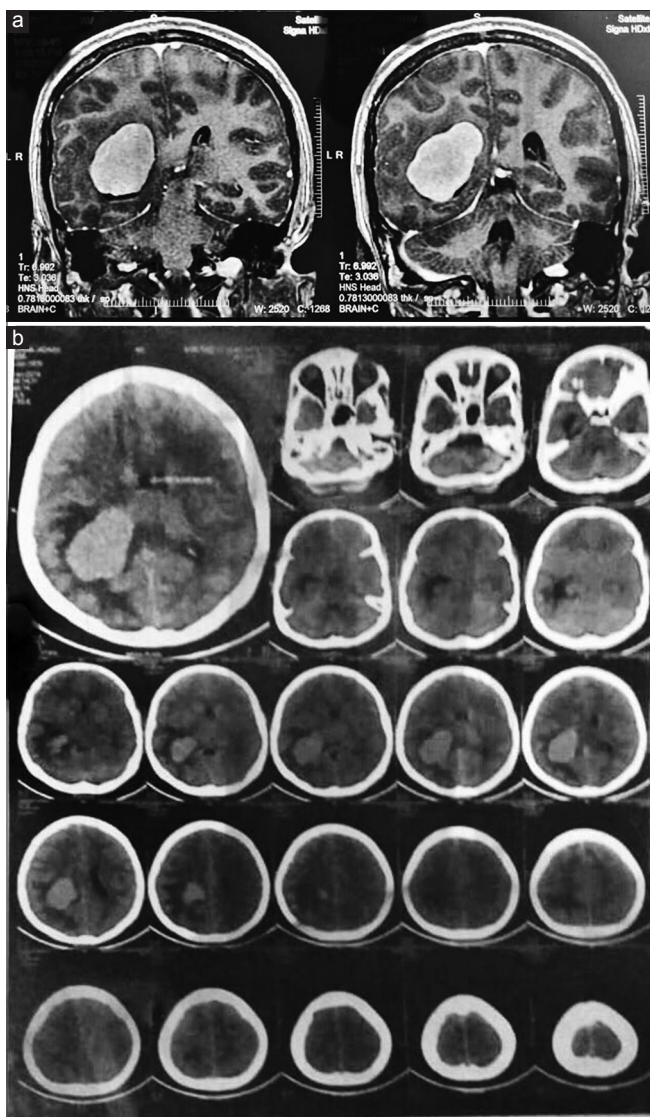


Figure 1: (a and b) Magnetic resonance imaging reveals an intensely enhancing lobulated mass expanding the atrium and the occipital horn of the lateral ventricle with mild perilesional vasogenic edema

Discussion

RDD is a rare benign lymphohistioproliferative disorder. The first report of RDD was described in 1959. It usually presents in the second or the third decades of life as painless lymphadenopathy, fever, and weight loss. Extranodal involvement is seen in 30% of the cases and may involve the skin, salivary gland, thyroid, and testis.^[1]

It tends to involve the CNS very rarely and in a slightly older age group.^[2] Isolated intracranial involvement is very rare, and there are <150 cases described.^[3] This involvement is most commonly in the form of dural-based masses mimicking meningiomas. These lesions may present in the suprasellar region, convexity, parasagittal region, cavernous sinus, petroclival region, and cerebellum. Two cases with locally aggressive features and dural sinus involvement have been reported by Toh *et al.*^[4] Pachymeningitis^[5]

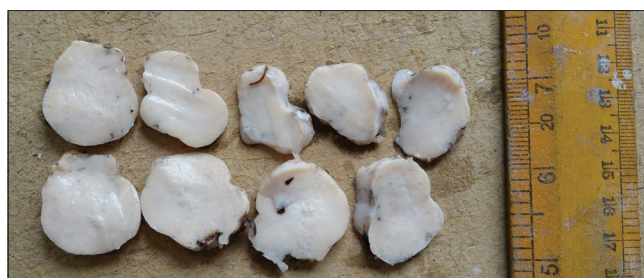

Figure 2: Gross examination: the mass is firm, nodular, gray white with the few yellowish areas

may also be the mode of presentation. Very rarely, parenchymal involvement mimicking lymphomas has been described.^[6] Only one case of intraventricular presentation has been described involving the fourth ventricle.^[7] The case with intraventricular presentation described in the literature was a 22-year-old woman, who had an enhancing mass on the floor of the fourth ventricle.^[7] Our case presented at a slightly older age as compared to the case presenting as a fourth ventricular mass and presented as an enhancing lobulated mass expanding the atrium and the occipital horn of the lateral ventricle. This is perhaps the first case presenting as an intraventricular mass in the region of the atrium. Radiologically, the lesion resembled meningiomas, as classically described, and the patient had no evidence of lymphadenopathy or hepatosplenomegaly. Thus, this was an isolated intraventricular presentation of RDD.

Patients with intracranial involvement tend to present with headache and seizures. They can also present with dysphasia, cranial nerve deficit, progressive loss of vision, hemiparesis, neglect, and endocrine dysfunction depending on the location of the lesion. Suprasellar involvement has been documented in five cases while involvement of the pituitary has been seen in only one case, in the form of diabetes insipidus.^[8] Our patient, however, presented with vague complaints of headache. She did not have any other signs or symptoms of raised intracranial tension at the time of presentation.

Microscopically, RDD is characterized by a polymorphous infiltration of histiocytes, plasma cells, and lymphocytes in a fibrotic background. Two types of histiocytes are seen, on the basis of the size. The large histiocytes classically show emperipolesis of lymphocytes and are S100 positive, while the smaller histiocytes may not show emperipolesis. Our case showed classical histomorphological features of RDD. The polymorphous population of lymphoid cells was confirmed by the presence of cells expressing both B- and T-cell markers on IHC. The macrophages were CD68 positive and S100 positive and showed emperipolesis of lymphocytes. The differential that was considered was Erdheim–Chester syndrome and Langerhans cell histiocytosis (LCH). However, as the patient did not have any skeletal or bony involvement clinically, the macrophages were S100 positive and no Touton giant cells were seen on histology, Erdheim–Chester disease was ruled

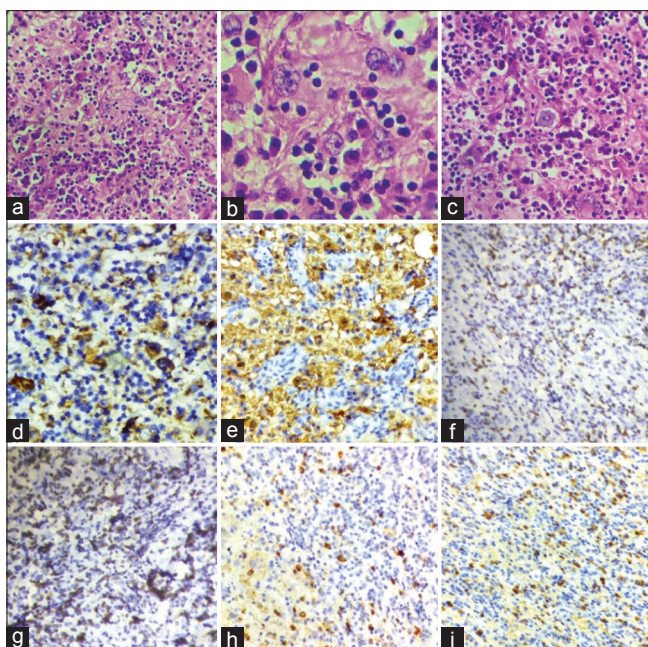


Figure 3: Microscopy showed: (a) histiocytes with prominent emperipolesis admixed with mature plasma cells and lymphocytes (H and E, $\times 40$). (b) Histiocytes with emperipolesis are seen. (c) Mature plasma cells with Russell bodies are seen. (d) Macrophages are CD68 positive. (e) Macrophages are S100 positive. (f) Lymphocytes are heterogeneous and consist of both CD3 positive and (g) CD20 positive cells. (h) Kappa and lambda (i) staining by IHC show no light chain restriction

out. The cells did not show cleaved or bean-shaped nuclei classical of LCH, and hence, the possibility of LCH was also ruled out.

The treatment of choice for intracranial RDD is surgery. Complete, incomplete resection, and biopsies have been attempted. The success rate is higher for the intracranial lesions which can be completely excised. There is definite progression of the disease when it is only biopsied. Our patient was also managed surgically, and complete excision of the mass was done.

Postoperatively, the patient improved symptomatically.

Conclusion

Isolated intracranial RDD is rare and tends to present most commonly as a dura-based lesion. However, rarely, it can

present at any site including the ventricles of the brain. Awareness of the rare presentation would help in early suspicion and treatment of such lesions in the future.

Declaration of patient consent

The authors certify that they have obtained all appropriate patient consent forms. In the form the patient(s) has/have given his/her/their consent for his/her/their images and other clinical information to be reported in the journal. The patients understand that their names and initials will not be published and due efforts will be made to conceal their identity, but anonymity cannot be guaranteed.

Financial support and sponsorship

Nil.

Conflicts of interest

There are no conflicts of interest.

References

1. Sanchez R, Rosai J, Dorfman RF. Sinus histiocytosis with massive lymphadenopathy: An analysis of 113 cases with special emphasis on its extranodal manifestation. *Lab Invest* 1977;36:21-2.
2. Foucar E, Rosai J, Dorfman R. Sinus histiocytosis with massive lymphadenopathy (Rosai-Dorfman disease): Review of the entity. *Semin Diagn Pathol* 1990;7:19-73.
3. Sandoval-Sus JD, Sandoval-Leon AC, Chapman JR, Velazquez-Vega J, Borja MJ, Rosenberg S, *et al*. Rosai-Dorfman disease of the central nervous system: Report of 6 cases and review of the literature. *Medicine (Baltimore)* 2014;93:165-75.
4. Toh CH, Chen YL, Wong HF, Wei KC, Ng SH, Wan YL. Rosai-Dorfman disease with dural sinus invasion. Report of two cases. *J Neurosurg* 2005;102:550-4.
5. Kinoshita Y, Yasukouchi H, Tsuru E, Yamaguchi R. Case report of Rosai-Dorfman disease mimicking pachymeningitis. *No Shinkei Geka* 2004;32:1051-6.
6. Sundaram C, Uppin SG, Prasad BC, Sahu BP, Devi MU, Prasad VS, *et al*. Isolated Rosai Dorfman disease of the central nervous system presenting as dural-based and intraparenchymal lesions. *Clin Neuropathol* 2005;24:112-7.
7. Morandi X, Godey B, Riffaud L, Heresbach N, Brassier G. Isolated Rosai-Dorfman disease of the fourth ventricle. Case illustration. *J Neurosurg* 2000;92:890.
8. Ng HK, Poon WS. Sinus histiocytosis with massive lymphadenopathy localized to the sella. *Br J Neurosurg* 1995;9:551-5.