

## Acute Ischemic Stroke due to Internal Carotid Artery Dissection in a 10-Year-Old Child

### Abstract

A 10-year-old girl was transferred to our hospital with left hemiparesis. Diffusion-weighted magnetic resonance imaging (MRI) of the brain showed a signal lesion in the right posterior limb of the internal capsule and magnetic resonance angiography showed poor visualization of the right internal carotid artery (ICA), and a defect area was present in a part of the supraclinoid portion of the right ICA. Based on the clinical and radiological findings, the patient was diagnosed with ischemic stroke due to right ICA dissection (ICAD). She received 5 days of intravenous argatroban followed by oral aspirin. A month later, her hemiparesis markedly improved. As early diagnosis of ICAD is crucial for prompt treatment in children with unexplained gross neurologic abnormalities, this disease should be suspected and MRI should be performed even without a history of blunt trauma to the head and neck.

**Keywords:** Acute stroke, internal carotid artery dissection, magnetic resonance angiography

### Introduction

Stroke is relatively rare in children but can lead to significant morbidity and mortality. Acute ischemic stroke in children has an incidence ranging from 3 to 8 per 100,000 children per year.<sup>[1]</sup> The likelihood of an acute ischemic stroke being secondary to an arterial dissection is reported to be as high as 20%.<sup>[2]</sup> We present the case of a right internal carotid artery (ICA) dissection (ICAD) that led to a thromboembolic ischemic stroke.

### Case Report

A previously healthy 10-year-old girl who presented with a headache and left hemiparesis was immediately transferred to our hospital. She had a manual muscle testing (MMT) score of 1 and also had left hemianopia and left hypoesthesia. Computed tomography (CT) showed no abnormal lesion [Figure 1a]. Diffusion-weighted magnetic resonance imaging (MRI) of the brain showed a signal lesion in the right posterior limb of the internal capsule [Figure 1b], and magnetic resonance angiography (MRA) showed poor visualization of the right ICA, and a defect area was present in a

part of the supraclinoid portion of the right ICA [Figure 1c]. MRA of the neck showed a thin and segmented stenosis in the right cervical ICA [Figure 1d]. T1 fat-saturated brain imaging showed a hyperintensity along the vessel wall [Figure 1e]. Three-dimensional CT angiography showed no abnormal findings in the aortic arch and other major arteries [Figure 1f]. Based on the clinical and radiological findings, the patient was diagnosed with ischemic stroke due to right ICAD. No cervical arterial vessel redundancy, tortuosity, or fibromuscular dysplasia was noted, and her transthoracic echocardiogram was normal. Serum autoimmune markers, inflammatory markers, and hypercoagulation panel were unremarkable. Moreover, given that she had no history of trauma, the ICAD was thought to be spontaneous. She received 5 days of intravenous argatroban (40 mg/day) followed by oral aspirin (100 mg/day). At 1 month, the infarction had not increased. In addition, the imaging appearance of the dissection did not change. Three months later, her hemiparesis markedly improved with an MMT score of 4, and the left hemianopia and left hypoesthesia had disappeared.

**Saori Otake,  
Yosuke Tajima,  
Michihiro Hayasaka,  
Tomohiro Sugiyama**

*Department of Neurosurgery,  
Kimitsu Chuo Hospital,  
Kisarazu City, Chiba, Japan*

#### Address for correspondence:

*Dr. Yosuke Tajima,  
Department of Neurosurgery,  
Kimitsu Chuo Hospital,  
1010 Sakurai, Kisarazu City,  
Chiba 292-8535, Japan.  
E-mail: tajima5615@yahoo.  
co.jp*

This is an open access journal, and articles are distributed under the terms of the Creative Commons Attribution-NonCommercial-ShareAlike 4.0 License, which allows others to remix, tweak, and build upon the work non-commercially, as long as appropriate credit is given and the new creations are licensed under the identical terms.

For reprints contact: WKHLRPMedknow\_reprints@wolterskluwer.com

**How to cite this article:** Otake S, Tajima Y, Hayasaka M, Sugiyama T. Acute ischemic stroke due to internal carotid artery dissection in a 10-year-old child. *Asian J Neurosurg* 2020;15:716-8.

**Submitted:** 08-Apr-2020 **Revised:** 02-May-2020  
**Accepted:** 11-May-2020 **Published:** 28-Aug-2020

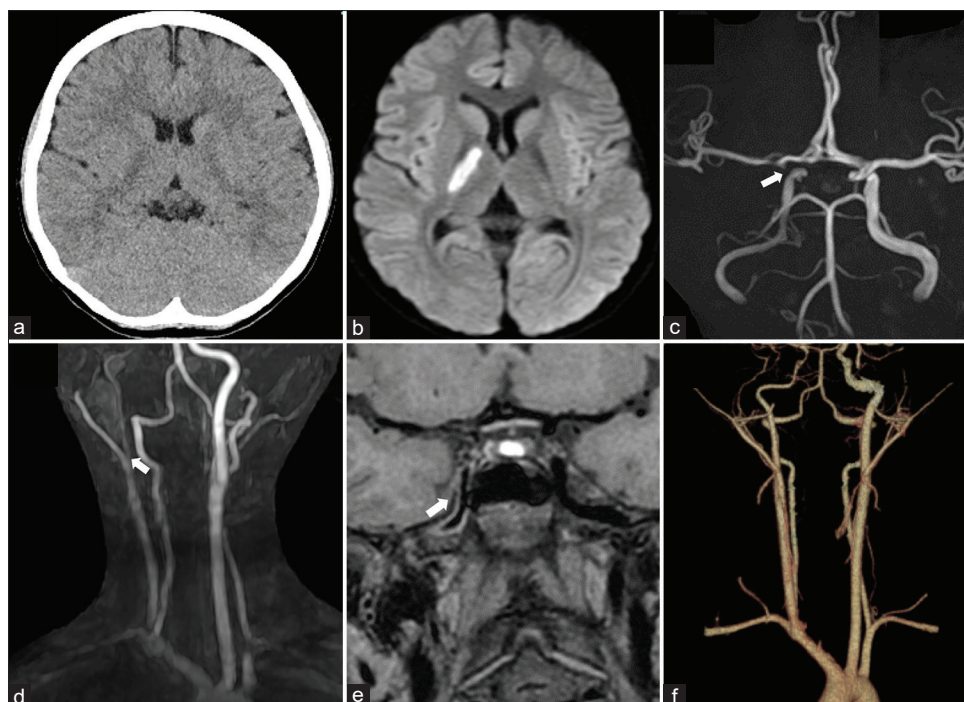
#### Access this article online

**Website:** [www.asianjns.org](http://www.asianjns.org)

**DOI:** 10.4103/ajns.AJNS\_146\_20

#### Quick Response Code:





**Figure 1:** (a) Computed tomography showing no abnormal lesion. (b) Diffusion-weighted imaging showing areas of restricted diffusion involving the right internal capsule. (c) Magnetic resonance angiography of the brain showing that a defect area was present in the right internal carotid artery (arrow). (d) Magnetic resonance angiography of the neck showing a thin and segmented stenosis in the right internal carotid artery. (e) T1 fat-saturated image of the brain showing a hyperintensity along the vessel wall (arrow). (f) Three-dimensional computed tomography angiography showing no abnormal findings in the aortic arch and the other major arteries

## Discussion

ICAD is one of the most important causes of acute ischemic stroke in children. Risk factors for ICAD in children include head-and-neck injury, connective tissue disorders (such as Ehlers–Danlos syndrome or Marfan’s syndrome), and the male sex.<sup>[2]</sup> Moreover, some reports show that there may be the relationships between rotational changes and tolerability to G forces and dissection, for example, with a water slide<sup>[3]</sup> and roller coaster.<sup>[4]</sup> However, it is important to note that spontaneous ICAD is frequently encountered as in the present case.

The diagnosis of ICAD is often difficult. MRI/MRA has become the first-line imaging modality for patients with suspected dissection. It is noninvasive, requires no radiation, and simultaneously images for dissection and acute ischemic stroke. MRI can visualize the intramural hematoma with T1 fat-saturated imaging as a hyperintensity along the vessel wall like in the present case.

The treatment of ICAD remains controversial as controlled studies are lacking. The utility of antiplatelet agents and anticoagulation remains unclear. According to previous studies in adults, thromboembolism is the primary mechanism of acute ischemic stroke in ICAD, and anticoagulation therapy is suggested for 3–6 months.<sup>[5]</sup> However, no prospective randomized study has been performed to support this treatment regimen. Moreover, even the use of antiplatelet therapy

is controversial. In a recent randomized controlled trial, it was not established whether antiplatelet therapy or anticoagulation was superior.<sup>[5]</sup>

In the present case, we initiated argatroban therapy in the acute stage, and after 5 days of anticoagulation, we commenced antiplatelet therapy and discontinued the anticoagulation. This therapy regimen appeared safe and effective.

Because of the rarity of acute ischemic stroke, diagnosis is often delayed and cases may remain under- or mis-diagnosed. In fact, CT could not detect any abnormal lesions in the present case. As early diagnosis of ICAD is crucial for prompt treatment in children with unexplained gross neurologic abnormalities, ICAD should be suspected and MRI should be performed even without a history of blunt trauma to the head and neck.

## Declaration of patient consent

The authors confirmed that all appropriate patient consent forms have obtained. In the form, the patient and her parents have given consent for her images and other clinical information to be reported in the journal. The patient and her parents understands that her names and initials will not be published and due efforts will be made to conceal their identity.

## Financial support and sponsorship

Nil.

### Conflicts of interest

There are no conflicts of interest.

### References

1. Pandey AS, Hill E, Al-Holou WN, Gemmete JJ, Chaudhary N, Thompson BG, *et al.* Management of pediatric craniocervical arterial dissections. *Childs Nerv Syst* 2015;31:101-7.
2. Zetterling M, Carlström C, Conrad P. Internal carotid artery dissection. *Acta Neurol Scand* 2000;101:1-7.
3. Akbas Y, Arban E, Serdaroglu A, Nazhel B. Internal carotid artery dissection following water slide use: The first case report. *Childs Nerv Syst* 2016;32:411-3.
4. Noh A, Vela-Duarte D, Grobelny T, Hoganson G, Pasquale D, Biller J. Internal carotid artery dissection after a roller coaster ride in a 4-year-old: Case report and review of the literature. *Pediatr Neurol* 2015;52:349-51.
5. Fullerton HJ, Johnston SC, Smith WS. Arterial dissection and stroke in children. *Neurology* 2001;57:1155-60.