

Case Report

Posterior Fossa Arteriovenous Malformation with Multiple Pedicle Aneurysms and Recruitment of Meningeal Supply

Abstract

Cerebral aneurysms arising on the peripheral posterior inferior cerebellar artery (PICA) are rare. Here, we present a unique case of arteriovenous malformation (AVM) with pedicle aneurysms arising on the peripheral PICA and recruited by meningeal supply. A 67-year-old woman presented with subarachnoid hemorrhage. Cerebral angiography revealed two saccular aneurysms on the peripheral PICA, which formed an abnormal arteriovenous shunt adjacent to the transverse sinus. The shunt was also fed by the ipsilateral superior cerebellar and contralateral posterior meningeal arteries. The proximal aneurysm was larger and deep seated while the distal aneurysm was smaller and located superficially. The patient underwent coil embolization of the proximal aneurysm followed by microsurgical trap of the distal aneurysm and resection of the arteriovenous shunt lying superficially in the cerebellar hemisphere. The shunt was histologically verified as AVM. Staged approach with coil embolization and open microsurgery can be a treatment option for multiple PICA aneurysms associated with an AVM.

Keywords: Cerebellar arteriovenous malformation, meningeal blood supply, pedicle aneurysms, posterior inferior cerebellar artery

Introduction

Saccular and fusiform aneurysm are estimated to comprise 2.7%–9% of all intracranial aneurysms. Posterior inferior cerebellar artery (PICA) aneurysms arising in association with arteriovenous malformations (AVMs) are rare, and there is no defined treatment algorithm. Here, we present a unique case of ruptured multiple PICA aneurysms associated with a cerebellar AVM that caused subarachnoid hemorrhage (SAH) and treated by combined procedures with endovascular treatment followed by microsurgical aneurysm clipping and excision of AVM.

The present study was performed in accordance with our institution's guidelines for human research. Written informed consent was obtained from the patient before the treatment.

Case Report

A 67-year-old woman developed a severe headache. She was admitted our hospital with 21 points on NIHSS. Cranial computed tomography scans showed SAH predominantly distributing

in the left lateral pontine cistern and clot in the fourth ventricle [Figure 1a]. Cerebral angiography showed two saccular aneurysms peripherally on the left PICA, which formed an abnormal arteriovenous shunt adjacent to the left transverse sinus. The shunt was further fed by the ipsilateral superior cerebellar and contralateral posterior meningeal arteries. Neither stenotic nor obstructive changes were found in the sinus [Figure 1b and c]. The proximal aneurysm was larger and deep seated while the distal aneurysm was smaller and located superficially. Initial treatment aiming at an internal trap of the PICA between the two aneurysms failed for technical difficulty and resulted in embolization of the proximal aneurysm. On the following day, the patient underwent a microsurgical trap of the distal aneurysm and resection of the arteriovenous shunt. Intraoperatively, the inner dural surface showed convolutions with purplish discoloration adjacent to the transverse sinus. The distal aneurysm was buried in thick clots and presented as a premature rupture, which suggesting the source of bleeding. *En bloc* resection was achieved for the superficially located abnormal vessels, which was

**Senshu Nonaka,
Hidenori Oishi¹,
Satoshi Tsutsumi,
Hisato Ishii**

Department of Neurosurgery,
Juntendo University Urayasu
Hospital, ¹Department of
Neurosurgery, Juntendo
University School of Medicine,
Urayasu, Chiba 279-0021,
Japan

Address for correspondence:

Dr. Senshu Nonaka,
Department of Neurosurgery,
Juntendo University Urayasu
Hospital, 2-1-1 Tomioka,
Urayasu, Chiba 279-0021,
Japan.
E-mail: snonaka@juntendo.ac.jp

Access this article online

Website: www.asianjns.org

DOI: 10.4103/ajns.AJNS_180_17

Quick Response Code:



How to cite this article: Nonaka S, Oishi H, Tsutsumi S, Ishii H. Posterior fossa arteriovenous malformation with multiple pedicle aneurysms and recruitment of meningeal supply. *Asian J Neurosurg* 2018;13:1250-1.

This is an open access journal, and articles are distributed under the terms of the Creative Commons Attribution-NonCommercial-ShareAlike 4.0 License, which allows others to remix, tweak, and build upon the work non-commercially, as long as appropriate credit is given and the new creations are licensed under the identical terms.

For reprints contact: reprints@medknow.com

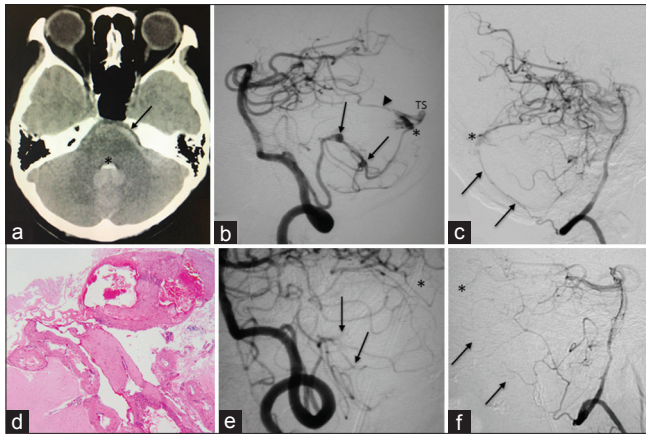


Figure 1: (a) CT scan showing subarachnoid hemorrhage (arrow) and intraventricular clot (asterisk). (b) A left vertebral arteriogram, oblique view, showing aneurysms on the distal PICA (arrows) fed by the superior cerebellar artery (arrowhead), forming arteriovenous shunt (asterisk), and draining into the transverse sinus (TS). (c) A right vertebral arteriogram, lateral view, showing the posterior meningeal artery (arrows) feeding the shunt (asterisk). (d) Photomicrograph of the resected shunt showing findings of arteriovenous malformation. H-E stain, x 200 (e and f) Left (e) and right (f) vertebral arteriograms, oblique view, showing disappearance of PICA aneurysms (arrows) and shunt (asterisk)

histologically verified as AVM [Figure 1d]. Postoperative angiography confirmed the disappearance of the abnormal vasculatures [Figure 1e and f]. Although there was no complication with the procedures, delayed ischemic neurological deficit appeared for the perioperative period, the patient was discharged with 15 points on NIHSS.

Discussion

A pedicle PICA aneurysm associated with an AVM is a rare occurrence with a few documented cases. Multiple pedicle aneurysms in association with an AVM are exceptionally rare.^[1-3] Although clip obliteration is the standard treatment of such aneurysms, endovascular therapy has been reported as an alternative option.^[1,4,5] In our case, as previously documented, catheterization into the peripheral PICA was technically difficult.^[5] Therefore, we performed staged treatment with coil embolization to the proximal aneurysm followed by microsurgical management to the superficially located distal aneurysm and AVM. Embolization using liquid material was thought to be a risk for migration into the transverse sinus. In the present case, cerebellar AVM was supplied by the posterior meningeal artery. This type of transdural feeding was found in 6.6% of intracranial AVMs,

not having an impact on the treatment outcome.^[6] The meningeal supply in this case was interrupted by a dural incision during surgery and no additional management was necessary. A staged approach with coil embolization and open microsurgery can be a treatment option for multiple PICA aneurysms associated with an AVM.

Conclusion

We underwent multiple PICA aneurysms associated with cerebellar AVM. These both lesions are extremely rare, and we treated the case with combined procedure of endovascular treatment and open surgery. We consider that the combined procedures of endovascular treatment and open surgery are suitable because of less invasive strategy than a single surgical procedure for the cerebellum in the acute phase.

Financial support and sponsorship

Nil.

Conflicts of interest

There are no conflicts of interest.

References

1. Case D, Kumpe D, Cava L, Neumann R, White A, Roark C, *et al.* Ruptured distal posterior inferior cerebellar artery (PICA) aneurysms associated with cerebellar arterial venous malformations (AVMs): A Case series and review of the literature demonstrating the need for angiographic evaluation and feasibility of endovascular treatment. *World Neurosurg* 2017;97:751.e7-13.
2. Higashi K, Hatano M, Yamashita T, Inoue S, Matsumura T. Coexistence of posterior inferior cerebellar artery aneurysm and arteriovenous malformation fed by the same artery. *Surg Neurol* 1979;12:405-8.
3. Kaptain GJ, Lanzino G, Do HM, Kassell NF. Posterior inferior cerebellar artery aneurysms associated with posterior fossa arteriovenous malformation: Report of five cases and literature review. *Surg Neurol* 1999;51:146-52.
4. Chen Z, Li L, Gong F, Wang W. Endovascular treatment of ruptured distal posterior inferior cerebellar artery aneurysms: Report of 11 cases. *Afr Health Sci* 2014;14:89-93.
5. Isokangas JM, Siniluoto T, Tikkaoski T, Kumpulainen T. Endovascular treatment of peripheral aneurysms of the posterior inferior cerebellar artery. *AJNR Am J Neuroradiol* 2008;29:1783-8.
6. Bervini D, Morgan MK, Stoodley MA, Heller GZ. Transdural arterial recruitment to brain arteriovenous malformation: Clinical and management implications in a prospective cohort series. *J Neurosurg* 2017;127:51-8.