

Lhermitte–Duclos Disease: A Rare Cause of Cerebellar Ataxia

Abstract

The aim of this study is to describe a case of Lhermitte–Duclos disease (LDD), which is an extremely rare cause of cerebellar ataxia. LDD is an extremely rare type of benign cerebellar mass and usually manifest as features of raised intracranial pressure and cerebellar dysfunction. Patients may remain asymptomatic for many years, and detection of tumor may be by chance on routine magnetic resonance imaging (MRI) and magnetic resonance spectroscopy (MRS). A 29-year-old female presented to the outdoor patient department with 18 months history of a headache, which was moderate to severe in intensity, throbbing in nature, localized to the right side of the head, and associated with nausea and photophobia. On examination, she had mild cerebellar dysfunction, and MRI/MRS finding was consistent with LDD. LDD is a rare cause of headache and cerebellar dysfunction in younger age group. Treatment may be individualized, and conservative management with regular follow-up may be a better approach if symptoms are mild and nonprogressive in nature.

Keywords: *Ataxia, cerebellum, magnetic resonance imaging*

Introduction

Lhermitte–Duclos disease (LDD) is an extremely rare type of benign cerebellar mass and usually manifest as features of raised intracranial pressure and cerebellar dysfunction. Patients may remain asymptomatic for many years and detection of tumor may be by chance on routine magnetic resonance imaging (MRI) and magnetic resonance spectroscopy (MRS). We report a young female patient who presented with headache, mild cerebellar dysfunction, and MRI/MRS finding was consistent with LDD.

Case Report

A 29-year-old female presented to the outdoor patient department with 18 months history of headache which was moderate to severe in intensity, throbbing in nature, localized to right side of the head, and associated with nausea and photophobia. It used to occur for a duration of 4–5 h at a frequency of 4–6 times/month initially which slowly increased and became continuous for 4 months. There was no history of phonophobia, nasal congestion, lacrimation, eye redness, fever, weight loss, or diplopia. On examination, the patient had a normal general physical examination. She was conscious and oriented. Her fundus and cranial nerves examination were normal. There were no motor and sensory deficits.

This is an open access article distributed under the terms of the Creative Commons Attribution-NonCommercial-ShareAlike 3.0 License, which allows others to remix, tweak, and build upon the work non-commercially, as long as the author is credited and the new creations are licensed under the identical terms.

For reprints contact: reprints@medknow.com

Cerebellar examination revealed impaired tandem gait [Video 1]. However, there was no associated nystagmus, and speech was also normal. Rest of the systemic examination was within normal limits. Routine blood investigations were within normal limits. On neuroimaging, MRI of brain revealed lesion in the right cerebellar hemisphere with preserved cortical striations that were hypointense on T1-weighted images (T1WI), hyperintense on T2WI and fluid attenuation inversion recovery (FLAIR) images [Figure 1]. On postgadolinium, T1WI there was no contrast enhancement [Figure 1b]. MRS of the lesion revealed a decreased level of N-acetylaspartate (NAA) and elevated lactate level [Figure 2]. A diagnosis of LDD was made, and a decision was made to follow-up the patient as she was not willing to undergo surgery immediately.

Discussion

LDD is a rare benign cerebellar lesion of unknown etiology which is characterized by enlargement of the cerebellar folia.^[1] It has features of both a malformation as well as a tumor.^[2] The disease was first described by Lhermitte and Duclos in 1920.^[3] With a prevalence of <1 in 1,000,000, this disease usually has an adult onset presentation. More often than not it is sporadic but has an autosomal dominant inheritance when associated with Cowden's disease. Being a part of phosphatase and tensin homolog (PTEN)

How to cite this article: Pandey S, Sarma N. Lhermitte–Duclos disease: A rare cause of cerebellar ataxia. *Asian J Neurosurg* 2017;12:705-6.

**Sanjay Pandey,
Neelav Sarma**

*Department of Neurology,
GB Pant Hospital, New Delhi,
India*

Address for correspondence:

*Dr Sanjay Pandey,
Room No. 507, Academic
Block, GB Pant Hospital,
New Delhi - 110 002, India.
E-mail: sanjaysgpgi2002@
yahoo.co.in*

Video Available on:
www.asianjns.org

Access this article online

Website: www.asianjns.org

DOI: 10.4103/ajns.AJNS_190_14

Quick Response Code:



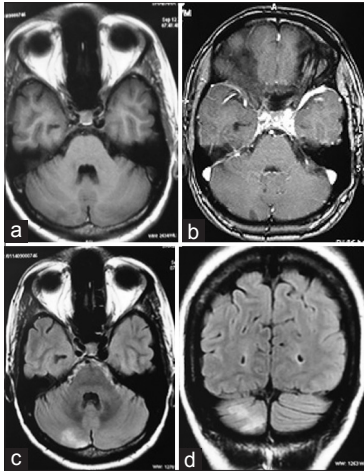


Figure 1: Magnetic resonance imaging of brain showing hypointense lesion in the right cerebellar hemisphere on T1-weighted images (a), which does not show postgadolinium enhancement (b), hyperintense on fluid-attenuated inversion recovery axial (c), and coronal (d) sequences

hamartoma tumor syndromes, the disease’s gene locus when associated with Cowden disease has been located at chromosome 10q 22–23 which codes for PTEN which is 403 amino acid phosphatase with antitumor effects.^[4] Histopathology of such lesions reveals the internal granular layer and molecular layer appear diffusely enlarged with dysplastic cells replacing the internal granular layer with hypermyelination of the molecular layer. The tissue stains positive for synaptophysin. Clinically, such patients present in the third or fourth decade of life with symptoms such as headache, nausea, and imbalance whose examination reveal features of ataxia, visual disturbances, and other cranial nerve palsies. Other abnormalities that can be present include microgyria, hydromyelia, megalencephaly, partial gigantism, polydactyly, and macroglossia.^[5] While confirmatory diagnosis is formed by histopathological findings, MRI/MRS provides good markers for diagnosing this particular condition. The lesions appear hypointense in T1WI and hyperintense on T2WI/FLAIR images. The lesions appear as widened cerebellar folia with preservation of striations. MRS images reveal elevated lactate while reductions in NAA and myoinositol.^[2] Contrast enhancement is not a typical feature and when present should suggest another diagnostic possibility such as hemangioblastoma.^[2,6] Fluorodeoxyglucose positron emission tomography shows an increase in uptake of these lesions.^[2] Definitive treatment for this condition involves surgery and removal of the lesion. However, asymptomatic patients diagnosed incidentally by MRI, conservative strategy can be justified.^[7,8] New studies have tried endoscopic ventriculocisternostomy for patients who present with hydrocephalus.^[9] Postoperative disease recurrence has been found to be rare.^[10]

Conclusion

LDD is a rare cause of headache and cerebellar dysfunction in younger age group. MRI and MRS findings are important in making a diagnosis. Treatment may be individualized depending on patient history and clinical examination.

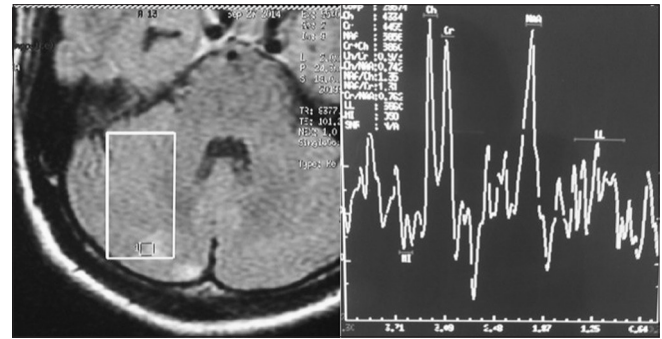


Figure 2: Magnetic resonance spectroscopy of the right cerebellar region showing decreased N-acetylaspartate and elevated lactate peak (lactate level)

Conservative management with regular follow-up may be a better approach if symptoms are mild and nonprogressive in nature.

Financial support and sponsorship

Nil.

Conflicts of interest

There are no conflicts of interest.

References

- Nowak DA, Trost HA, Porr A, Stölzle A, Lumenta CB. Brain MRI features in Lhermitte-Duclos disease. *Clin Neurol Neurosurg* 2001;103:105.
- Klisch J, Juengling F, Spreer J, Koch D, Thiel T, Büchert M, *et al.* Lhermitte-Duclos disease: Assessment with MR imaging, positron emission tomography, single-photon emission CT, and MR spectroscopy. *AJNR Am J Neuroradiol* 2001;22:824-30.
- L’hermitte J, Duclos P. On the diffuse ganglioneuroma of the cerebellar cortex. *Bull Assoc Fr Etud Cancer*. 1920;9:99-107.
- Marsh DJ, Coulon V, Lunetta KL, Rocca-Serra P, Dahia PL, Zheng Z, *et al.* Mutation spectrum and genotype-phenotype analyses in Cowden disease and Bannayan-Zonana syndrome, two hamartoma syndromes with germline PTEN mutation. *Hum Mol Genet* 1998;7:507-15.
- Nowak DA, Trost HA. Lhermitte-Duclos disease (dysplastic cerebellar gangliocytoma): A malformation, hamartoma or neoplasm? *Acta Neurol Scand* 2002;105:137-45.
- Nagaraja S, Powell T, Griffiths PD, Wilkinson ID. MR imaging and spectroscopy in Lhermitte-Duclos disease. *Neuroradiology* 2004;46:355-8.
- Capone Mori A, Hoeltzenbein M, Poetsch M, Schneider JF, Brandner S, Boltshauser E. Lhermitte-Duclos disease in 3 children: A clinical long-term observation. *Neuropediatrics* 2003;34:30-5.
- Marano SR, Johnson PC, Spetzler RF. Recurrent Lhermitte-Duclos disease in a child. Case report. *J Neurosurg* 1988;69:599-603.
- Sibille CA, Triffaux M, Claes K, Sznajder Y, Gille M. Lhermitte-Duclos disease with obstructive hydrocephalus: An illustrative case treated with endoscopic ventriculo-cisternostomy. *Rev Neurol (Paris)* 2013;169:917-9.
- Prabhu SS, Aldape KD, Bruner JM, Weinberg JS. Cowden disease with Lhermitte-Duclos disease: Case report. *Can J Neurol Sci* 2004;31:542-9.