

Outcome of Posttraumatic Delayed Intracerebral Tension Pneumatocoele: Prospective Study of Four Cases: Single Institutional Experience

Abstract

Aim: Delayed intracerebral tension pneumatocele (DITP) is an uncommon cause of raised intracranial pressure following trauma. However, it can cause herniation syndrome due to a sudden increase in intracranial pressure which requires emergent intervention. Pneumocephalus is a complication of head injury in 3.9%–9.7% of the cases. The accumulation of intracranial air can be acute (<72 h) or delayed (≥ 72 h). **Method:** When intracranial air causes intracranial hypertension and has a mass effect with neurological deterioration, it is called tension pneumocephalus. In our case series, we demonstrated four cases of DITP in adult patients from January 2012 to January 2017 in the Department of Neurosurgery at R. N. T. Medical College and M. B. Hospital, Udaipur, Rajasthan. **Result:** During this period, a total number of patients admitted of head injury are 1768 and hence, the incidence of DITP in our series is 0.226% which is very less as compared to previous literature. All patients are male; age ranging from 17 years to 55 years (mean age was 31.75 years). All patients have a history of head injury, and mode of injury had road traffic accidents. Glasgow Coma Score (GCS) at readmission were 12–13 (mean GCS 12.75). Duration of developed DITP 1 month to 2½ months (mean 1.375 months), all patients had gone to surgical intervention, and outcome assessed using Glasgow outcome score. All patients had a good outcome and average follow-up was 12.5 months. **Conclusion:** long term observation of patients with simple pneumocephalus following trauma is beneficial as there is an expected risk of developing delayed tension pneumocephalus which may manifest with raised intracranial pressure.

Keywords: Cerebrospinal fluid rhinorrhea, intracerebral, pneumocephalus, tension pneumatocele

Introduction

Pneumocephalus is usually defined as the presence of air in the intracranial cavity. The term pneumocephalus was first coined by wolf in 1914. It is usually associated with a basal skull fracture and dural tear after head and facial trauma. Clinically, it manifests as cerebrospinal fluid (CSF) rhinorrhea or otorrhea, whereas tension pneumatocele results from entrapment of intracranial air due to a check valve system following head injury. Tension pneumatocele at times behaves like an intracranial space occupying lesion and threatens life.

Methods

Four successive patients of delayed intracerebral, tension pneumatocele, shown in plain Computed Tomography (CT) head or magnetic resonance imaging (MRI) brain admitted from January 2012 to January 2017 in the Department of Neurosurgery

at R. N. T. Medical College and M. B. Hospital, Udaipur, Rajasthan, formed the prospective study group. A written informed consent was obtained from all the patients, as applicable. The diagnosis of Delayed intracerebral tension pneumatocele (DITP) was made on the basis of CT or MRI and Outcome assessed using Glasgow outcome score.

Results

During this period, a total number of patients admitted of head injury is 1768. All patients are male; age ranging from 17 years to 55 years (mean age 31.75 years). All patients have a history of head injury, and mode of injury had road traffic accidents (RTAs). Glasgow Coma Score (GCS) at readmission was 12–13 (mean GCS 12.75). Duration of developed DITP was 1–2½ months (mean 1.375 months). All patients went on surgical intervention [Table 1], and Outcome assessed by Glasgow outcome score

**Vivek Kumar Kankane,
Tarun Kumar Gupta**

*Department of Neurosurgery,
R. N. T. Medical College,
Udaipur, Rajasthan, India*

Address for correspondence:

*Dr. Vivek Kumar Kankane,
Department of Neurosurgery,
R. N. T. Medical College,
Udaipur, Rajasthan, India.
E-mail: vivekkankane9@gmail.com*

Access this article online

Website: www.asianjns.org

DOI: 10.4103/ajns.AJNS_226_17

Quick Response Code:



How to cite this article: Kankane VK, Gupta TK. Outcome of posttraumatic delayed intracerebral tension pneumatocele: Prospective study of four cases: Single institutional experience. Asian J Neurosurg 2018;13:1087-95.

This is an open access journal, and articles are distributed under the terms of the Creative Commons Attribution-NonCommercial-ShareAlike 4.0 License, which allows others to remix, tweak, and build upon the work non-commercially, as long as appropriate credit is given and the new creations are licensed under the identical terms.

For reprints contact: reprints@medknow.com

Table 1: Demographic data, management and outcome of patients

Age (year)	Sex	Duration developed to DITP	Mode of injury	GCS at the time of re-admission	Management	Outcome measure by GOS
25	Male	1 month	RTA	13/15	Surgery	Good
30	Male	1 month	RTA	12/15	Surgery	Good
17	Male	2 month	RTA	13/15	Surgery	Good
55	Male	1 and ½ month	RTA	13/15	Surgery	Good

DITP – Delayed intracerebral tension pneumatocele; GCS – Glasgow Coma Score; GOS – Glasgow Outcome Scale; RTA – Road traffic accident

Table 2: Glasgow outcome score

GOS score	Functional status
5	Resumption of normal life; there may be minor neurological and or psychological deficit
4	Able to work in a shattered environment and travel by public transportation
3	Dependent for daily support by reason of mental or physical disability or both
2	Unresponsive for weeks or months or until death
1	Death

GOS – Glasgow Outcome Scale

[Table 2]. All patients had a good outcome, and average follow-up was 12.5 months. We described all patients detailed in case descriptions (Case-1 to Case-4).

Case 1

A 25-year-old male was admitted to Neurosurgery ward with head injury. He had no loss of consciousness, vomiting, and seizure but bleeding from nose present. His GCS was 15/15, there were bilateral black eyes with per orbital swelling, and hence, his vision and pupil could not be assessed. Except anosmia no other cranial nerves, motor, and sensory deficit detected. A plain noncontrast computed tomography (NCCT) head revealed a fracture of Left frontal bone involving the sinus with depression of posterior wall of the sinus, underlying multiple contusions of the frontal lobe and no pneumocephalus [Figure 1a]. He was kept on antibiotic and anticonvulsant and strictly in the supine posture. He was made to sit up after 48 h and checked for CSF rhinorrhea, which was not present. He was discharged on the 10th day in a stable neurological condition. A month later, he was readmitted in an altered sensorium with repeated vomiting. He was drowsy, irritable, and confused, his GCS was 13/15, pupil right side was normal, left moderately dilated and sluggishly reacting to light, and no other deficit was detected. The patient had MRI from outside [Figure 1b] which revealed a large left frontal intraparenchymal tension pneumatocele causing a mass effect. He was operated in emergency. Left frontal craniotomy, evacuation of tensed air, duraplasty, and exteriorization of frontal sinus was done. Postoperatively, he becomes fully conscious, and there was no neurological deficit. After 48 h, a repeat CT head [Figure 1c] was done, which showed minimal left frontal pneumatocele with no mass effect. The patient was discharged on the 10th day

without any neurological deficit or CSF rhinorrhea. At his 6-month follow-up, he has no neurological deficit and no signs of rhinorrhea and meningitis.

Case 2

A 30-year-old male was admitted to Neurosurgery ward with head injury following RTA. He had no history of loss of consciousness, vomiting, ear bleed and seizures, but he had bleeding from nose. His GCS was 15/15. Pupils were 2 mm bilaterally and reacting to light. No any cranial nerves, motor, and sensory deficit detected. A plain computerized tomogram was done which revealed bilateral frontal contusion with fracture of bilateral frontal bone with involving the right frontal sinus with mild depression of posterior wall of sinus with patchy pneumocephalus [Figure 2a]. He kept on antibiotic, anticonvulsant and analgesics and patient was discharge 3rd of admission. At the time of discharge, patient was intact without focal neurological deficit and with no CSF rhinorrhea. A month later, he complained of severe frontal headache with CSF rhinorrhea and progressively deteriorating neurologically then readmitted in neurosurgery ward and on admission, his GCS dropped to 12, meningeal signs were found and he become bradypneic and repeat NCCT head revealed tension intraparenchymal pneumatocele on right frontal lobe with rounded or oval in configuration, measuring on an average 3–4 cm in diameter with mass effect and communicating with bilateral lateral ventricles, basal cisterns, and subarachnoid spaces [Figure 2b]. Under general anesthesia, right frontal craniotomy evacuation of tensed air, duraplasty was done shifted to the Neurosurgery ICU. Next day after the surgical treatment, he improved and became awake. The subdural drain was removed. A repeat NCCT head was done after 48 h which showed resorption of frontal pneumatocele with minimal subarachnoid and intraventricular air [Figure 2c]. CSF rhinorrhea stopped. In 10 days after surgery, the patient was discharged. At his 6-month follow-up, he has no neurological deficit and no signs of rhinorrhea and meningitis.

Case 3

A 17-year-old male was admitted with head injury following RTA. He had no loss of consciousness, vomiting, or seizure, but he had bleeding from nose. His GCS was 15/15. A plain CT head was done which revealed fracture of left frontal

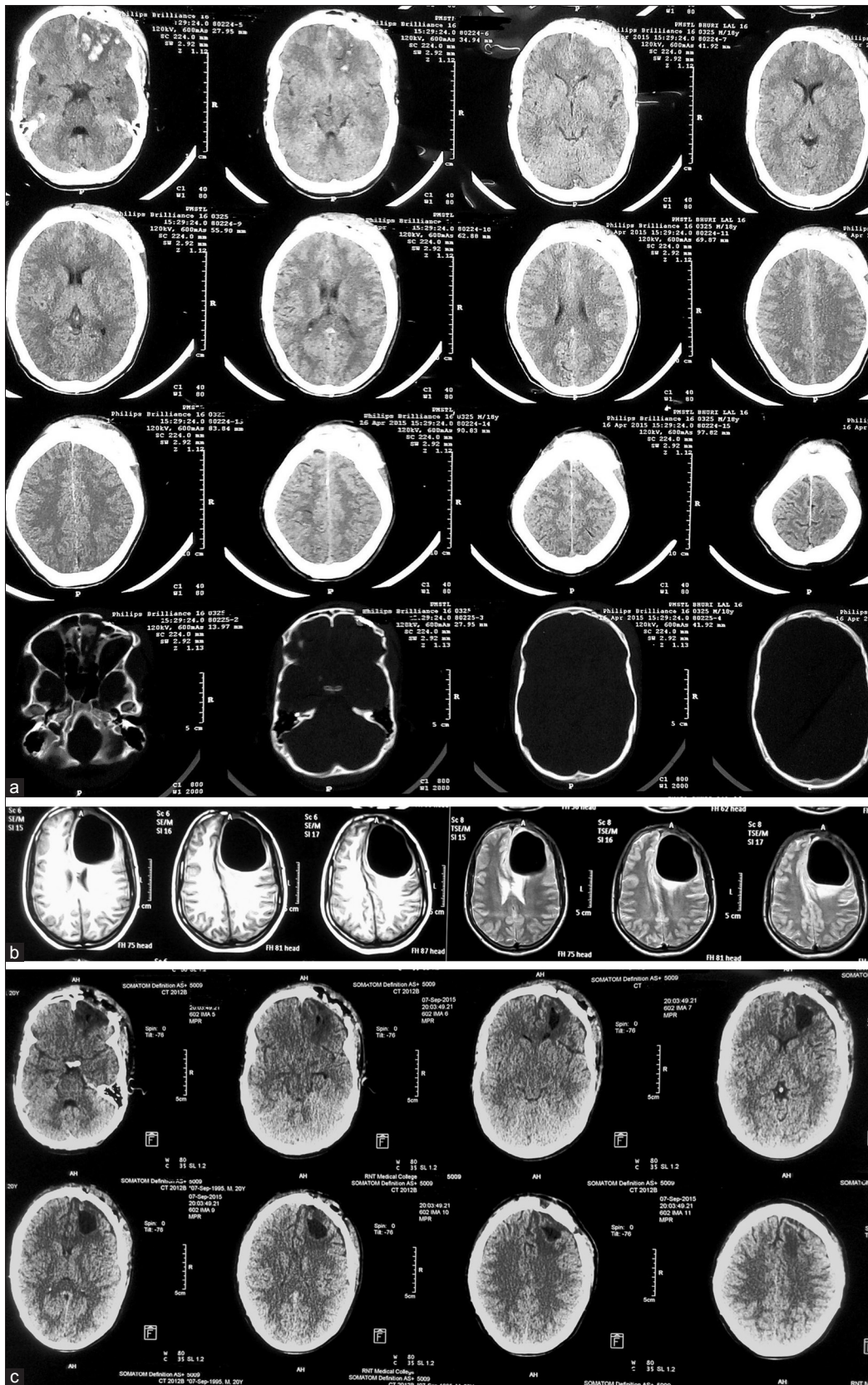


Figure 1: (a) Noncontrast computed tomography Head revealed fracture of Left frontal bone involving the sinus with depression of posterior wall of the sinus, underlying multiple contusions of frontal lobe and no pneumocephalus. (b) Magnetic resonance imaging T2 W image revealed a large Left frontal intraparenchymal tension pneumatocele causing mass effect. (c) noncontrast computed tomography Head revealed minimal Left Frontal pneumatocele with no mass effect

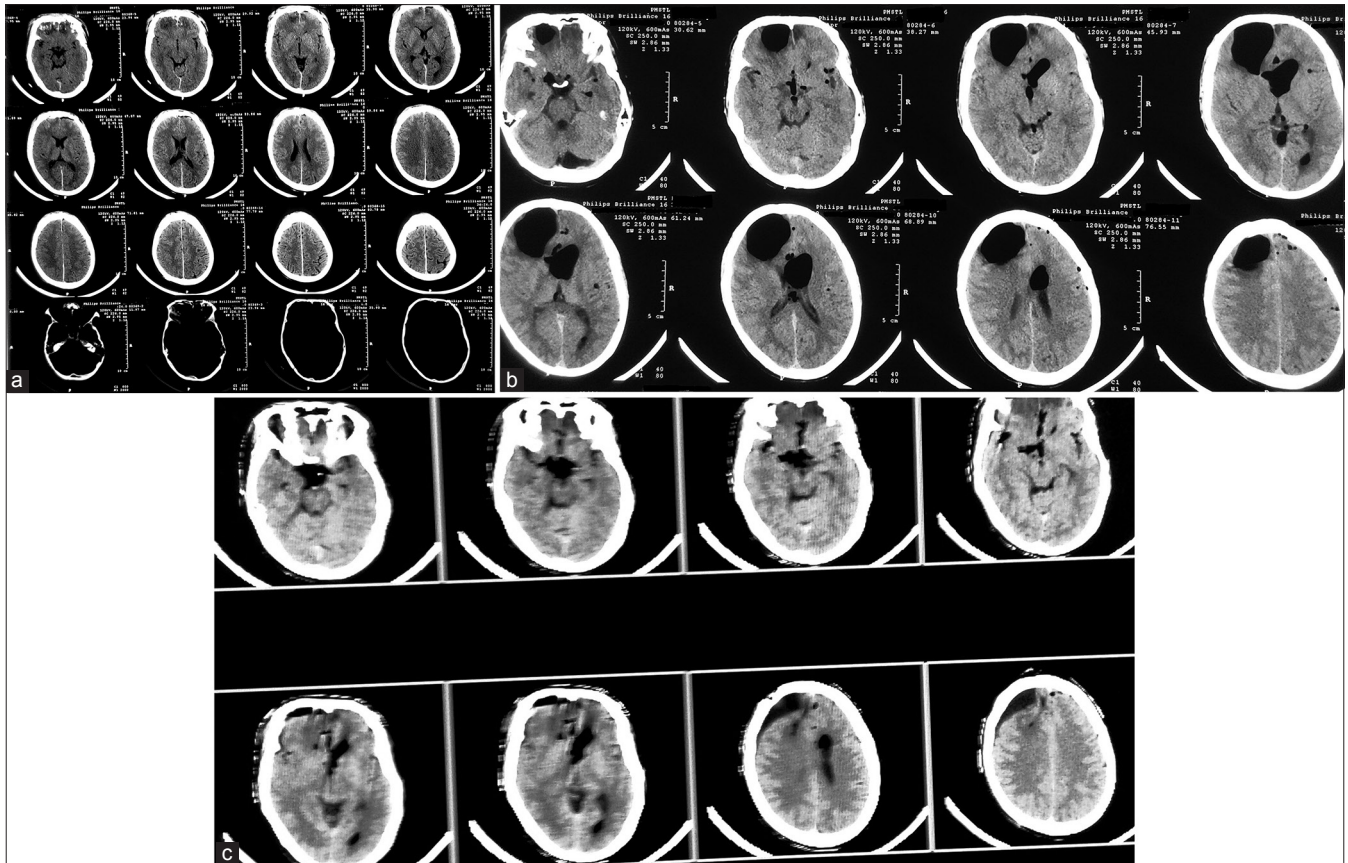


Figure 2: (a) A noncontrast computed tomography Head revealed bilateral frontal contusion with fracture of bilateral frontal bone with involving the right frontal sinus with mild depression of posterior wall of sinus with Mild pneumocephalus. (b) Repeat noncontrast computed tomography Head revealed tension intraparenchymal pneumatocele on right frontal lobe with mass effect and communicating with bilateral lateral ventricles, basal cisterns and subarachnoid spaces. (c) On postoperative noncontrast computed tomography scans revealed resorption of frontal pneumatocele with minimal subarachnoid and intraventricular air; there was a minimal residual Pneumocephalus

bone involving the sinus with mild depression of posterior wall of the sinus, underlying tiny contusions of left frontal lobe and bilateral pneumocephalus in baso-frontal convexity extending to interhemispheric fissure which was not significant and no mass effect [Figure 3a].

The patient kept on antibiotic, anticonvulsant, and strictly in the supine posture. He was prepared to sit up after 48 h and checked for CSF rhinorrhea, which was not present even after 72 h. He was discharged on the 7th day in a stable neurological condition. A 2 month later, he was readmitted in an altered sensorium with repeated vomiting. On examination, his vital signs were stable, he was drowsy, irritable, and confused, his GCS was 13/15, and pupils were bilateral normal. Urgent NCCT head was done [Figure 3b] which revealed a large Left frontal intraparenchymal tension pneumatocele causing a mass effect. He was operated in emergency. Left frontal craniotomy, evacuation of tensed air, duraplasty and exteriorization of frontal sinus was done. Postoperatively, he becomes fully conscious, and there was no neurological deficit. A repeat CT head [Figure 3c] was done after 48 h, which showed minimal Left Frontal pneumatocele with no mass effect. The patient was discharged on the 10th day

without any neurological deficit or CSF rhinorrhea. At his 6- month follow-up, he has no neurological deficit and no signs of rhinorrhea and meningitis.

Case 4

A 55-year-old male was admitted with Head injury. He had no loss of consciousness, vomiting, and seizure but he had bleeding from the nose. His GCS was 15/15. A plain CT head was done which revealed a fracture of left frontal bone involving the sinus, underlying tiny contusions of the bilateral frontal lobe and bilateral pneumocephalus in baso-frontal convexity extending to interhemispheric fissure which was not significant and no mass effect [Figure 4a].

The patient kept on antibiotic, anticonvulsant and strictly in the supine posture. He was discharged on the 5th day in a stable neurological condition. A 1½ month later, he was readmitted in an altered sensorium with repeated vomiting. He was drowsy, irritable, and confused, his GCS was 13/15, pupils were bilateral normal. The patient had come with MRI [Figure 4b] which revealed a large Left frontal intraparenchymal tension pneumatocele with air-fluid level causing a mass effect. He was operated in emergency. Left frontal craniotomy, evacuation of tensed air, duraplasty and

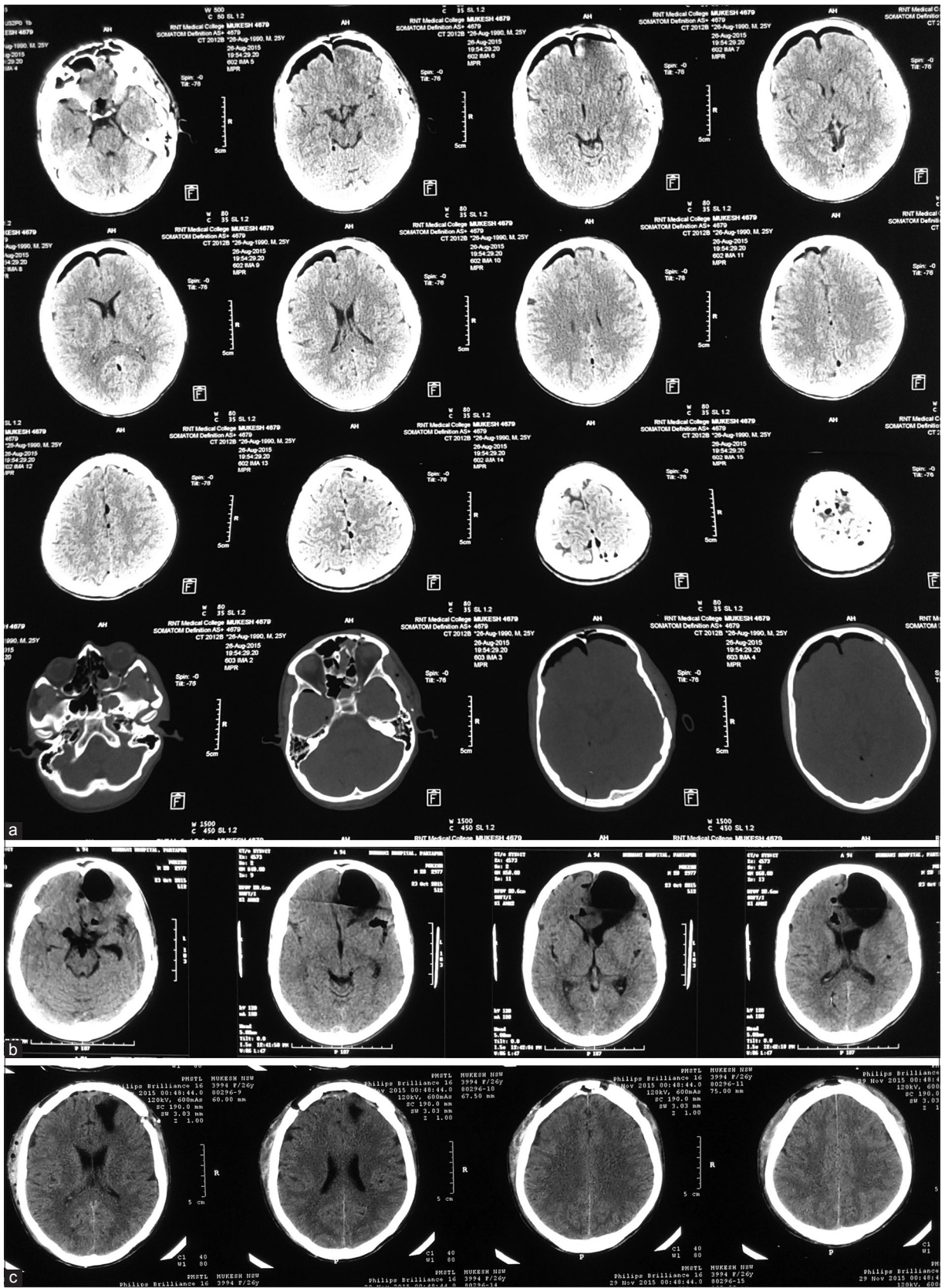


Figure 3: (a) Fracture of Left frontal bone involving the sinus with mild depression of posterior wall of the sinus, underlying tiny contusions of left frontal lobe and Bilateral pneumocephalus in baso-frontal convexity extending to interhemispheric fissure which was not significant and no mass effect. (b) Large Left frontal intraparenchymal tension pneumatocele causing mass effect. (c) Minimal Left Frontal pneumatocele with no mass effect

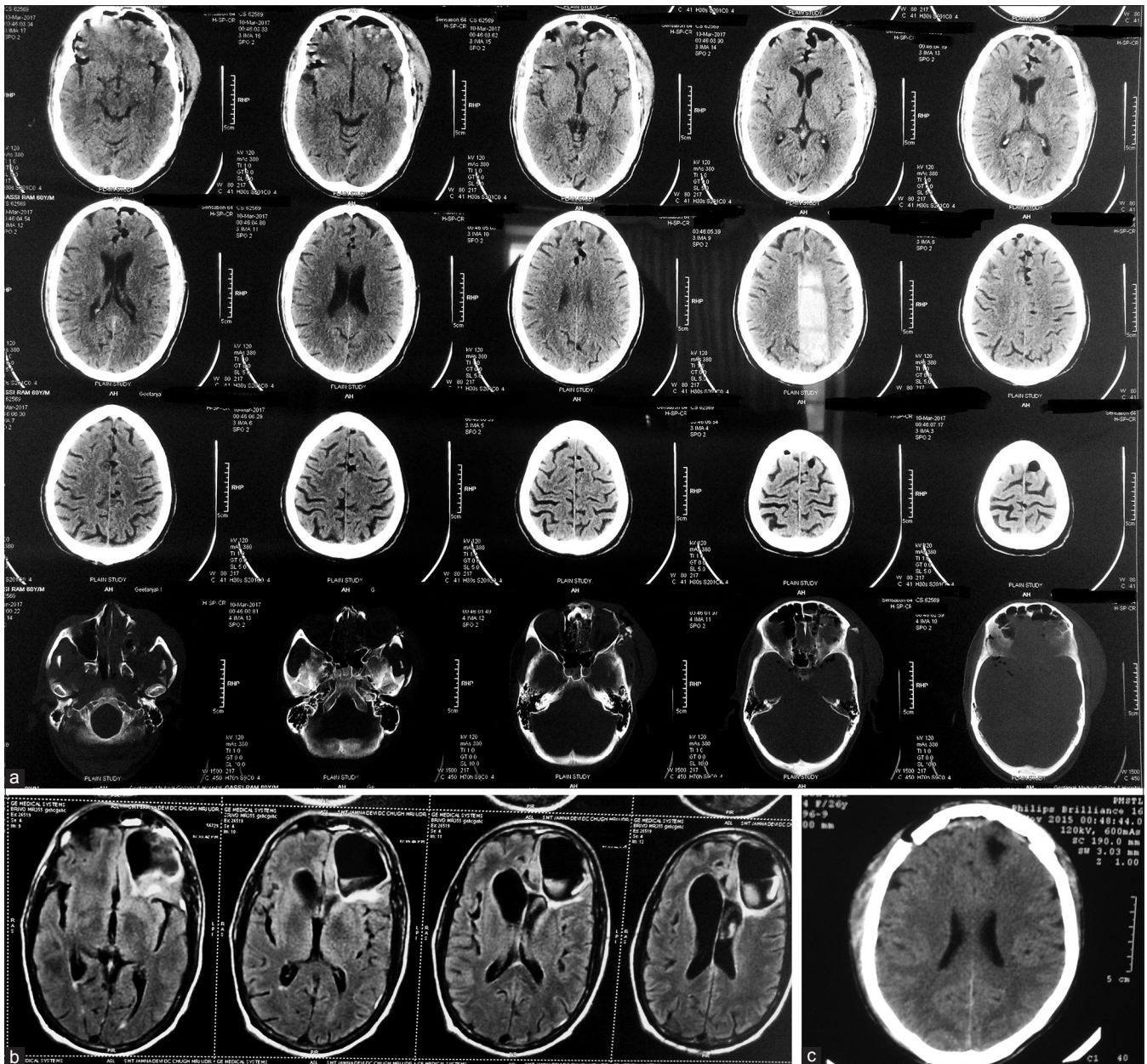


Figure 4: (a) Fracture of Left frontal bone involving the sinus, underlying tiny contusions of bilateral frontal lobe and bilateral pneumocephalus in baso-frontal convexity extending to interhemispheric fissure which was not significant and no mass effect. (b) Magnetic resonance imaging fluid-attenuated inversion recovery image revealed large left frontal intraparenchymal tension pneumatocele causing mass effect. (c) Minimal left frontal pneumatocele with no mass effect

exteriorization of frontal sinus was done. Postoperatively, he becomes fully conscious, and there was no neurological deficit. A repeat CT head [Figure 4c] was done after 48 h, which showed minimal left frontal pneumatocele with no mass effect. The patient was discharged on the 10th day without any neurological deficit or CSF rhinorrhea. At his 6 months follow-up, he has no neurological deficit and no signs of rhinorrhea and meningitis.

Discussion

Pneumocephalus, also known as intracranial aereocoele or pneumatocele is defined as the presence of gas within

any of the intracranial compartments (epidural, subdural, subarachnoid, intraventricular, and intraparenchymal).^[1] The pathophysiology of pneumocephalus usually involves one of the following mechanisms:

- (1) Ball valve mechanism in which there are a cranial defect and dural tear adjacent to a point where the air is available, i.e., paranasal sinus; air may be forced intracranially by coughing, sneezing, or blowing, etc., The dural opening is sealed due to tamponade effect on pia-arachnoid by the swollen brain, trapping the air intracranially (pneumocephalus). Repeated coughing and sneezing resulting in raised air pressure lead to larger accumulation

of air in the subdural or within the brain itself giving rise to marked mass effect (tension pneumocephalus)

- (2) Inverted bottleneck mechanism in which air enters as fluid leaves the intracranial space.^[2,3]

Intracranial pneumocephalus was first described in an autopsy report of a trauma patient in 1866.^[4] Some years later, Chiari reported a similar finding in an autopsy of a patient with chronic ethmoid sinusitis.^[5] The usefulness of X-ray in diagnosing intracranial air was demonstrated by Luckett in 1913. Pneumocephalus is a complication of head injury in 3.9-9.7% cases but in our series it was 0.226%, which is very less compare to previous literature.^[6,7] Pneumocephalus is a complication of head injury in 3.9%–9.7% of cases, but in our series, it was 0.226%, which is very less as compared to previous literature.^[7] It also appears after supratentorial craniotomy in 100% of cases.^[8] The accumulation of intracranial air can be acute (<72 h) or delayed (≥72 h).^[9] As a rule, intracranial collection of air is benign and asymptomatic. When intracranial air causes intracranial hypertension and has a mass-effect with neurological deterioration, it is called tension pneumocephalus. In the literature, 25 cases of tension pneumocephalus were described, 14 of them needed urgent surgery [Table 3]. In our article, we describe four cases of delayed tension pneumocephalus

who underwent urgent surgical treatment. All patients are male; age ranging from 17 years to 55 years (mean age 31.75 years). All patients have history of head injury and mode of injury had RTAs. GCS at readmission were 12–13 (mean GCS 12.75). Duration of developed DITP was 1 month to 2 ½ months (mean 1.375 months).

In tension pneumocephalus, air most frequently occupies the subdural area. However, air can also occupy the epidural, subarachnoid, intraparenchymal, and intraventricular areas.^[2,3,7,10] Gönül *et al.* presented a case of tension pneumocephaly due to head trauma where they performed emergency Decompressive surgery due to shift of intracranial midline structures. They noted that their case was interesting due to intraventricular tension pneumocephalus.^[10] Ram *et al.* presented a case of tension pneumocephaly in the posterior fossa region with CSF leakage at the suture line developing at the tenth day of posterior fossa operation.^[11] In our case series, initial pneumocephalus following trauma almost resolved, and a tension pneumatocele developed almost a month after trauma. Gore *et al.* mentioned the use of normobaric oxygen in high flow as a treatment protocol for simple pneumocephalus which enhanced the rate of absorption of pneumocephalus.^[12]

Browning *et al.* pointed out that intracranial air is frequently present after craniotomy, but it is normally absorbed in

Table 3: Description of previous reported case of tension pneumocephalus

Author	Year	Number of case	Age (year)/sex of patient	Description of patient	Management	Outcome
Satpathy and Dash	2000	1	10/male	Tension pneumocephalus developed in postoperative period after decompression of craniopharyngioma in supine position	Surgery	Good
Pillai <i>et al.</i>	2001	2	8/male 20/male	Traumatic tension pneumocephalus Traumatic tension pneumocephalus	Conservative Surgery	Good Good
Kon <i>et al.</i>	2003	1	46/male	Delayed tension pneumocephalus after 7 years of craniotomy	Surgery	Good
Sankhla <i>et al.</i>	2004	1	19/male	Delayed tension pneumocephalus after 6 month of shunt surgery	Surgery	Good
Kuncz <i>et al.</i>	2004	1	8/female	Traumatic prepontine tension pneumocephalus	Surgery	Good
Cho <i>et al.</i>	2004	2	Adult	Tension pneumocephalus which was developed after trans-sphenoid surgery for pituitary adenoma and craniopharyngioma	Surgery	Good
Hong <i>et al.</i>	2005	2	64/male 38/female	Delayed tension pneumocephalus developed after VP shunt Delayed tension pneumocephalus developed after 12 years of trauma	Surgery Surgery	Good Good
Chandran <i>et al.</i>	2007	1	18/male	Delayed spontaneous tension pneumocephalus	Surgery	Good
Leong <i>et al.</i>	2008	2	42/male 71/male	Traumatic delayed tension pneumocephalus Traumatic early tension pneumocephalus	Conservative Conservative	Good Good
Lee <i>et al.</i>	2009	1	45/male	Delayed tension pneumocephalus caused by spinal tapping in a patient with basal skull fracture and pneumothorax	Surgery	Good
Shaikh <i>et al.</i>	2010	1	70/male	Tension pneumocephalus after drainage of chronic subdural hematoma	Surgery	Good
Prüss <i>et al.</i>	2011	1	58/male	Tension pneumocephalus with diplegia after ethmoid sinus surgery	Surgery	Good
Kankane <i>et al.</i>	2016	1	30/male	Traumatic delayed tension pneumocephalus	Surgery	Good

VP – Ventriculo-peritoneal

3–4 weeks. The presence of pneumocephalus on a delayed postoperative CT scan should raise the possibility of CSF fistula, or infection with the gas forming organism. Many CSF fistulae require surgical closure to prevent potentially life-threatening central nervous system infections and tension pneumocephalus.^[13]

Pneumocephalus can be caused by trauma (basal skull fractures, paranasal sinuses fractures, open cranial convexity fractures with dural laceration^[14]), Neurosurgical operations (twist-drill evacuation of chronic subdural hematomas,^[15] ventriculo-peritoneal shunting,^[16] posterior fossa surgery in sitting^[17] or lateral position,^[18] intracranial pressure (ICP) monitoring,^[19] transsphenoidal or endoscopic sinus surgery, ENT operations (paranasal sinuses surgery; nasal septum resection; nasal polypectomy), lumbar punctures,^[20] barotraumas, tumors, CNS infections caused by gas-producing microorganisms, nitrous oxide, congenital skull and tegmen tympani defects, spinal anesthesia, positive pressure ventilation, hyperbaric oxygen therapy, spontaneous, scuba diving.

Clinical presentation of tension pneumocephalus may include a headache, generalized seizures, agitation, delirium, reflex abnormalities, and otherwise, altered level of consciousness, pupillary changes, and frontal lobe syndrome. Tension pneumocephalus localized in the posterior cranial fossa can cause clinical signs of brainstem dislocation,^[21] including breathing rhythm changes and cardiac arrest. Some rare neurological symptoms of tension pneumocephalus were reported, such as marked weakness of both legs^[22] and transient hemiplegia.^[23]

Computed tomography (CT) is a golden standard for tension pneumocephalus diagnostics. A bilateral subdural hypoattenuation (Hounsfield coefficient– 1000) collections, causing compression and separation of frontal lobes (widened interhemispheric fissure), with separated frontal lobes tips on CT scans were described as “Mount Fuji sign” by Ishiwata *et al.* as a pathognomonic sign of tension pneumocephalus.^[24,25] But in our cases, an intraparenchymal air-filled round cavity is seen in the frontal lobe (tension frontal pneumatocele) pneumocephalus also seen in subdural, basal cisterns, and communicating with the frontal horn of bilateral lateral ventricle with a fracture of right frontal and ethmoid sinus.

Tension pneumocephalus treatment includes a complex of manipulations directed to removing of intracranial air mass effect, adequate skull base defects closure, and secondary posttraumatic meningitis prophylaxis. Initial treatment is usually conservative, including bed rest in an upright position, high concentration oxygen, avoidance of maneuvers that might increase intrasinus pressure (such as nose-blowing or Valsalva maneuver) and antibiotics if there is evidence of meningism. Surgical treatment is indicated when there is recurrent pneumocephalus or signs of increasing ICP suggesting the development of tension

pneumocephalus.^[26,27] Surgical options include direct insertion of a subdural drain connected to underwater seal or, indirectly, with the use of a saline-primed Camino bolt.^[28]

Conclusion

Long-term observation of patients with simple pneumocephalus following trauma is beneficial as there is an expected risk of developing delayed tension pneumocephalus which may manifest with raised intracranial pressure. Emergency intervention in these situations can be life-saving. Even minor air collection in the cranial cavity has a risk of transformation into tension pneumocephalus in case of valve mechanism development; these patients should be subject to long-term follow-up after discharge from the hospital.

Financial support and sponsorship

Nil.

Conflicts of interest

There are no conflicts of interest.

References

1. Markham JW. The clinical features of pneumocephalus based upon a survey of 284 cases with report of 11 additional cases. *Acta Neurochir (Wien)* 1967;16:1-78.
2. Nazir SS, Wani MA, Kirmani AR. Post-traumatic subdural with intraventricular pneumatocele: A case report and review of literature. *JK Pract* 2004;11:50-3.
3. Huang CF, Chou TY, Chang CK. Traumatic tension pneumocephalus – Intracerebral pneumatocele: A case report. *Gaoxiong Yi Xue Ke Xue Za Zhi* 1992;8:113-6.
4. Schirmer CM, Heilman CB, Bhardwaj A. Pneumocephalus: Case illustrations and review. *Neurocrit Care* 2010;13:152-8.
5. Oge K, Akpınar G, Bertan V. Traumatic subdural pneumocephalus causing rise in intracranial pressure in the early phase of head trauma: Report of two cases. *Acta Neurochir (Wien)* 1998;140:655-8.
6. Hong WJ, Yoo CJ, Park CW, Lee SG. Two cases of delayed tension pneumocephalus. *J Korean Neurosurg Soc* 2005;37:59-62.
7. Kon T, Hondo H, Kohno M, Kasahara K. Severe tension pneumocephalus caused by opening of the frontal sinus by head injury 7 years after initial craniotomy – Case report. *Neurol Med Chir (Tokyo)* 2003;43:242-5.
8. Satapathy GC, Dash HH. Tension pneumocephalus after neurosurgery in the supine position. *Br J Anaesth* 2000;84:115-7.
9. Pillai P, Sharma R, MacKenzie L, Reilly EF, Beery PR 2nd, Papadimos TJ, *et al.* Traumatic tension pneumocephalus – Two cases and comprehensive review of literature. *Int J Crit Illn Inj Sci* 2017;7:58-64.
10. Gönül E, Izci Y, Sali A, Baysefer A, Timurkaynak E. Subdural and intraventricular traumatic tension pneumocephalus: Case report. *Minim Invasive Neurosurg* 2000;43:98-101.
11. Ram Z, Knoller N, Findler G, Sahar A. Delayed intraventricular tension pneumocephalus complicating posterior fossa surgery for cerebellar medulloblastoma. *Childs Nerv Syst* 1992;8:351-3.
12. Gore PA, Maan H, Chang S, Pitt AM, Spetzler RF, Nakaji P, *et al.* Normobaric oxygen therapy strategies in the treatment of

- postcraniotomy pneumocephalus. *J Neurosurg* 2008;108:926-9.
13. Browning CJ, Harland SP, Burnet NG. Gas in the cranium: An unusual case of delayed pneumocephalus following craniotomy. *Clin Oncol (R Coll Radiol)* 2000;12:118-20.
 14. Vikram A, Deb AK. Tension pneumocephalus secondary to a dural tear. *Appl Radiol* 2011;40:37-8.
 15. Shaikh N, Masood I, Hanssens Y, Louon A, Hafiz A. Tension pneumocephalus as complication of burr-hole drainage of chronic subdural hematoma: A case report. *Surg Neurol Int* 2010;1. pii: 27.
 16. Sankhla S, Khan GM, Khan MA. Delayed tension pneumocephalus: A rare complication of shunt surgery. *Neurol India* 2004;52:401-2.
 17. Pandit UA, Mudge BJ, Keller TS, Samra SK, Kilaru P, Pandit SK, *et al.* Pneumocephalus after posterior fossa exploration in the sitting position. *Anaesthesia* 1982;37:996-1001.
 18. Nayak PK, Mahapatra AK. Tension pneumocephalus in lateral position following posterior fossa surgery. *Pan Arab J Neurosurg* 2011;15:76-8.
 19. Vitali AM, le Roux AA. Tension pneumocephalus as a complication of intracranial pressure monitoring: A case report. *Indian J Neurotrauma* 2007;4:115-8.
 20. Lee SH, Koh JS, Bang JS, Kim MC. Extensive tension pneumocephalus caused by spinal tapping in a patient with basal skull fracture and pneumothorax. *J Korean Neurosurg Soc* 2009;45:318-21.
 21. Kuncz A, Roos A, Lujber L, Haas D, Al Refai M. Traumatic prepontine tension pneumocephalus – Case report. *Ideggyogy Sz* 2004;57:313-5.
 22. Prüss H, Klingebiel R, Endres M. Tension pneumocephalus with diplegia and deterioration of consciousness. *Case Rep Neurol* 2011;3:48-9.
 23. Chandran TH, Prepageran N, Philip R, Gopala K, Zubaidi AL, Jalaludin MA, *et al.* Delayed spontaneous traumatic pneumocephalus. *Med J Malaysia* 2007;62:411-2.
 24. Michel SJ. The Mount Fuji sign. *Radiology* 2004;232:449-50.
 25. Thapa A, Agrawal D. Mount Fuji sign in tension pneumocephalus. *Indian J Neurotrauma* 2009;6:161-2.
 26. Cho HL, Han YM, Hong YK. Tension pneumocephalus after transsphenoidal surgery: Report of two cases. *J Korean Neurosurg Soc* 2004;35:536-8.
 27. Kankane VK, Gupta TK, Jaiswal G. Traumatic bilateral basal ganglia bleed: A report of rare two cases and review of the literature. *Asian J Neurosurg* 2016;11:457.
 28. Leong KM, Vijayanathan A, Sia SF, Waran V. Pneumocephalus: An uncommon finding in trauma. *Med J Malaysia* 2008;63:256-8.