

## Adverse Event with the Use of Carmustine Wafers and Postoperative Radiochemotherapy for the Treatment of High-grade Glioma

### Abstract

Randomized, controlled trials have shown significant improvement of survival after implantation of 1,3-bis(2-Chloroethyl)-1-nitrosourea (BCNU) wafers for patients suffering from high-grade glioma. A combination of local chemotherapy with BCNU and concomitant radiochemotherapy with temozolomide (TMZ) appears to be attractive to enhance the overall survival, even though these treatments may potentially cumulate their toxicity. We report a clinical case of a patient submitted to this combined treatment protocol. Severe brain edema and a cystic formation in the surgical cavity rapidly developed. Data supporting the use of Gliadel® combined with TMZ comes from small retrospective studies, and some series have shown a very high rate of adverse events (AEs) when this multimodality treatment is applied. Combined protocols of local and systemic chemotherapy might provide survival benefits, although AEs seem currently underestimated.

**Keywords:** Adverse events, carmustine wafers, Gliadel, high-grade glioma

### Introduction

High-grade gliomas (HGGs) are the most common primary tumors of the central nervous system. The current standard of care for HGG includes surgical removal, if possible, followed by radiotherapy and systemic chemotherapy with temozolomide (TMZ). Chemotherapy with alkylating agents such as TMZ has significantly increased overall survival (OS) and progression-free survival compared to radiotherapy alone. However, OS at 2 years is still low: 27.2%, as demonstrated by the EORTC 26981 final results.<sup>[9]</sup>

1,3-bis(2-Chloroethyl)-1-nitrosourea (BCNU or carmustine) wafer implantation directly into the resection cavity followed by radiation therapy has also shown to significantly improve survival in patients with newly diagnosed malignant glioma, and this survival benefit was maintained over the long term.<sup>[1-5,10]</sup>

The idea of applying local chemotherapy in the surgical cavity would have several theoretical benefits. For instance, adjuvant treatment starts immediately after surgery, and there is no need to wait 2 or 3 weeks as with conventional radiochemotherapy.

In addition, the chemotherapeutic agent is applied directly within the brain, skipping the blood-brain barrier and reaching high parenchymal concentrations with potentially fewer systemic adverse reactions.

A combination of local BCNU wafer treatment and concomitant radiochemotherapy with TMZ appears attractive not only because it merges successful treatment strategies for malignant gliomas but also it may take advantage of a sensitizing effect of TMZ and carmustine on their respective resistance genes MGMT and AGT.<sup>[6]</sup>

Our neurosurgical department has chosen this multimodal treatment whenever total resection of the tumor is possible. Nevertheless, only a few data have become available concerning safety and efficiency of such treatment.

### Case Report

A 55-year-old male patient presented to the hospital due to progressive motor weakness of the left limbs and persistent headache. Magnetic resonance imaging (MRI) of the brain showed a probable HGG infiltrating the superior right frontal gyrus [Figure 1].

**Federico Salle<sup>1,2,3</sup>,  
Wissem Lahiani<sup>1</sup>,  
Edgardo  
Spagnuolo<sup>3</sup>,  
Stéphane Palfi<sup>1,2</sup>**

<sup>1</sup>Department of Neurosurgery, Assistance Publique-Hôpitaux de Paris, Groupe Hospitalier Henri-Mondor Albert-Chenevier, PePsy Department, <sup>2</sup>U955 INSERM IMRB eq. 14 Université Paris 12 UPEC, Faculté de Médecine, F-94010 Créteil, France, <sup>3</sup>Department of Neurosurgery, Hospital Maciel-ASSE, Montevideo, Uruguay

**Address for correspondence:**  
Dr. Federico Salle,  
Pedro Bustamante 1453, CP  
11600, Montevideo, Uruguay.  
E-mail: federico.salle@gmail.com

#### Access this article online

Website: [www.asianjns.org](http://www.asianjns.org)

DOI: 10.4103/ajns.AJNS\_235\_16

#### Quick Response Code:



**How to cite this article:** Salle F, Lahiani W, Spagnuolo E, Palfi S. Adverse event with the use of carmustine wafers and postoperative radiochemotherapy for the treatment of high-grade glioma. *Asian J Neurosurg* 2018;13:1171-4.

This is an open access journal, and articles are distributed under the terms of the Creative Commons Attribution-NonCommercial-ShareAlike 4.0 License, which allows others to remix, tweak, and build upon the work non-commercially, as long as appropriate credit is given and the new creations are licensed under the identical terms.

For reprints contact: [reprints@medknow.com](mailto:reprints@medknow.com)

The patient was programmed for elective surgery. Total resection of the lesion was performed by the authors (FS, WL) without any incidents. Preliminary histopathological examination confirmed the diagnosis of malignant glioma, and 8 wafers of Gliadel® were placed in the surgical cavity. Postoperative computed tomography (CT) scan showed no complications. He recovered from his motor deficit keeping a mild left hemiparesis that did not interfere with basic activities of daily living. He was discharged from hospital 1 week after surgery [Figure 2].

Three weeks after surgery, he started chemoradiation at standard doses for the Stupp protocol. Seven days on beginning this treatment, he had to be readmitted because of worsening of his motor deficit. Monoplegia of the upper left limb and cephalalgia were the main findings. Control MRI revealed extensive brain edema involving practically an entire hemisphere and formation of a cyst with mass effect within the surgical cavity. High doses of corticosteroids were administered, which helped managing the headaches, but the motor deficit was unresponsive to medical treatment. He remained hospitalized for several weeks, although he never recovered strength of his left upper limb. He is now still alive at 13 months of follow-up [Figure 3].

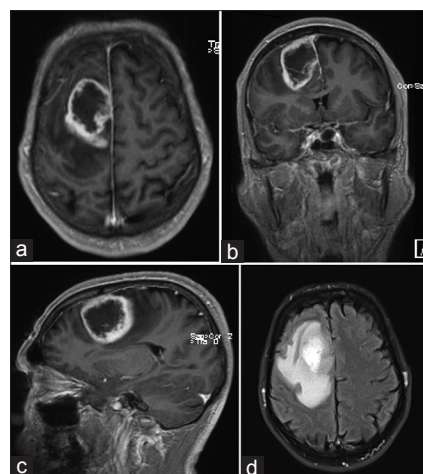
## Discussion

Standard treatment for HGG usually entails surgery (either biopsy or resection) followed by radiotherapy with or without TMZ. Implanting wafers impregnated with chemotherapy agents into the resection cavity represents an additional way of delivering drugs directly to the resection cavity with potentially fewer systemic side effects.<sup>[11]</sup>

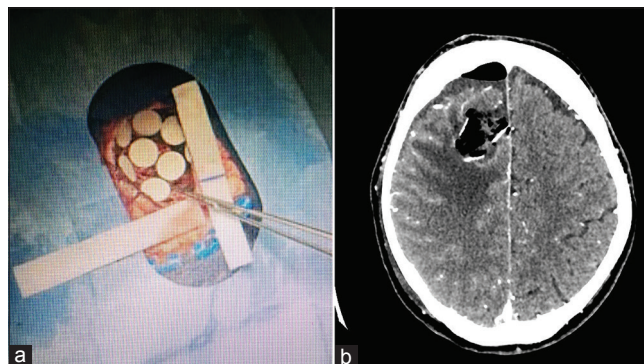
Many trials have been conducted to determine the safety and efficacy of Gliadel®, or whether it should be recommended as part of standard care for patients with HGG.

Westphal *et al.*, in 2003, published a phase three trial that randomized 240 patients to receive either Gliadel® + radiotherapy or placebo + radiotherapy. They demonstrated a reduction of 29% in the risk of death for the Gliadel® group, and an increase in median survival. The rate of adverse events (AEs) was comparable except for cerebrospinal fluid (CSF) leaks (5% with Gliadel® vs. 0.8% with placebo) and incidence of intracranial hypertension (9.1% Gliadel® vs. 1.7% placebo).<sup>[2]</sup>

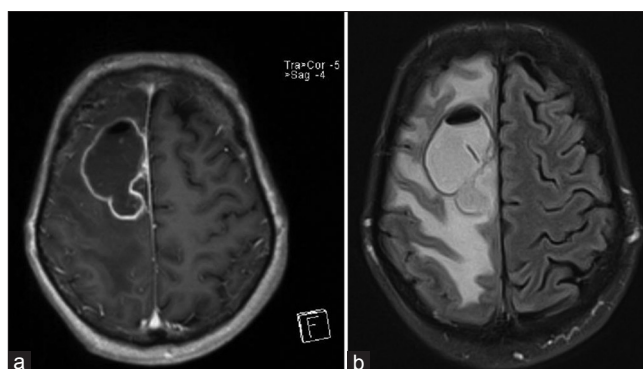
A meta-analysis combining the results of the trial published by Westphal and an earlier randomized phase three study by Valtonen *et al.* demonstrated that, specifically for the subgroup of glioblastoma, treatment with BCNU wafers resulted in a survival increase to 13.1 months versus 10.9 months for placebo patients ( $P = 0.03$ ).<sup>[6]</sup> Representing Class II evidence, the results of the two trials led to the Food and Drug Administration approval of Gliadel® in the



**Figure 1: Preoperative magnetic resonance imaging demonstrating a probable right frontal glioblastoma: (a) Axial T1-gadolinium showing peripheral enhancement with contrast. (b) Coronal magnetic resonance imaging view showing mass effect. (c) T1, sagittal view. (d) Fluid-attenuated inversion recovery magnetic resonance imaging showing surrounding edema**



**Figure 2: Intraoperative placement of Gliadel wafers (a) and postoperative computed tomography scan (b)**



**Figure 3: Postoperative magnetic resonance imaging. (a) T1 axial view. (b) Fluid-attenuated inversion recovery showing severe brain edema**

treatment of newly diagnosed glioblastoma in March 2003. Gliadel® has been available and reimbursed in France since 2005.<sup>[8]</sup>

Chowdhary *et al.* performed a recent meta-analysis in 2015, regarding the efficacy and safety of Gliadel®. Thus,

62 publications were analyzed, totally 3162 patients receiving Gliadel® and 1736 undergoing surgical resection alone. They found that, for newly diagnosed HGG, 1-year OS was increased from 48% (no Gliadel group) to 67% (Gliadel group). Two-year OS was 15% without Gliadel® and 26% with Gliadel®. Median survival was estimated around 16.4 months (Gliadel) versus 13.1 months (no Gliadel). For recurrent HGG, the differences were very small and did not reach statistical significance. The most common AEs were mass effect, surgical site infection, hydrocephalus, cysts in the resection cavity, acute hematoma, wound healing complications, and brain necrosis. Approximately, 3% of the patients receiving Gliadel® needed repeat surgery to treat complications.<sup>[3]</sup>

These findings are supported by the most recent Cochrane review of carmustine wafers. They did not find increased incidence of AEs compared to placebo, but the majority of the patients enrolled only received radiotherapy after Gliadel®.<sup>[5]</sup>

Bock *et al.*, in their retrospective study, analyzed the post-operative clinical course of 44 patients treated with surgery + Gliadel and the Stupp protocol (6 weeks radiotherapy to reach a 60 Gy dose + TMZ 75 mg/m<sup>2</sup>/day, followed by five cycles of TMZ 50–200 mg/m<sup>2</sup>). The median OS was 12.7 months. Median progression-free survival was 7 months. There was a high rate of AEs: 52%, of which 43% were classified as grade 3 or 4 (severe or life-threatening). In 27% of the cases, the AE delayed oncologic treatment and 16% of the patients required re-intervention. The most common AEs were cerebral edema (25%), wound healing abnormalities and infection (16%). CSF leak (11%), altered mental status (18%), and new onset seizures (16%) were also frequent. The authors conclude that toxicity seems currently underestimated, as only small retrospective studies assess the risks of multimodal treatment strategies combining local and systemic chemotherapy with radiotherapy.<sup>[6]</sup>

The systematic review performed in 2007 by Perry *et al.* concludes that Gliadel® is an option for selected patients with newly diagnosed malignant glioma when a near gross total resection is possible. No evidence is available comparing Gliadel® with systemic therapy, and a decision to combine Gliadel® with systemic therapy should be made for patients individually.<sup>[4]</sup>

Another retrospective study involving 165 patients (77 with newly diagnosed glioblastoma and 88 with recurrent glioblastoma), analyzed the impact of Gliadel® implantation on the rate of AE. Multivariate analysis showed that both patients with a higher number of wafers implanted and patients with recurrent tumors experienced a significant higher rate of AE and implantation-site AE (ISAE). Thus, patients with eight Gliadel® wafers implanted had a 3-fold increased risk of AE and a 5.6-fold increased risk of ISAE, and patients with recurrent tumor

had a 2.8-fold increased risk of AE and a 9.3-fold increased risk of ISAE.<sup>[7]</sup>

Our patient, implanted with 8 Gliadel wafers could be considered at higher risk of AE.

The French experience of 26 neurosurgical services is resumed in a retrospective study that specifically addresses the issue of combining Gliadel® with radiochemotherapy. One hundred and sixty-three patients were surgically intervened for HGG with Gliadel® placement. About 52% of the newly diagnosed gliomas also received radiotherapy and TMZ. The global incidence of AEs was almost 45%. Even though this rate seems to be high, they found no statistical correlation with adjuvant use of TMZ. OS was 17 months for newly diagnosed HGG.<sup>[8]</sup>

In summary, our patient suffered two of the AEs known to be related to Gliadel® placement. These AEs resulted, in fact, from a combination of treatments. According to the common terminology criteria for AEs (CTCAE version 4.0) of the US National Institute of Health and National Cancer Institute, this AE can be classified as Grade 3: severe or medically significant but not immediately life-threatening; hospitalization or prolongation of hospitalization indicated; disabling; and limiting self-care activities of daily living.

Evidence regarding safety and efficacy of combined multimodal treatment protocols of local and systemic chemotherapy is somewhat contradictory so far. Large prospective series or randomized trials are needed to elucidate this matter. In the meantime, decisions should be made for each patient individually and specific prevention strategies ought to be undertaken. Such strategies include: attention to sufficient pre- and post-operative anticonvulsants and dexamethasone; watertight dural closure; limit potential for contamination of dural closure from carmustine by irrigation and do not use instruments in contact with carmustine for dural closure; prophylactic intra- and post-operative antibiotics; irrigation of extradural wound with saline in case there has been contamination by carmustine; and a cautious dexamethasone taper. In addition, a significant connection between the surgical cavity and the ventricular system has long been considered to create a risk of obstructive hydrocephalus should a polymer or polymer fragment enter the CSF space.

## Conclusions

Implantation of Gliadel® wafers in the treatment of newly diagnosed HGG has consistently shown an improvement in OS. Combining local chemotherapy with TMZ seems attractive and it potentially adds a survival benefit. However, the risk of increased toxicity should be carefully minded as some AEs seem more common. Additional studies are required to carefully establish whether Gliadel® with the association of TMZ is well tolerated and extends the OS.

## Financial support and sponsorship

Nil.

## Conflicts of interest

There are no conflicts of interest.

## References

1. Valtonen S, Timonen U, Toivanen P, Kalimo H, Kivipelto L, Heiskanen O, *et al.* Interstitial chemotherapy with carmustine-loaded polymers for high-grade gliomas: A randomized double-blind study. *Neurosurgery* 1997;41:44-8.
2. Westphal M, Hilt DC, Bortey E, Delavault P, Olivares R, Warnke PC, *et al.* A phase 3 trial of local chemotherapy with biodegradable carmustine (BCNU) wafers (Gliadel wafers) in patients with primary malignant glioma. *Neuro Oncol* 2003;5:79-88.
3. Chowdhary SA, Ryken T, Newton HB. Survival outcomes and safety of carmustine wafers in the treatment of high-grade gliomas: A meta-analysis. *J Neurooncol* 2015;122:367-82.
4. Perry J, Chambers A, Spithoff K, Laperriere N. Gliadel wafers in the treatment of malignant glioma: A systematic review. *Curr Oncol* 2007;14:189-94.
5. Hart MG, Grant R, Garside R, Rogers G, Somerville M, Stein K. Chemotherapy wafers for high grade glioma. *Cochrane Database Syst Rev* 2011;(3):CD007294.
6. Bock HC, Puchner MJ, Lohmann F, Schütze M, Koll S, Ketter R, *et al.* First-line treatment of malignant glioma with carmustine implants followed by concomitant radiochemotherapy: A multicenter experience. *Neurosurg Rev* 2010;33:441-9.
7. De Bonis P, Anile C, Pompucci A, Fiorentino A, Balducci M, Chiesa S, *et al.* Safety and efficacy of Gliadel wafers for newly diagnosed and recurrent glioblastoma. *Acta Neurochir (Wien)* 2012;154:1371-8.
8. Menei P, Metellus P, Parot-Schinkel E, Loiseau H, Capelle L, Jacquet G, *et al.* Biodegradable carmustine wafers (Gliadel) alone or in combination with chemoradiotherapy: The French experience. *Ann Surg Oncol* 2010;17:1740-6.
9. Stupp R, Hegi ME, Mason WP, van den Bent MJ, Taphoorn MJ, Janzer RC, *et al.* Effects of radiotherapy with concomitant and adjuvant temozolomide versus radiotherapy alone on survival in glioblastoma in a randomised phase III study: 5-year analysis of the EORTC-NCIC trial. *Lancet Oncol* 2009;10:459-66.
10. Kleinberg L. Polifeprosan 20, 3.85% carmustine slow-release wafer in malignant glioma: Evidence for role in era of standard adjuvant temozolomide. *Core Evid* 2012;7:115-30.
11. Ashby LS, Ryken TC. Management of malignant glioma: Steady progress with multimodal approaches. *Neurosurg Focus* 2006;20:E3.