

Airway Management in Case of Diffuse Idiopathic Skeletal Hyperostosis

Abstract

Diffuse idiopathic skeletal hyperostosis (DISH) is associated with abnormal ossification of spinal and extraspinal appendages. Incidence of DISH is high in old age with predilection for males. Cervical hyperostosis can make intubation difficult in multiple ways. Here, we report a case of DISH bridging the cervical spine from C2 to C7 vertebrae managed using awake fiberoptic technique and a small-sized endotracheal tube.

Keywords: Cervical spine, difficult airway, diffuse idiopathic skeletal hyperostosis, fiberoptic intubation

Introduction

Forestier and Rotes-Querol^[1] in 1950 described an ankylosing hyperostotic disease of the spine developing in elderly people, now known as diffuse idiopathic skeletal hyperostosis (DISH). DISH is a syndrome with axial and peripheral manifestations of hyperostosis, i.e., abnormal ossification and calcification of ligaments. Its incidence in Indian population is not exactly known, but few studies state that it is 15%–20% in the elderly people with prevalence greater in males (27.3%) than females (12.8%).^[2,3] Affection of cervical spine by DISH can make airway management difficult in various ways. Here, we report a case of DISH having extremely difficult intubation managed using awake-fiberoptic intubation.

Case Report

A 62-year-old, 76 kg, male was suffering from dysphagia and odynophagia for almost a year. He was referred to a neurosurgeon here by an otorhinolaryngologist for associated neck stiffness. Preoperative examination revealed that he had stiff neck with almost no extension and even flexion not possible. Mouth opening was adequate with Mallampati classification Grade 3 and upper lip bite test Grade 3 status. Bilateral upper limb power was Grade 4/5. There were no associated comorbid conditions. Two-dimensional echo of heart and pulmonary function tests were normal. X-ray of the neck [Figures 1 and 2] and

magnetic resonance imaging (MRI) of cervical spine [Figure 3] revealed severe ossification of anterior longitudinal ligament leading to osseous bridging of cervical vertebrae from C2 to C7. Slight ossification of C4–C5 disc was seen, and rest of the discs were spared. A beak-like projection of osteophytes of the 6th and 7th cervical vertebrae was compressing the esophagus so severely that the posterior wall of trachea was also getting indented. A small protrusion was also seen at C2–C3 level. The posterior wall of trachea was roughened due to big protrusion and calcification of mucosa, probably due to chronic irritation [Figure 2]. He was diagnosed to have DISH and was posted for excision of osteophytes under general anesthesia.

The patient was explained about awake-fiberoptic intubation and he readily consented for. In the operation theater, monitoring was started with electrocardiography, noninvasive blood pressure monitoring, and pulse oximeter. An intravenous access was secured and injection glycopyrrolate 0.2 mg and injection midazolam 1 mg were injected to dry up the secretions and to relieve anxiety. Topical anesthesia in the form of lignocaine 4% gargles and 10% lignocaine spray was provided to the oropharynx and tongue respectively. Fiberoptic bronchoscope (FOB) was passed orally, and the epiglottis, larynx, and vocal cords were sprayed with 4% lignocaine (spray-as-you-go method). The shape of larynx was slightly distorted and posterior pharyngeal wall was

**Kundan Gosavi,
Paulomi Dey,
Sachin Swami**

*Department of Anaesthesiology,
Grant Government Medical
College, Mumbai, Maharashtra,
India*

Address for correspondence:

*Dr. Paulomi Dey,
Flat No. 13, LXN3, Sai Krupa
CHS, Kashish Park, LBS
Marg, Thane West - 400 604,
Maharashtra, India.
E-mail: paulomi.dey@gmail.com*

Access this article online

Website: www.asianjns.org

DOI: 10.4103/ajns.AJNS_235_17

Quick Response Code:



How to cite this article: Gosavi K, Dey P, Swami S. Airway management in case of diffuse idiopathic skeletal hyperostosis. Asian J Neurosurg 2018;13:1260-3.

This is an open access journal, and articles are distributed under the terms of the Creative Commons Attribution-NonCommercial-ShareAlike 4.0 License, which allows others to remix, tweak, and build upon the work non-commercially, as long as appropriate credit is given and the new creations are licensed under the identical terms.

For reprints contact: reprints@medknow.com

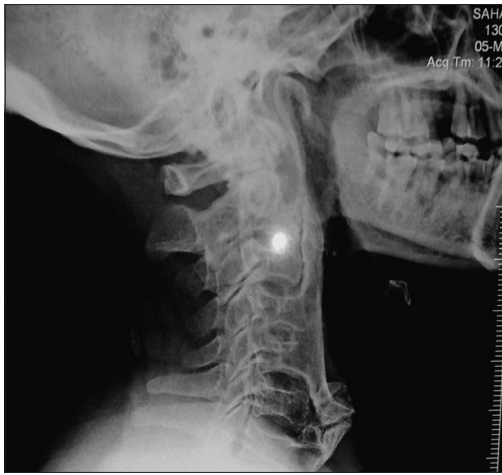


Figure 1: Diffuse idiopathic skeletal hyperostosis – X-ray 1

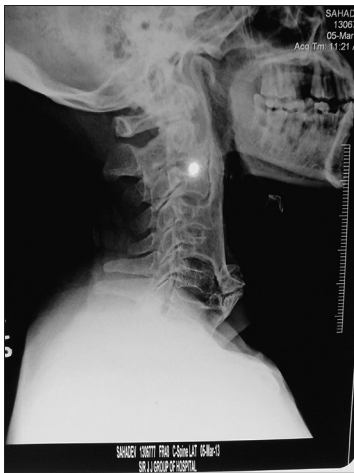

Figure 2: Diffuse idiopathic skeletal hyperostosis – X-ray 2

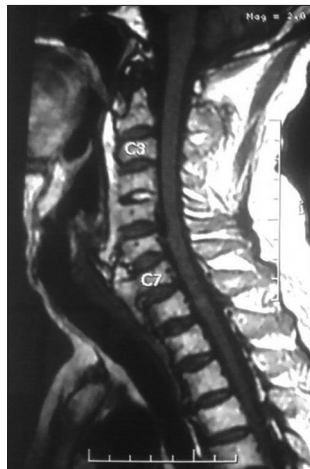

Figure 3: Diffuse idiopathic skeletal hyperostosis – magnetic resonance imaging

obviously irregular due to osteophytes. The large protruding bulge was obstructing the view of subglottic region; almost half of the tracheal lumen was obstructed. We estimated that the tracheal lumen would accommodate endotracheal

tube (ETT) of size greater than 7.5mm (external diameter). The FOB was successfully passed beyond the protrusion, and the upper part of the trachea was also sprayed with 4% lignocaine. A well-lubricated Portex®-flexometallic ETT of size 7.5 was then passed into the trachea over FOB until the resistance (distal holdup) was encountered. However, ETT could not be pushed beyond 18-cm mark at incisors. The FOB was withdrawn. End-tidal carbon dioxide adapter and Bain's circuit were connected. A good capnogram was present. We inflated the cuff and it started making a noise in the pharynx. We passed the FOB by the side of tube into the pharynx to check the position of cuff and found the inflated cuff lying proximal to cords while ETT tip was just entering the larynx. We put an airway exchange catheter (Cook: 14 Fr) through the ETT, deflated the cuff, and tried to push the ETT gently over the bougie. However, it was too difficult to navigate cuff, through the narrowed subglottic area. Hence, we removed no. 7.5 ETT and tried a well-lubricated no. 7.0 ETT. It could be navigated with a little force up to 24-cm mark. The bougie was removed and ventilation on Bain's circuit was restarted. The position of cuff was checked again by FOB after inflation. The patient was induced with injection propofol and rocuronium. Anesthesia was maintained with sevoflurane, nitrous oxide, and oxygen on a circle absorber system. Peak inspiratory pressure remained <25 cmH₂O throughout the surgery in spite of the small diameter of ETT. The protruding osteophytes at C5, C6, and C7 were excised. Surgery was uneventful. At the end of surgery, neuromuscular blockade was reversed with neostigmine. After confirming good neuromuscular recovery, the patient was extubated on Cook airway exchange catheter. The catheter was removed after half an hour of uneventful monitoring. Oxygen was supplied with a mask. The patient was monitored for 2 h before shifting to ward. Postoperative period was uneventful. Follow-up revealed that the patient was almost relieved of dysphagia and had no other complications.

Discussion

DISH is an ossifying diathesis which may affect spinal and extraspinal sites.^[4,5] The hyperostosis is probably due to abnormal bone cell activity under the influence of certain metabolic factors. Serum matrix Gla protein may be a marker of such osteometabolic syndrome.^[4] Ossification of the anterior longitudinal ligament, paravertebral osteophyte formation, and ligamentous calcification are more common and marked in thoracolumbar spine than elsewhere. However, isolated and predominant cervical spinal involvement may occur.^[1,5,6] Peripheral manifestations may include hyperostosis frontalis, calcaneal spur, and postsurgical heterotrophic hip ossification. Resnik^[7] proposed a radiological criterion of diagnosis of DISH as follows:

1. Osseous bridging of at least four contiguous vertebral bodies with

2. Absence of degenerative disc disease and
3. Absence of inflammatory changes in facets and sacro-iliac joints.

DISH is a disease of old age peaking in the 60s, with males more affected than females. Early-age obesity, diabetes mellitus, and hyperuricemia are predisposing risk factors.^[3,4]

Otherwise asymptomatic, dysphagia (0.2%–28%) and stiff neck are the most common symptoms of DISH. Dyspnea, stridor, myelopathy, and predisposition to catastrophic spinal cord injuries have been reported in some cases.^[1,6,8] X-ray of cervical spine is usually helpful in diagnosis, but MRI is the modality of choice to delineate the airway and spine.^[4,6,9]

Mechanism of difficult intubation in DISH is poorly understood and literature points to multiple abnormalities.^[10] Cervical spine stiffness and immobility is an obvious risk factor associated with DISH. Some reports mentioned difficult intubation due to mass-like protrusion of posterior pharyngeal wall as in our case.^[10-12] Aziz *et al.*^[13] had difficulty in insertion of intubating laryngeal mask airway due to the same reason. Crosby and Grahovac found anterior displacement of the larynx with an acute angulation of the trachea just below the larynx and had to use a smaller ETT like in our case due to narrowing of trachea.^[5] Yamamoto *et al.*^[14] encountered a great difficulty not only in spine mobility but also in epiglottis elevation. Togashi *et al.*^[15] reported an interesting case of difficult ventilation due to abutting of beveled tracheal tube orifice against the cervical osteophytes and deviated trachea.

Most of these cases were managed by awake FOB intubation. We too anticipated hypopharyngeal narrowing in this case and adopted the same strategy. Laryngeal mask airway and elective tracheostomy were the other options for securing airway in this case but they were not preferred due to risk associated in sharing airway with surgeons and chronic morbidity, respectively.

Preoperative laryngeal edema is common in DISH patients due to chronic mechanical irritation of the retrocricoid area from rolling over spiky osteophytes. The tissue reaction around the osteophyte spikes which leads to fibrosis and adhesions preventing the normal gliding movements of the esophagus and larynx during deglutition is suggested as a cause of this.^[11,16] The edema may worsen due to surgical procedure. There are reports stating the need of tracheostomy or reintubation in postoperative as well as preoperative period.^[11,12] Hence, we decided to extubate the patient on an airway exchange catheter. Furthermore, prophylactic steroid shot was given in premedication to prevent laryngeal edema. Fluid management, temperature regulation, and pre- and postoperative physiotherapy were the other issues handled successfully in this case.

Conclusion

DISH is a disease of old age. As it remains asymptomatic in many cases, its diagnosis needs a high index of suspicion and radiological assistance. DISH can make the intubation difficult in multiple ways and the anesthetist must be familiar and prepared to tackle the emergency situations that may arise. Awake-fiberoptic intubation remains the technique of choice for airway management in DISH.

Declaration of patient consent

The authors certify that they have obtained all appropriate patient consent forms. In the form the patient(s) has/have given his/her/their consent for his/her/their images and other clinical information to be reported in the journal. The patients understand that their names and initials will not be published and due efforts will be made to conceal their identity, but anonymity cannot be guaranteed.

Financial support and sponsorship

Nil.

Conflicts of interest

There are no conflicts of interest.

References

1. Forestier J, Rotes-Querol J. Senile ankylosing hyperostosis of the spine. *Ann Rheum Dis* 1950;9:321-30.
2. Weinfeld RM, Olson PN, Maki DD, Griffiths HJ. The prevalence of diffuse idiopathic skeletal hyperostosis (DISH) in two large American Midwest metropolitan hospital populations. *Skeletal Radiol* 1997;26:222-5.
3. Kiss C, Szilágyi M, Paksy A, Poór G. Risk factors for diffuse idiopathic skeletal hyperostosis: A case-control study. *Rheumatology (Oxford)* 2002;41:27-30.
4. Sarzi-Puttini P, Atzeni F. New developments in our understanding of DISH (diffuse idiopathic skeletal hyperostosis). *Curr Opin Rheumatol* 2004;16:287-92.
5. Crosby ET, Grahovac S. Diffuse idiopathic skeletal hyperostosis: An unusual cause of difficult intubation. *Can J Anaesth* 1993;40:54-8.
6. Sreedharan S, Li YH. Diffuse idiopathic skeletal hyperostosis with cervical spinal cord injury – A report of 3 cases and a literature review. *Ann Acad Med Singapore* 2005;34:257-61.
7. Resnick D. Degenerative diseases of the vertebral column. *Radiology* 1985;156:3-14.
8. Mader R. Clinical manifestations of diffuse idiopathic skeletal hyperostosis of the cervical spine. *Semin Arthritis Rheum* 2002;32:130-5.
9. Aydin E, Akdogan V, Akkuzu B, Kirbaş I, Ozgirgin ON. Six cases of Forestier syndrome, a rare cause of dysphagia. *Acta Otolaryngol* 2006;126:775-8.
10. Bougaki M, Sawamura S, Matsushita F, Hanaoka K. Difficult intubation due to ossification of the anterior longitudinal ligament. *Anaesthesia* 2004;59:303-4.
11. Kim YS, Lee JJ, Chung YH, Kim ES, Chung IS. Postoperative obstructing laryngeal edema in patients with diffuse idiopathic skeletal hyperostosis of cervical spine – A report of two cases. *Korean J Anesthesiol* 2011;60:377-80.
12. Baxi V, Gaiwal S. Diffuse idiopathic skeletal hyperostosis of

- cervical spine – An unusual cause of difficult flexible fiber optic intubation. *Saudi J Anaesth* 2010;4:17-9.
13. Aziz ES, Thompson AR, Baer S. Difficult laryngeal mask insertion in a patient with Forestier's disease. *Anaesthesia* 1995;50:370.
 14. Yamamoto T, Katoh H, Wakamatsu M, Kondo U. Anesthetic problems in patients with Forestier's disease. *Masui* 1992;41:1008-10.
 15. Togashi H, Hirabayashi Y, Mitsuhata H, Saitoh K, Shimizu R. The beveled tracheal tube orifice abutted on the tracheal wall in a patient with Forestier's disease. *Anesthesiology* 1993;79:1452-3.
 16. Marks B, Schober E, Swoboda H. Diffuse idiopathic skeletal hyperostosis causing obstructing laryngeal edema. *Eur Arch Otorhinolaryngol* 1998;255:256-8.