

Minimally Invasive Spine (MIS) Surgery in Traumatic Thoracolumbar Fractures: A Single-Center Experience

Abstract

Objective: Traumatic thoracolumbar fractures are common, and surgical fixation is a well-established treatment option, with the aim to achieve spinal stability and preserve neurological function. Pedicle screw fixation using a minimally invasive spine (MIS) surgical approach has emerged as an alternative approach for the treatment of thoracolumbar fractures. The aim of this study is to collect data regarding epidemiology, management, and outcomes of patients treated with MIS pedicle screw fixation for traumatic thoracolumbar fractures in our neurosurgical department.

Materials and Methods: This was a retrospective cohort study including all patients who underwent MIS fixation from March 2013 to March 2017. **Results:** A total of 125 patients were included, 61 males and 64 females; the mean age was 59 years. The majority of injuries were from falls. In 48 cases, the fracture involved a thoracic vertebra and in 77 cases a lumbar vertebra. More than 10% of the patients presented with a neurological deficit on admission and 75% of those showed postoperative improvement in their neurology. The average length of hospital stay was 14 days. MIS fixation achieved a satisfactory regional sagittal angle (RSA) postoperatively in all patients. The vast majority of patients had no or mild postoperative pain and achieved a good functional outcome. **Conclusions:** MIS fixation is a safe surgical option with comparable outcomes to open surgery and a potential reduction in perioperative morbidity. MIS surgery achieves a rapid and significant improvement in pain score, functional outcome, Frankel Grade, and RSA. We expect that MIS fixation will become the predominant technique in the management of traumatic thoracolumbar fractures.

Keywords: Minimally invasive spine surgery, regional sagittal angle, thoracolumbar fracture

**Mohamed Naufel Ansar,
Syed Maroof Hashmi,
Francesca Colombo**

*Department of Neurosurgery,
Royal Preston Hospital, Preston,
United Kingdom*

Introduction

Traumatic spinal fractures are common, with a constantly increasing rate of referrals to neurosurgical tertiary centers in the United Kingdom. These injuries can result in potentially devastating consequences including pain, deformity, and neurological deficits.^[1-5] In addition to the physical impairment, the long-term effects of spinal injuries may also have a significant psychological, economic, and social impact.^[6-9] Surgical fixation is a well-established treatment option for spinal fractures, with the aim of achieving spinal stability and preservation of neurological function.

Open pedicle screw fixation is the conventional technique to promote fusion and restore stability. This is sometimes used in combination with other procedures such as interbody fusion or vertebroplasty.

Open fixation techniques are an effective treatment for spinal fractures across cervical, thoracic, and lumbar spine and for degenerative conditions. However, they are often associated with considerable morbidity such as significant postoperative back pain, increased duration of surgery, and prolonged hospital stay. Damage to the surrounding neurological structures, incomplete or suboptimal stabilization, and instrumentation failure have been described as well, together with high infection rates and high blood loss.^[2-4,6,10,11]

Most recently, pedicle screw fixation using a minimally invasive surgical (MIS) approach has emerged as an alternative approach for the treatment of thoracolumbar fractures, aiming to minimize soft-tissue injury and perioperative morbidity.^[7,8,10] MIS utilizes fluoroscopic imaging or computed tomography to guide percutaneous placement of pedicle screws

Address for correspondence:

*Dr. Mohamed Naufel Ansar,
Department of Neurosurgery,
Royal Preston Hospital,
Sharoe Green Lane, Fulwood,
Preston PR2 9HT, Preston,
United Kingdom.
E-mail: naufel.ansar@lthtr.
nhs.uk*

Access this article online

Website: www.asianjns.org

DOI: 10.4103/ajns.AJNS_236_19

Quick Response Code:



How to cite this article: Ansar MN, Hashmi SM, Colombo F. Minimally invasive spine (MIS) surgery in traumatic thoracolumbar fractures: A single-center experience. *Asian J Neurosurg* 2020;15:76-82.

Submission: 24-07-2019 **Accepted:** 23-12-2019
Published: 25-02-2020

This is an open access journal, and articles are distributed under the terms of the Creative Commons Attribution-NonCommercial-ShareAlike 4.0 License, which allows others to remix, tweak, and build upon the work non-commercially, as long as appropriate credit is given and the new creations are licensed under the identical terms.

For reprints contact: reprints@medknow.com

and instrumentation in order to achieve the reduction and fixation of spinal fractures. This technique reduces healing times, postoperative analgesia requirements, and intraoperative blood loss while achieving a comparable level of fixation and stabilization in the majority of cases. Although more studies are required, so far the results of MIS fixation for the management of thoracolumbar fractures are promising.^[1,9-11]

The aim of this study is to collect data regarding epidemiology, management, and outcomes of patients treated with MIS pedicle screw fixation for traumatic thoracolumbar fractures in our neurosurgical department in the United Kingdom.

Materials and Methods

All the patients who underwent MIS surgery for traumatic thoracolumbar fractures at Royal Preston Hospital from March 2013 to March 2017 were included in this study. Patients' data, operation notes, and clinical details including intraoperative and postoperative complications were collected retrospectively from patients' notes and our online database. We exclusively included patients who were not deemed suitable for conservative management of the fracture, in particular, either patients with three-column injury or new neurological deficit on presentation. Stable osteoporotic fractures were not included in this study as they are normally treated conservatively in our center.

Causes of injury were grouped into six categories: fall from a height, fall from standing height, fall downstairs, road traffic accident, fall from a horse, and blunt trauma. The fracture level was identified from radiological images and broadly divided into (a) thoracic and (b) lumbar. Thoracic fractures were further subdivided into upper-thoracic (T1–T4), mid-thoracic (T5–T8), and lower-thoracic (T9–T12); lumbar fractures were grouped into L1, L2, L3, and L4.

The Frankel Grading system was used to classify the degree of neurological deficit. The degree of preoperative pain was assessed using the Visual Analog Scale (VAS). Patients were asked to grade their pain at the time of admission on a scale from 0 to 10. Zero is equivalent to no pain, 1–3 is mild pain, 4–6 is moderate pain, and 7–10 is considered severe pain.

All the pedicle screws were placed with fluoroscopy guidance, using the standard technique for percutaneous pedicle screw placement. All the cases were performed by a group of senior spinal neurosurgeons. Depending on the number of levels fixed during MIS surgery, the procedure was categorized as: (A) 1 level above and below the fracture, (B) 2 levels above and below the fracture, and (C) short pedicle screws at fracture level in addition to 1 level above and below.

The length of stay (LOS) in the hospital was calculated in days from the day of admission to the date of discharge

from the neurosurgical unit. All patients who were transferred to spinal rehabilitation or were repatriated to the local hospital were considered as discharged. Outpatient follow-up was conducted at 2, 6, 12, and 24 months after surgery in the majority of patients. A few patients were discharged earlier than 24 months based on surgeons' preference and patient condition. The overall functional outcome was assessed for each patient at the end of the follow-up period. Patients were divided into three groups: good functional outcome (able to perform daily activities independently and return to functional baseline), restriction in the daily activities, and poor functional outcome (unable to perform daily activities independently).

The regional sagittal angle (RSA) was measured preoperatively in the immediate postoperative period and on the final weight-bearing X-ray. The difference in angle between the first and last radiographs was tabulated in order to assess the degree of correction of spinal deformity. The lateral radiographs of all the patients were analyzed using the digital radiography software on our picture archiving and communication system using a magnified image. A positive RSA indicates lordosis, and a negative angle indicates kyphosis as described in previous studies [Figure 1].^[12]

Results

A total of 125 patients underwent MIS fixation with percutaneous pedicle screws between March 2013 and March 2017. Sixty-one patients were male (49%) and 64 were female (51%); the mean age was 59 years with the youngest patient being 17 years old and the oldest 79.

The majority of injuries were from falls. Forty-five patients fell from a height (36%), 26 fell downstairs (20.8%), 25 were involved in a road traffic accident (20%), eleven fell from standing height (8.8%), ten patients fell from a horse (8%), and in eight cases, the cause of fracture was blunt trauma (6.4%).

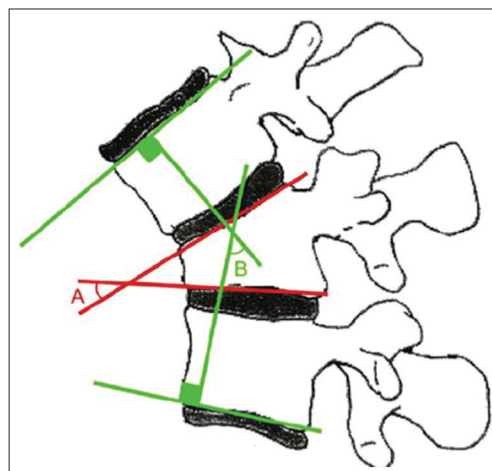


Figure 1: A – Local sagittal angle; B – Regional sagittal angle 12

All the patients had a single-level traumatic thoracic or lumbar fracture. In 48 cases, the fracture involved a thoracic vertebra (38.4%) and in 77 cases a lumbar vertebra (61.6%). More than half of the fractures (53%) were at the thoracolumbar junction (either T12 or L1). Among the thoracic fractures, 4 (3.2%) were upper-thoracic, 13 (10.4%) were mid-thoracic and 31 (24.8%) were lower-thoracic fractures. Forty-four patients had a fracture at L1 (35.2%), twenty at L2 (16%), nine at L3 (7.2%), and four at L4 (3.2%). No patient had a fracture at L5 level [Figure 2].

Sixteen patients (12.8%) presented with a neurological deficit on admission on our neurosurgical unit. Two patients were grade A according to the Frankel Grading classification, nine were Grade C, and five were Grade D. All patients with neurological deficits underwent posterior decompression at the same time of the MIS fixation. The five patients who presented with Grade D all improved to normal power. Out of the nine patients with Grade C, two improved to normal, five improved to Grade D, and two remained unchanged. All the patients who presented with Grade A deficit failed to show any neurological improvement [Table 1].

Eighty-five patients (68%) had severe preoperative pain, 33 patients (26.4%) had moderate pain, and 7 patients had mild pain (5.6%). Postoperatively, 82 patients (65.6%) had no pain and 13 (10.4%) reported mild pain. Twenty-four (19.2%) patients had persistent moderate back pain; three patients (2.4%) had severe back pain. Patients with moderate and severe pain were investigated with further imaging. Most patients did not have any pathology amenable to surgical intervention and were, therefore, referred to the pain specialists. One patient needed a vertebrectomy with cage placement. One patient had pain over the screw site and was offered an operation to remove the screw but declined it [Figure 3].

Ninety-five patients (76%) achieved a good functional outcome and were able to go back to work and their normal daily activities. All the patients with absence of pain or mild postoperative pain belong to this group. The patients with moderate pain had some restriction of their daily activities, and all the patients with severe pain belong to the poor functional outcome group. Three patients were lost to follow-up at their last clinic review, so the final outcome was not measured in their case.

Sixty-four patients (51.2%) underwent fixation one level above and one level below the fracture; 48 (38.4%)

had fixation two levels above and two levels below, and 13 (10.4%) had short pedicle screws inserted at the fracture level along with fixation one level above and one below. Four patients underwent vertebroplasty at the fractured levels or augmentation of pedicle screws in addition to fixation. The procedures were performed by either a consultant or a senior spinal fellow in all cases, using a standard technique as previously described in the literature. Figure 4 shows postoperative standing X-rays of patients at their second follow-up at 6 months.

The mean preoperative RSA of thoracic fractures was -13.5° , the mean postoperative RSA was -5.7° , and at the end of the follow-up period, it was -6.5° . The mean

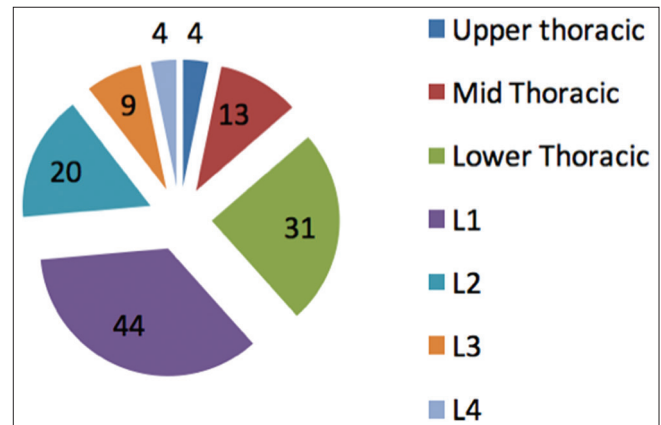


Figure 2: Distribution according to fracture level

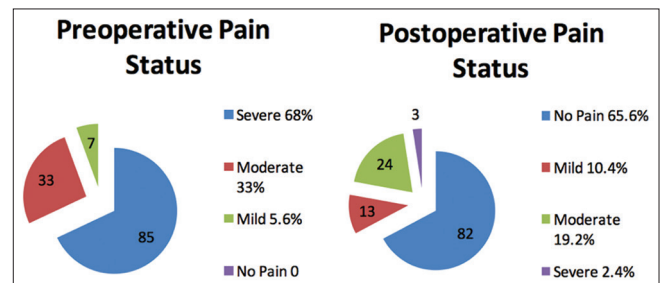


Figure 3: Pre and Post-operative pain status

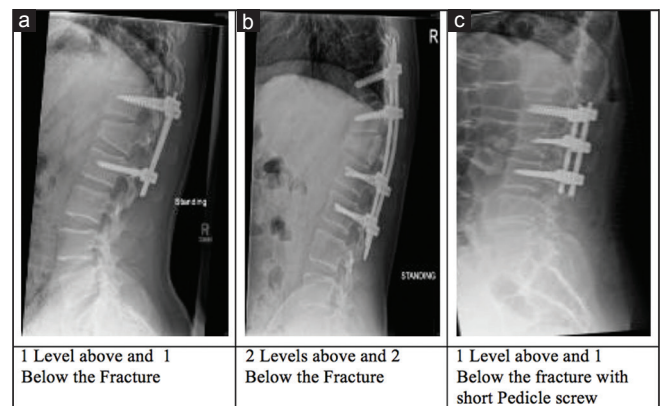


Figure 4: Examples of post-operative X-rays at 6 months. Source: Royal Preston Hospital, Department of Neurosurgery

Table 1: Neurological deficits according to Frankel Grading system

	Grade					Total number of patients with neurological deficits
	A	B	C	D	E	
Preoperative	2	0	9	5	-	16
Postoperative	2	0	2	5	7	9

preoperative RSA of lumbar fractures was -4.2° , the mean postoperative RSA was $+3.1^\circ$, and at the end of the follow-up period, it was $+2.8^\circ$ [Table 2].

Ninety-three patients were discharged home, 19 were sent to their local hospital for short-term rehabilitation prior to discharge, and 13 required long-term spinal rehabilitation at a dedicated spinal cord injury center. The average LOS in the hospital was 14 days (2–118 days).

Six patients (4.8%) had a wound infection; 5 of them were treated conservatively with antibiotics and one patient required surgical debridement. Three patients had pneumonia. In two patients, the upper-level screws pulled out, and in two cases, one screw was misplaced. These four patients underwent surgical intervention with either replacement or removal of the screws.

Discussion

The aim of surgical intervention following traumatic spinal fractures of the thoracolumbar spine is to achieve spinal stability, prevent further loss of neurological function, facilitate early mobilization, and obtain the best possible outcome while minimizing pain and morbidity.^[7,8,10] Open pedicle screw fixation is an effective treatment option for these fractures; however, it is associated with a significant degree of postoperative pain and prolonged hospital stay. In our single-center retrospective study, we collected evidence to support that MIS fixation is also a safe and less invasive option to manage these types of fractures.

We include a significant number of patients presenting with traumatic thoracolumbar fractures caused by a variety of mechanisms of injury. Our cohort of patients includes a wide age range, an equal distribution of gender, and different degrees of preoperative fitness, and it is overall a good representation of the general population, making our results relevant to other neurosurgical centers. We excluded patients deemed suitable for conservative management, for example, osteoporotic fractures in the elderly. However, 11 patients were elderly and sustained a fall from standing; hence, it is possible that they had undiagnosed osteoporosis.

Our outcomes following surgery are good. More than 10% of the patients presented with a neurological deficit on admission. Among these patients, 75% showed postoperative improvement in their neurology, including 7 patients who regained normal function. No patient had worse neurology postoperatively. No patient died within 30 days after surgery, and as a result of good pain control and early mobilization, only a very small number of patients (3) developed medical complications such as pneumonia. The infection rate was comparable to open surgery infection rate and other MIS studies previously published in the literature (around 4%). The average length of hospital stay was 14 days. Ten patients were medically fit for discharge few days after surgery, but they stayed in the hospital for more than 100 days each due to social issues.

Some of the patients had prolonged hospital stay due to additional occupational therapy requirements. If we exclude these ten patients, the average length of hospital stay for 115 patients was 6.3 days which is better than reported hospital stay in open surgery. It would be interesting to collect further data and differentiate between hospital stay related to the surgical procedure and hospital stay related to social issues. Spinal stability was achieved in every patient at the end of the follow-up period. We have not collected data related to fusion as the aim of the fixation was mainly neurological decompression and stabilization.

MIS fixation achieved a satisfactory RSA angle postoperatively in all patients. In fact, the natural kyphosis of the thoracic spine and lordosis of the lumbar spine were maintained, while improving the initial pathological RSA. The vast majority of patients had no or mild postoperative pain (76%) and achieved a good functional outcome, being able to go back to their preinjury baseline. Our study demonstrates that MIS fixation achieves adequate correction in RSA, which is linked with good surgical outcome, excellent pain relief, and early return to normal activities. Minimally invasive approaches dramatically decrease paraspinal musculature stripping, leaving the attachment of the muscle to the bone intact, reducing ligament disruption, providing direct access to the transverse processes and pedicles, and hence decreasing bleeding and postoperative pain.^[13-15] Other previous studies, for example, Jian *et al.*^[15] have shown that percutaneous fixation of thoracolumbar fractures results in equivalent or better clinical outcomes when compared to the open group.

Indications for minimally invasive spinal fixation have expanded in the recent years and are now comparable to those for open surgery.^[16-19] Surgeons are becoming increasingly experienced in this field; however, we must acknowledge that most MIS spinal techniques have a steep learning curve and other authors suggest that the operating surgeon must have adequate experience with open procedures before attempting minimally invasive approaches.^[19-21] For the same reason, depending on the surgeon's experience, MIS fixation may in some cases take more time to perform than open surgery and may result in inadequate restoration of vertebral body height and RSA.^[16,20,22] It is also worth mentioning that MIS techniques often require a not irrelevant amount of fluoroscopy; consequently, appropriate training to reduce patient and occupational radiation exposure is necessary.^[23-25]

According to previous studies assessing the adequacy of screw placement in MIS, up to 98% of screws were reported to be in a good or excellent position.^[26,27] Similarly, in our study, we found that 96.8% of screws were in an excellent position. The screws that we placed had less tendency to violate the lateral wall of the pedicle compared to other MIS studies, giving similar results to open fixation. In 2013, a study by Dong *et al.*, and in 2016

Table 2: Regional sagittal angle preoperatively, postoperatively, and at the end of the follow-up period

Level of the fracture	Preoperative RSA at the end of the follow-up period	Postoperative RSA at the end of the follow-up period	Preoperative Level of the fracture	Postoperative Level of the fracture	RSA at the end of the follow-up period	Preoperative RSA at the end of the follow-up period	Postoperative RSA at the end of the follow-up period	RSA at the end of the follow-up period		
T3	-11.2	-5.9	-6.6	T12	-15.2	-6.1	-7.1	-4.6	+3.4	+3.1
T4	-14.4	-7.3	-7.9	T12	-18.6	-9.3	-10.5	-2.9	+4.2	+3.8
T4	-12.5	-6.8	-7.5	T12	-16.3	-7.5	-7.5	-4.5	+2.7	+2.3
T4	-11.7	-5.1	-5.9	T12	-14.1	-6.1	-6.9	-4.3	+3.7	+3.3
T5	-18.6	-9.5	-10.2	T12	-9.8	-2.4	-3.3	-4.5	+3.5	+3.1
T5	-17.5	-9.2	-9.9	T12	-16.3	-6.5	-6.9	-3.7	+3.8	+3.4
T6	-13.9	-6.4	-7.3	L1	-4.9	+2.1	+1.8	-4.6	+3.2	+2.9
T6	-16.1	-8.2	-8.9	L1	-5.9	+1.5	+1.2	-4.7	+2.9	+2.6
T6	-13.9	-6.4	-7.7	L1	-3.6	+3.5	+3.3	-4.9	+2.6	+2.5
T6	-17.8	-8.7	-10.1	L1	-5.3	+1.9	+1.6	-4.5	+3.5	+2.9
T7	-18.4	-8.9	-9.5	L1	-5.3	+1.6	+1.4	-5.2	+2.9	+2.6
T7	-18.3	-9.3	-9.9	L1	-5.1	+2.3	+2.1	-3.5	+2.8	+3.1
T8	-15.1	-7.2	-7.9	L1	-4.9	+2.7	+2.5	-4.7	+3.2	+2.6
T8	-14.5	-6.7	-7.6	L1	-3.1	+3.8	+3.5	-4.6	+3.1	+2.7
T8	-9.7	-1.5	-2.7	L1	-3.8	+3.7	+3.4	-3.5	+3.9	+3.5
T8	-7.5	-0.8	-1.5	L1	-5.2	+1.6	+1.3	-3.9	+3.6	+3.4
T8	-16.1	-7.6	-8.7	L1	-4.9	+2.9	+2.6	-3.1	+3.8	+3.6
T9	-15.6	-5.9	-7.1	L1	-4.3	+3.2	+2.8	-4.3	+3.1	+2.8
T9	-13.9	-5.6	-6.4	L1	-3.2	+3.4	+3.1	-4.9	+2.7	+2.4
T10	-6.7	-0.7	-1.5	L1	-3.9	+3.1	+2.7	-3.6	+3.2	+2.9
T10	-5.1	-1.2	-2.1	L1	-4.4	+2.8	+2.3	-4.4	+2.9	+2.7
T10	-16.3	-7.2	-8.1	L1	-3.7	+3.4	+2.7	-4.2	+2.8	+2.5
T11	-14.2	-6.3	-6.9	L1	-4.6	+2.7	+2.3	-3.9	+3.4	+3.2
T11	-17.3	-10.1	-10.9	L1	-4.4	+3.5	+3.1	-4.5	+2.7	+2.5
T11	-18.1	-10.8	-11.3	L1	-4.6	+3.2	+2.9	-4.1	+3.2	+3.1
T12	-16.7	-8.1	-9.2	L1	-5.1	+1.3	+1.1	-3.7	+2.9	+2.6
T12	-13.7	-3.7	-4.5	L1	-4.3	+2.7	+2.5	-2.9	+3.7	+3.5
T12	-14.1	-6.2	-7.1	L1	-4.8	+2.8	+2.5	-2.1	+3.5	+3.3
T12	-9.7	-2.3	-3.2	L1	-3.4	+3.8	+3.4	-2.6	+4.2	+3.9
T12	-13.9	-4.8	-5.6	L1	-5.1	+1.9	+1.5	-2.4	+3.9	+3.6
T12	-16.1	-8.3	-8.9	L1	-4.8	+3.4	+3.1	-3.9	+2.9	+2.7
T12	-6.4	-0.8	-2.1	L1	-3.9	+3.8	+3.4	-4.7	+3.8	+3.6
T12	-3.9	0	-0.7	L1	-2.7	+3.7	+3.4	-4.9	+3.1	+2.9
T12	-15.4	-7.1	-7.1	L1	-4.9	+2.8	+2.5	-3.7	+3.2	+2.9
T12	-17.6	-9.3	-10.4	L1	-5.2	+2.1	+1.8	-3.4	+3.1	+2.9
T12	-7.9	-1.9	-2.3	L1	-4.6	+3.3	+2.8	-4.8	+3.2	+2.9
T12	-6.8	-0.6	-1.2	L1	-3.8	+3.9	+3.6	-4.3	+3.5	+3.1

Contd...

Table 2: Contd...

Level of the fracture	Preoperative RSA at the end of the follow-up period	Level of the fracture	Preoperative Postoperative RSA at the end of the follow-up period	Level of the fracture	Preoperative Postoperative RSA at the end of the follow-up period
T12	-6.9	L1	-4.8	L4	-5.1
T12	-13.6	L1	-4.5	L4	-2.1
T12	-16.4	L1	-4.1	L4	-3.6
T12	-11.9	L1	-4.5	L4	-4.3
T12	-12.3	L1	-3.7		
RSA – Regional sagittal angle					
	-0.5		+3.8		+1.4
	-5.4		+3.4		+3.4
	-4.3		+3.1		+3.4
	-3.9		+3.6		+2.6
	-5.2		+3.8		+1.2
	-1.6		+3.5		+3.1
	-5.9		+2.7		+3.1
	-4.3		+3.3		+2.5
	-6.1		+3.5		

McAnany *et al*, on short-segment percutaneous screw fixation demonstrated that the curative effect achieved by both open and percutaneous approaches are similar, with no difference in radiological outcomes.^[13,28]

The strength of our study is the high number of patients and screws when compared to other publications available in the literature. The retrospective nature of the study is a limiting factor. Another limitation of our study is the lack of a comparison group. We included exclusively patients who were already considered unsuitable for conservative management, and we did not collect data regarding open fixation in our center. Blood loss, surgical time, and vertebral height postoperatively have not been assessed in our research project, despite being relevant variables when comparing open surgery to minimally invasive techniques.^[28] New prospective studies with a higher number of patients and screws, potentially including cases with fractures at multiple levels and quantifying the above-mentioned variables (blood loss, surgical time, and vertebral height) may be useful to further assess the outcomes of minimally invasive techniques.

Conclusions

Our findings are comparable to other studies available in the literature and confirm that MIS fixation is a safe surgical option with outcomes comparable to open surgery and a potential reduced morbidity. MIS surgery achieves a rapid and significant improvement in VAS score, functional outcome, Frankel Grade, and RSA. With technological advancements, we expect that MIS fixation will become the predominant technique in the management of unstable traumatic thoracolumbar fractures.

Financial support and sponsorship

Nil.

Conflicts of interest

There are no conflicts of interest.

References

- Rampersaud YR, Annand N, Dekutoski MB. Use of minimally invasive surgical techniques in the management of thoracolumbar trauma: Current concepts. *Spine (Phila Pa 1976)* 2006;31:S96-102.
- Gertzbein SD. Scoliosis research society. Multicenter spine fracture study. *Spine (Phila Pa 1976)* 1992;17:528-40.
- Levine AM, McAfee PC, Anderson PA. Evaluation and emergent treatment of patients with thoracolumbar trauma. *Instr Course Lect* 1995;44:33-45.
- Ge CM, Wang YR, Jiang SD, Jiang LS. Thoracolumbar burst fractures with a neurological deficit treated with posterior decompression and interlaminar fusion. *Eur Spine* . 2011;20: 2195-2201.
- Meldon SW, Moettus LN. Thoracolumbar spine fractures: Clinical presentation and the effect of altered sensorium and major injury. *J Trauma* 1995;39:1110-4.
- Bosch A, Stauffer ES, Nickel VL. Incomplete traumatic

- quadriplegia. A ten-year review. *JAMA* 1971;216:473-8.
7. Cooper C, Dunham CM, Rodriguez A. Falls and major injuries are risk factors for thoracolumbar fractures: Cognitive impairment and multi injuries impede the detection of back pain and tenderness. *J Trauma* 1995;38:692-6.
 8. Riggins RS, Kraus JF. The risk of neurologic damage with fractures of the vertebrae. *J Trauma* 1977;17:126-33.
 9. Stover SL, Fine PR. The epidemiology and economics of spinal cord injury. *Paraplegia* 1987;25:225-8.
 10. Rehtine GR, Bono PL, Cahill D, Bolesta MJ, Chrin AM. Postoperative wound infection after instrumentation of thoracic and lumbar fractures. *J Orthop Trauma* 2001;15:566-9.
 11. Verlaan JJ, Diekerhof CH, Buskens E, van der Tweel I, Verbout AJ, Dhert WJ, *et al.* Surgical treatment of traumatic fractures of the thoracic and lumbar spine: A systematic review of the literature on techniques, complications, and outcome. *Spine (Phila Pa 1976)* 2004;29:803-14.
 12. Siebenga J, Segers MJ, Elzinga MJ, Bakker FC, Haarman HJ, Patka P. Spine fractures caused by horse riding. *Eur Spine J* 2006;15:465-71.
 13. Dong SH, Chen HN, Tian JW, Xia T, Wang L, Zhao QH, *et al.* Effects of minimally invasive percutaneous and trans-spatium intermuscular short-segment pedicle instrumentation on thoracolumbar mono-segmental vertebral fractures without neurological compromise. *Orthop Traumatol Surg Res* 2013;99:405-11.
 14. Lee JK, Jang JW, Kim TW, Kim TS, Kim SH, Moon SJ. Percutaneous short-segment pedicle screw placement without fusion in the treatment of thoracolumbar burst fractures: Is it effective?: Comparative study with open short-segment pedicle screw fixation with posterolateral fusion. *Acta Neurochir (Wien)* 2013;155:2305-12.
 15. Jiang XZ, Tian W, Liu B, Li Q, Zhang GL, Hu L, *et al.* Comparison of a paraspinous approach with a percutaneous approach in the treatment of thoracolumbar burst fractures with posterior ligamentous complex injury: A prospective randomized controlled trial. *J Int Med Res* 2012;40:1343-56.
 16. Mobbs RJ, Sivabalan P, Li J. Technique, challenges and indications for percutaneous pedicle screw fixation. *J Clin Neurosci* 2011;18:741-9.
 17. Hsieh PC, Koski TR, Sciubba DM, Moller DJ, O'Shaughnessy BA, Li KW, *et al.* Maximizing the potential of minimally invasive spine surgery in complex spinal disorders. *Neurosurg Focus* 2008;25:E19.
 18. Beisse R. Endoscopic surgery on the thoracolumbar junction of the spine. *Eur Spine J* 2006;15:687-704.
 19. Holly LT, Schwender JD, Rouben DP, Foley KT. Minimally invasive transforaminal lumbar interbody fusion: Indications, technique, and complications. *Neurosurg Focus* 2006;20:E6.
 20. Kerr SM, Tannoury C, White AP, Hannallah D, Mendel RC, Anderson DG. The role of minimally invasive surgery in the lumbar spine. *Oper Tech Orthop* 2007;17:183-9.
 21. Oppenheimer JH, DeCastro I, McDonnell DE. Minimally invasive spine technology and minimally invasive spine surgery: A historical review. *Neurosurg Focus* 2009;27:E9.
 22. Esses SI, Botsford DJ, Kostuik JP. Evaluation of surgical treatment for burst fractures. *Spine (Phila Pa 1976)* 1990;15:667-73.
 23. Park Y, Ha JW, Lee YT, Sung NY. Cranial facet joint violations by percutaneously placed pedicle screws adjacent to a minimally invasive lumbar spinal fusion. *Spine J* 2011;11:295-302.
 24. Patel RD, Graziano GP, Vanderhave KL, Patel AA, Gerling MC. Facet violation with the placement of percutaneous pedicle screws. *Spine (Phila Pa 1976)* 2011;36:E1749-52.
 25. Knox JB, Dai JM 3rd, Orchowski JR. Superior segment facet joint violation and cortical violation after minimally invasive pedicle screw placement. *Spine J* 2011;11:213-7.
 26. Tsuang FY, Chen CH, Kuo YJ, Tseng WL, Chen YS, Lin CJ, *et al.* Percutaneous pedicle screw placement under single dimensional fluoroscopy with a designed pedicle finder-a technical note and case series. *Spine J* 2017;17:1373-80.
 27. Kraus M, Weiskopf J, Dreyhaupt J, Krischak G, Gebhard F. Computer-aided surgery does not increase the accuracy of dorsal pedicle screw placement in the thoracic and lumbar spine: A retrospective analysis of 2,003 pedicle screws in a level I trauma center. *Global Spine J* 2015;5:93-101.
 28. McAnany SJ, Overley SC, Kim JS, Baird EO, Qureshi SA, Anderson PA. Open versus minimally invasive fixation techniques for thoracolumbar trauma: A meta-analysis. *Global Spine J* 2016;6:186-94.