

Neglected Bilateral Facet Dislocation of the Cervical Spine with Intact Neurology: Reduction Technique

Abstract

Bilateral cervical facet dislocation is a serious injury that in majority cause neurologic deficit requiring prompt medical attention. Rarely, they retain normal neurology due to spontaneous decompression even though patients can have objective myelopathic or root compression signs. Neglected cases with normal neurology are uncommon with only few of them reported in the literature but their management is still a matter of debate. Here, we report a case of a 26-year-old female who had neglected bilateral facet dislocation with neck stiffness that was operated with posteroanterior approach with near-complete reduction and intact neurology. We describe the technique employed and discuss the literature.

Keywords: American spinal injury association E, bilateral facet dislocation, chronic, neglected, normal neurology

Introduction

Traumatic cervical dislocation injuries are flexion-distraction injuries. These can be unilateral or bilateral facet dislocation presenting with severe neurological deficit.^[1] Being an unstable injury, they demand emergent surgical intervention. Rarely, they have intact neurology, which is attributed to some auto-decompression mechanisms such as associated posterior bony fractures. Such patients can become chronic if they fail to seek medical attention or rarely a missed diagnosis.^[2] The management of these neglected cases is a matter of debate and surgically a mammoth challenge keeping in mind the risks involved.^[2,3] However, maintaining cervical stability and alignment is a major requisite in preventing progressive deformity and late-onset neurological deficit.^[4] Surgeons have different algorithms for their patients, and here, we describe our technique in such a unique situation.^[2,3,5]

Case Report

A 26-year-old female sustained an injury in the neck after fall from the bullock cart in her native village. She was treated with local quacks for some time but experienced stiffness of her neck for which

she presented to us after 4 months. When we examined, we found neck was stiff, motor and the sensory test revealed the American spinal injury association (ASIA) E grade neurology without radiculopathy or myelopathy signs. A cervical spine X-ray showed bilateral facet dislocation with almost toppling of C4 over the C5 vertebrae [Figure 1]. Computed tomography of her neck revealed bilateral perched facets with early callous between C4 and 5 body and no other associated fractures. Magnetic resonance imaging of her cervical spine revealed the absence of disc compression anteriorly through the spinal cord was displaced posteriorly. In view of normal neurology and absence of myelopathic/root compression signs, a thorough discussion was done regarding the mode of treatment. The patient was fully explained the risks involving surgery, including a postoperative deficit. After the patient consented for surgery, she was planned for the posterior first approach. No preoperative traction was applied. She was positioned prone with Gardner-Wells tongs in place and weights of 4 kg. Posterior exposure revealed a visible cord between the separated lamina of C4-5. Partial laminectomy of superior of C5 and inferior lamina of C4 was done along with facetectomy. Manual extension

**Mantu Jain,
Susanta Khuntia,
Bhaskar P Rao¹**

*Departments of Orthopedics
and ¹Anaesthesia, AIIMS,
Bhubaneswar, Odisha, India*

Address for correspondence:

*Dr. Mantu Jain,
106, Mahadev Orchid,
Cosmopolis Road, Dumduma,
Bhubaneswar - 751 019,
Odisha, India.
E-mail: montu_jn@yahoo.com*

Access this article online

Website: www.asianjns.org

DOI: 10.4103/ajns.AJNS_27_20

Quick Response Code:



This is an open access journal, and articles are distributed under the terms of the Creative Commons Attribution-NonCommercial-ShareAlike 4.0 License, which allows others to remix, tweak, and build upon the work non-commercially, as long as appropriate credit is given and the new creations are licensed under the identical terms.

For reprints contact: WKHLRPMedknow_reprints@wolterskluwer.com

How to cite this article: Jain M, Khuntia S, Rao BP. Neglected bilateral facet dislocation of the cervical spine with intact neurology: Reduction technique. *Asian J Neurosurg* 2020;15:773-6.

Submitted: 17-Feb-2020

Revised: 23-Apr-2020

Accepted: 03-May-2020

Published: 28-Aug-2020

maneuver was tried to reduce the dislocation under vision, which failed. Lateral mass screws were placed in C4-5 and compression was done, which reduced the dislocation up to 50% [Figure 2a]. The posterior wound was closed, and the patient flipped supine. An anterior approach was taken, and pins applied in C4-5 that appeared as a cross [Figure 2b]. Now, the pins distracter was placed, which made the pins parallel [Figure 2c]. Next, the discectomy was done [Figure 2d] and a cage was placed with bone graft *in situ* harvested locally from the inferior lip of the C4 body [Figure 2e]. Finally, a plate was applied to reinforce the construct and wound closed. Postoperatively the patient

was neuro-intact after extubation and shifted toward after overnight stay in intensive care. The postoperative check X-ray was satisfactory [Figure 3] and the patient was discharged subsequently with the Philadelphia collar. She is doing well.

Discussion

Delayed presentation (more than 3 weeks) of cervical facet dislocation is common in developing country like ours due to various reasons.^[3,5] However, neglected bilateral facet dislocation with normal neurology is extremely rare injuries to have been reported in the literature. Prabhat

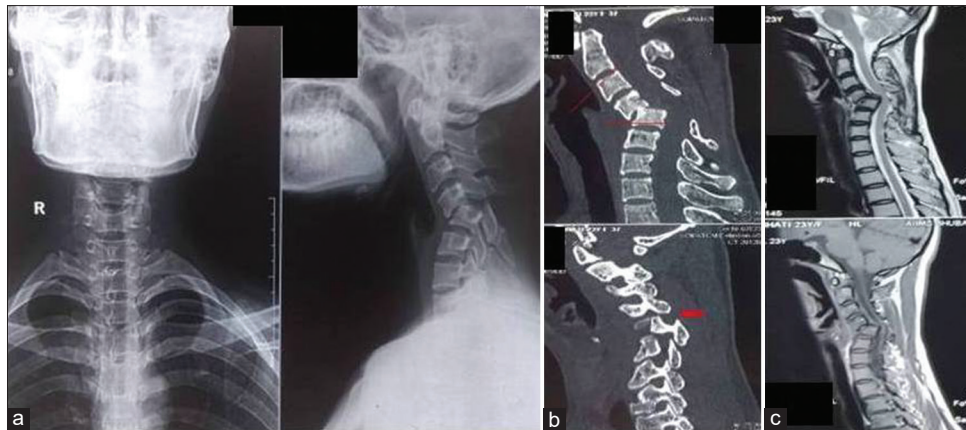


Figure 1: Preoperative imaging-X ray showing bilateral facet dislocation and listhesis of C4 over 5 (a), computed tomography scan showing perched facets-arrow marked (b) and magnetic resonance imaging showing an absence of disc compression anteriorly (c)

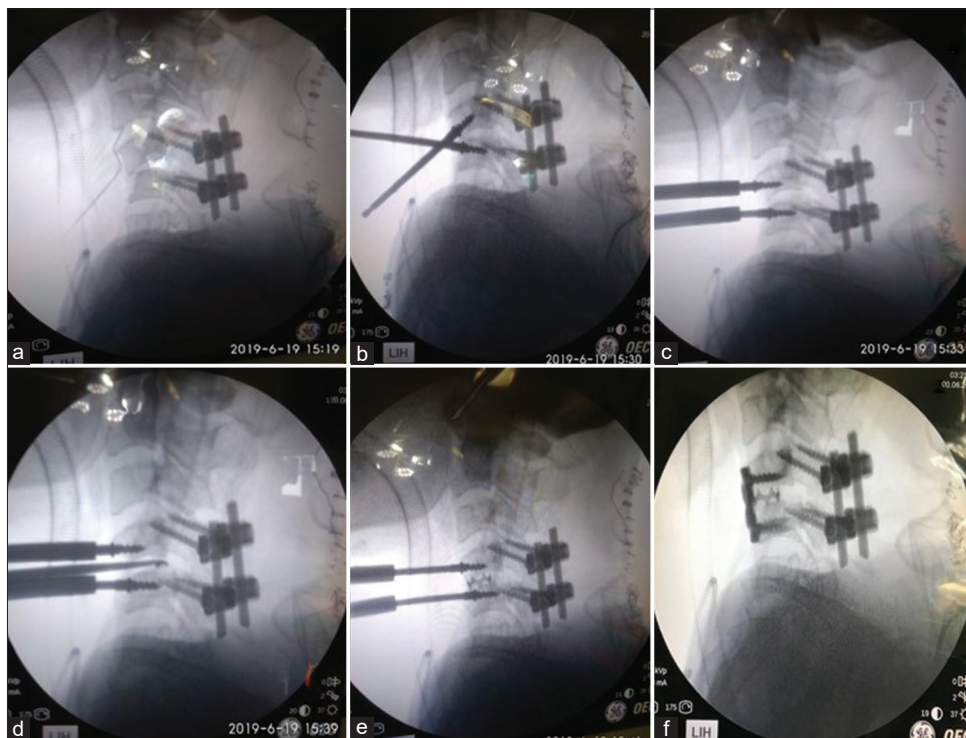


Figure 2: Intra-operative fluoroscopic picture of reduction technique. Fifty percent reduction achieved by posterior fixation in compression (a), pins placed in C4-5 which appears as cross (b), pins distracted and disc space opening up (c), anterior discectomy is done (d), cage placed in space with the bone graft (e), final pictures after anterior plating (f)

et al. reported 15 patients of chronic dislocation of which ten were bilateral, but only one was with ASIA E neurology (though had root injury) in their series.^[2] Because of rarity, the consensus regarding the optimal management of these patients is a matter of controversy.

Shah *et al.* has successfully managed 2 cases conservatively with “skillful negligence” as these undergo auto-fusion.^[6] Srivastava *et al.* reported such a case of neglected injury who had developed pain, deformity, and difficulty in gaze requiring surgery.^[4] Recent literature suggests more surgeons inclined to the surgery with fear of increasing kyphosis and late-onset neurology.^[7-10] Basu *et al.* and later Srivastava *et al.* proposed an algorithm for neglected dislocation in choosing the first approach depending on the prolapsed disc at an affected level that may be seen in 17%–20% of patients.^[3,5] Even in the absence of disc, a bony fusion starts in these neglected cases and Farooque *et al.* suggested to go anterior and remove this bony bridge followed by posterior and finally by anterior.^[11] Jain *et al.* advocated a posterior approach (using spinal wiring) followed by anterior and return to posterior for more rigid fixation if required.^[12]

The role of preoperative traction in reduction is also disputed. Allen *et al.* have found that only 20% of patients attain reduction by means of traction post 72 h.^[1] However, Basu *et al.* and Srivastava *et al.* advocate the use of preoperative traction as they have tasted some success and saved approach and time in few patients.^[3,5] Most authors with >10 weeks have not used preoperative tractions.^[8-10] Mishra *et al.* have found the fibrous fusion of facets intraoperatively that were not visible radiographically in 4 cases that had delayed presentation up to 10 weeks.^[7]

Authors imply various surgical strategies and the optimal is the one that has less number of approaches requiring less turning of patients and less time-consuming. Payer and Tessitore used the triple postant-post approach in their patient.^[8] Jain *et al.* also describe a case, wherein

they did the postant-post technique.^[12] After they failed to reduce posteriorly, they did interspinous wiring and came in anteriorly to manipulate, reduce, and fixing anteriorly, then going back again for rigid global fusion. The thought that lateral mass fixation may hinder anteriorly manipulated reduction after a failed posterior (post facet excision procedure) has prevented surgeons from trying this. In our case also, once the facets were excised with decompression accomplished, we attempted reduction but failed. However, we tried to pull up the listhetic vertebrae by compression force over lateral mass screws and achieved 50% reduction. When we went anteriorly and used pins distracter, the rigid posterior fixation allowed us to have “controlled aggression” and realign the spine. This helped us in operating a neurologically intact patient without any catastrophe.

Conclusion

Posterior shortening and rigid fixation and anterior controlled distraction is an effective method of achieving a reduction in a neurological intact patient with chronic bilateral facet dislocation.

Declaration of patient consent

The authors certify that they have obtained all appropriate patient consent forms. In the form the patient(s) has/have given his/her/their consent for his/her/their images and other clinical information to be reported in the journal. The patients understand that their names and initials will not be published and due efforts will be made to conceal their identity, but anonymity cannot be guaranteed.

Financial support and sponsorship

Nil.

Conflicts of interest

There are no conflicts of interest.

References

- Allen BL Jr., Ferguson RL, Lehmann TR, O'Brien RP. A mechanistic classification of closed, indirect fractures and dislocations of the lower cervical spine. *Spine (Phila Pa 1976)* 1982;7:1-27.
- Prabhat V, Boruah T, Lal H, Kumar R, Dagar A, Sahu H. Management of post-traumatic neglected cervical facet dislocation. *J Clin Orthop Trauma* 2017;8:125-30.
- Srivastava SK, Aggarwal RA, Bhosale SK, Nemade PS. Neglected dislocation in sub-axial cervical spine: Case series and a suggested treatment protocol. *J Craniovertebr Junction Spine* 2016;7:140-5.
- Srivastava A, Soh RC, Ee GW, Tan SB, Tow BP. Management of the neglected and healed bilateral cervical facet dislocation. *Eur Spine J* 2014;23:1612-6.
- Basu S, Malik FH, Ghosh JD, Tikoo A. Delayed presentation of cervical facet dislocations. *J Orthop Surg (Hong Kong)* 2011;19:331-5.
- Shah K, Gadiya A, Nene A. Autostabilisation of neglected high grade fracture dislocation in cervical spine. *J Craniovertebr*

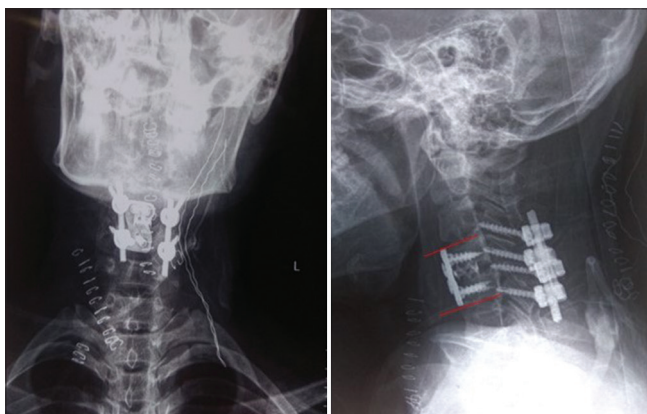


Figure 3: Postoperative check X-ray showing near reduced listhesis and reduction of kyphosis (between red lines)

- Junction Spine. 2018;9:274-6.
7. Mishra A, Agrawal D, Singh PK. Delayed presentation of post-traumatic bilateral cervical facet dislocation: A series of 4 cases. *Neurol India* 2014;62:540-2.
 8. Payer M, Tessitore E. Delayed surgical management of a traumatic bilateral cervical facet dislocation by an anterior-posterior-anterior approach. *J Clin Neurosci* 2007;14:782-6.
 9. Hassan MG. Treatment of old dislocations of the lower cervical spine. *Int Orthop* 2002;26:263-7.
 10. Bartels RH, Donk R. Delayed management of traumatic bilateral cervical facet dislocation: Surgical strategy. Report of three cases. *J Neurosurg* 2002;97:362-5.
 11. Farooque K, Khatri K, Gupta B, Sharma V. Management of neglected traumatic bilateral cervical facet dislocations without neurological deficit. *Trauma Mon* 2015;20:e18385.
 12. Jain AK, Dhammi IK, Singh AP, Mishra P. Neglected traumatic dislocation of the subaxial cervical spine. *J Bone Joint Surg Br* 2010;92:246-9.