

Endoscopic Endonasal Resection of the Odontoid Process in a Patient with Chronic Injury of the C1 Transverse Ligament

Abstract

Atlas dislocation after transverse ligament injury is one of the most rare types of trauma to the upper cervical level. If magnetic resonance imaging of the craniovertebral junction reveals the Kassam line passing through the cervix of the odontoid process, a transnasal approach can be used for surgical treatment. Here, we present a case in which an endoscopic endonasal approach was used to treat chronic traumatic transligamentous atlas dislocation. A 26-year-old male underwent two-stage surgical treatment; during the first stage, posterior decompression and fixation were performed under halo immobilization. In the second stage, a transnasal endoscopic approach to the odontoid process was used. A transnasal approach permitted complete decompression of the medulla oblongata and facilitated early extubation of the patient without any postoperative complications such as respiratory or pharyngopalatine deficiency. The patient was discharged in good condition 9 days after the surgery.

Keywords: Craniovertebral endoscopy, endonasal resection, Kassam line, odontoid resection, transligamentous atlas dislocations

Introduction

Atlas dislocation after transverse ligament injury is one of the most rare types of trauma to the craniovertebral level. One method of surgical treatment involves ventral decompression through transnasal resection of the odontoid process. Use of a transnasal approach to access the anterior structures of the upper neck was first reported in an anatomical study by Alfieri *et al.* in 2002.^[1] The first craniovertebral junction decompression in medical practice was performed by Kassam *et al.* in 2005.^[2] Yet, a high level of performance difficulty, the need for specific instruments, and highly restrictive surgical indications have prevented the widespread implementation of this method. Here, we report a case of chronic traumatic transligamentous atlas dislocation that was successfully treated using a transnasal approach.

Case Report

A 26-year-old male was injured during a fire show performance. After suffering severe burns, he fell and hit his head. Symptoms of injury manifested 6 months later when the patient performed a sudden

head movement and began to display severe tetraparesis. Magnetic resonance imaging (MRI) at this time revealed dislocation of the anterior transligamentous atlas dislocation [Figure 1].

The patient's burns were treated before admission for surgical treatment. Fibrous scarring over the burn areas resulted in rigid fixation of the head and cervical vertebral column into an abnormal position [Figure 2].

Functional radiography of the cervical spine indicated the feasibility of a partially closed reduction of the atlas dislocation. Considering the location of the invaginated odontoid process above the hard palatine line [Figure 1], a transnasal endoscopic odontoid process resection was selected for surgical treatment.

The patient underwent a two-stage surgical treatment. During the first stage of treatment, posterior decompression and fixation were performed under halo immobilization. In the second stage of treatment, an endoscopic approach to the odontoid process was performed. The anterior half ring of the C1 vertebra was exposed and the upper part of the half ring

**Andrey Grin,
Ivan Lvov,
Ivan Godkov,
Aleksy Sytnik,
Anton Kordonskiy,
Vladimir Smirnov**

*Department of Neurosurgery,
Sklifosovsky Research Institute
of Emergency Care, Moscow,
Russia*

Address for correspondence:

*Dr. Ivan Lvov,
B. Suharevskaya Pl., 3,
Moscow 107945, Russia.
E-mail: dr.speleolog@gmail.com*

Access this article online

Website: www.asianjns.org

DOI: 10.4103/ajns.AJNS_366_16

Quick Response Code:



How to cite this article: Grin A, Lvov I, Godkov I, Sytnik A, Kordonskiy A, Smirnov V. Endoscopic endonasal resection of the odontoid process in a patient with chronic injury of the C1 transverse ligament. *Asian J Neurosurg* 2018;13:1179-81.

This is an open access journal, and articles are distributed under the terms of the Creative Commons Attribution-NonCommercial-ShareAlike 4.0 License, which allows others to remix, tweak, and build upon the work non-commercially, as long as appropriate credit is given and the new creations are licensed under the identical terms.

For reprints contact: reprints@medknow.com

was resected. The odontoid process was located at 2 cm from the posterior edge of the C1 arc. An approach to the odontoid process of the C2 vertebra was performed under radiographic guidance. The odontoid process and upper part of the C2 vertebral body were identified and cleaned. The odontoid process and apical ligament were resected using a surgical drill and Kerrison cutters [Figure 3a and b]. Low-intensity cerebrospinal fluid flow from a dural tear was observed after resection of the odontoid process apex, and apparent pulsation of dura was observed after the decompression was completed [Figure 3c]. Dural repair was performed using a hemostatic sponge and biological glue. The glue was also used for fixation of the mucous membrane flap [Figure 3d]. Postoperative MRI of the

craniocervical junction is shown in Figure 4. There were no postoperative complications, and the patient was discharged in good condition 9 days after the surgery.

Discussion

Decompression by restoration of the physiological structure of the craniocervical junction using the halo correction system is considered to be a minimally invasive treatment option for the traumatic compression of neural structures. Yet, in many cases, the reduction of chronic or older injuries and dislocations is unsuccessful due to fibrous scarring and significant fixation of the dislocated vertebrae into an incorrect position.^[3,4] If halo repositioning is unsuccessful, a submandibular, transoral, or transnasal approach can be used for the ventral decompression of neural structures.^[5,6]

The main criterion for selecting an approach for ventral decompression is the location of the C2 vertebra in relation to the nasopalatine (Kassam) line.^[7,8] If the axis is located above this line (A-type), a transnasal odontoidectomy should be performed. If the Kassam line passes through the base of

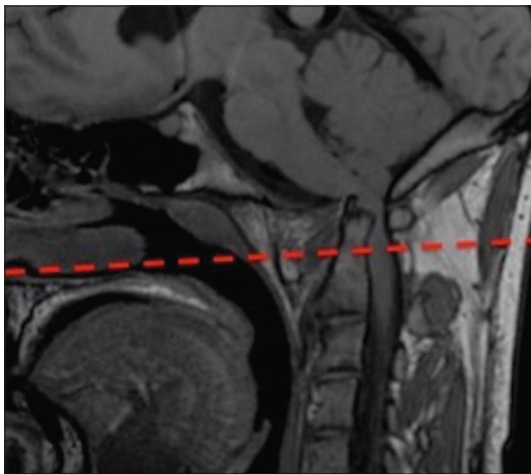


Figure 1: Magnetic resonance imaging of the patient. An increase of the Cruevillier space to 18 mm is shown. The medulla oblongata compressed by the odontoid process, occipital bone, and arc of the C1 vertebra. The nasopalatine line extended through the upper edge of the C1 arc and odontoid process (marked with a dotted line)

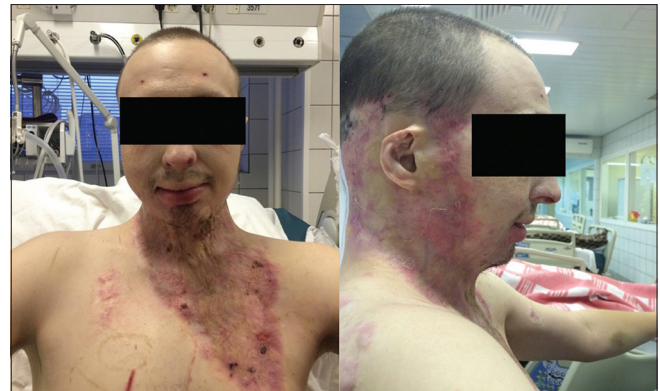

Figure 2: Appearance of the patient. Fibrous scarring affected burn areas on the head, neck, and thorax, causing deformity

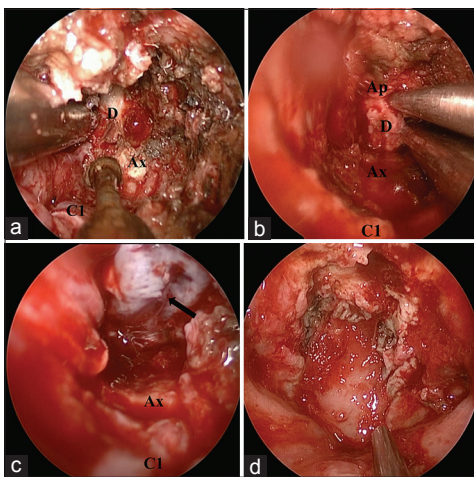


Figure 3: Intraoperative images from the endoscope camera. (a) Resection of the odontoid process cervix using a diamond drill. (b) Resection of the apical ligament using Kerrison cutters. (c) The completed decompression showing sagging of the dura; the arrow indicates a dural tear. (d) Replacement of the mucous membrane flap. Ap, apical ligament; Ax, C2 body; D, odontoid process

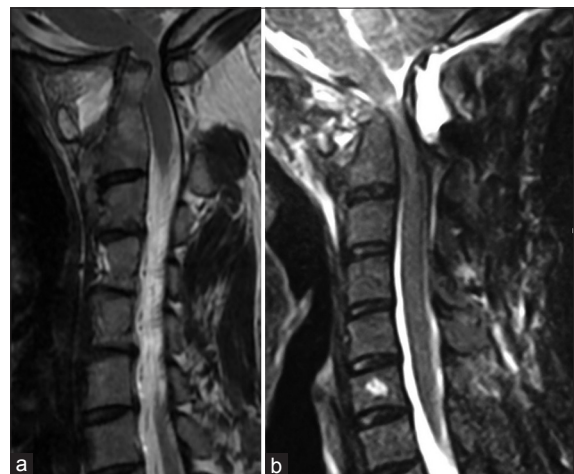


Figure 4: (a) Sagittal magnetic resonance images of the cervical spine before surgical treatment. (b) Sagittal magnetic resonance images of the cervical spine after surgical treatment

the odontoid process (B-type), either a transnasal or transoral approach can be used. If this line projects above the apex of odontoid process (C-type), then a transoral approach is optimal.

In the present case report, the patient exhibited conventional chronic dislocation of the C1 vertebra that had developed after injury of the transverse portion of the cruciate ligament, leading to progressive migration of the odontoid process to the foramen magnum. Despite a 6-month period between the time of injury and the time of surgical intervention, a solid interfibrous complex had not developed between the dislocated structures, as confirmed by functional radiography showing significant mobility at the C1 and C2 levels. Yet, repositioning using the halo system was unsuccessful due to significant scarring of the skin on the neck that restricted the patient's range of motion. Intraoperative reduction of the odontoid process invagination using occipital-spinal fusion screws was also ineffective. MRI of the craniovertebral junction [Figure 1] revealed that the Kassam line passed through the cervix of the odontoid process (B-type) such that a transoral, transnasal, or combination approach was indicated; however, a highly restricted range motion for mouth opening (i.e., not more than 2 cm) due to burn scarring precluded the use of a transoral approach. A transnasal approach allowed complete decompression of the medulla oblongata in the absence of any postoperative neurological impairment and facilitated early extubation of the patient without any complications including respiratory or pharyngopalatine deficiency.^{9,10}

Conclusion

Transnasal endoscopic odontoid resection is an alternative to transoral decompression for the treatment of craniovertebral injury when closed or combined reduction is ineffective. The absence of tongue and pharynx edema, a lower risk of wound contamination by the flora of the oral cavity, and the avoidance of soft palate retraction make transnasal decompression, a preferential method for treatment if the location of the compressing structure is above or at the level of the nasopalatine (Kassam) line.

Declaration of patient consent

The authors certify that they have obtained all appropriate patient consent forms. In the form the patient has given his consent for his images and other clinical information to be reported in the journal. The patient understand that his name and initials will not be published and due efforts will

be made to conceal his identity, but anonymity cannot be guaranteed.

Acknowledgments

We would like to thank Editage (www.editage.com) for English language editing.

Financial support and sponsorship

Nil.

Conflicts of interest

There are no conflicts of interest.

References

1. Alfieri A, Jho HD, Tschabitscher M. Endoscopic endonasal approach to the ventral cranio-cervical junction: Anatomical study. *Acta Neurochir (Wien)* 2002;144:219-25.
2. Kassam AB, Snyderman C, Gardner P, Carrau R, Spiro R. The expanded endonasal approach: A fully endoscopic transnasal approach and resection of the odontoid process: Technical case report. *Neurosurgery* 2005;57 1 Suppl:E213.
3. Dickman CA, Greene KA, Sonntag VK. Injuries involving the transverse atlantal ligament: Classification and treatment guidelines based upon experience with 39 injuries. *Neurosurgery* 1996;38:44-50.
4. Nekrasov M, Lvov I, Grin A. Surgical treatment of patients with fractures of the C2 vertebra odontoid process in the intermediate and late periods of injury. *Neurosurgery (Russia)* 2013;1:14-21.
5. Baird CJ, Conway JE, Sciubba DM, Prevedello DM, Quiñones-Hinojosa A, Kassam AB. Radiographic and anatomic basis of endoscopic anterior craniocervical decompression: A comparison of endonasal, transoral, and transcervical approaches. *Neurosurgery* 2009;65 6 Suppl:158-63.
6. Dasenbrock HH, Clarke MJ, Bydon A, Sciubba DM, Witham TF, Gokaslan ZL, *et al.* Endoscopic image-guided transcervical odontoidectomy: Outcomes of 15 patients with basilar invagination. *Neurosurgery* 2012;70:351-9.
7. El-Sayed IH, Wu JC, Ames CP, Balamurali G, Mummaneni PV. Combined transnasal and transoral endoscopic approaches to the craniovertebral junction. *J Craniovertebr Junction Spine* 2010;1:44-8.
8. Zenga F, Villaret AB, Fontanella MM, Nicolai P. Endoscopic transnasal odontoidectomy using ultrasonic bone curette: Technical case report. *Neurol India* 2013;61:69-72.
9. Fang CH, Friedman R, Schild SD, Goldstein IM, Baredes S, Liu JK, *et al.* Purely endoscopic endonasal surgery of the craniovertebral junction: A systematic review. *Int Forum Allergy Rhinol* 2015;5:754-60.
10. Tubbs RS, Demerdash A, Rizk E, Chapman JR, Oskouian RJ. Complications of transoral and transnasal odontoidectomy: A comprehensive review. *Childs Nerv Syst* 2016;32:55-9.