

A Rare Case of *Achromobacter* Species Subdural Empyema and Brain Abscess in an Adult Patient with Hematologic Malignancy

Sir,

Focal intracranial infections remain a major source of morbidity and are often life-threatening conditions. Rapid recognition and early neurosurgical intervention combined with appropriate antimicrobial treatment give the best chances of a favorable prognosis.^[1] We describe a rare case of a subdural empyema (SDE) and adjacent cerebral abscess from *Achromobacter* species in a young patient with hematologic malignancy.

A 39-year-old Caucasian female with multiple myeloma, was admitted in the emergencies with fever, headache, vomiting, gait disturbance, and seizures for 4 days. Neurological examination revealed a left hemiparesis, nuchal

rigidity, and positive Babinski sign. Pre- and post-contrast computed tomography and magnetic resonance imaging brain scans were suggestive of right frontal SDE and adjacent early capsule formation brain abscess with perifocal edema [Figure 1a-d].

The patient underwent right frontal craniectomy and complete removal of SDE and cerebral abscess [Figure 2]. *Achromobacter xylosoxidans* colonies were identified from blood samples and intracranial pus cultured on MacConkey agar. The patient received a combination of Piperacillin– Tazobactam and trimethoprim/sulfamethoxazole (TMP/SMX) intravenously for 6 weeks and she gradually recovered. She was also given oral TMP/SMX for a further 2 months, and at the time of writing this study, she is still well 1½ years after completion of therapy [Figure 3].

Achromobacter species is often isolated from aqueous environments but is rarely recognized as a human pathogen. However, it can cause serious infections in immunosuppressed patients. *Achromobacter* infections in patients with cancer, and especially in those who have underlying hematologic malignancies, usually are seen as uncomplicated hematogenous infections and are seldom accompanied by a secondary suppurative focus of infection.^[2,3] Isolation of *Achromobacter xylosoxidans* from intracranial space was an unusual finding and to the

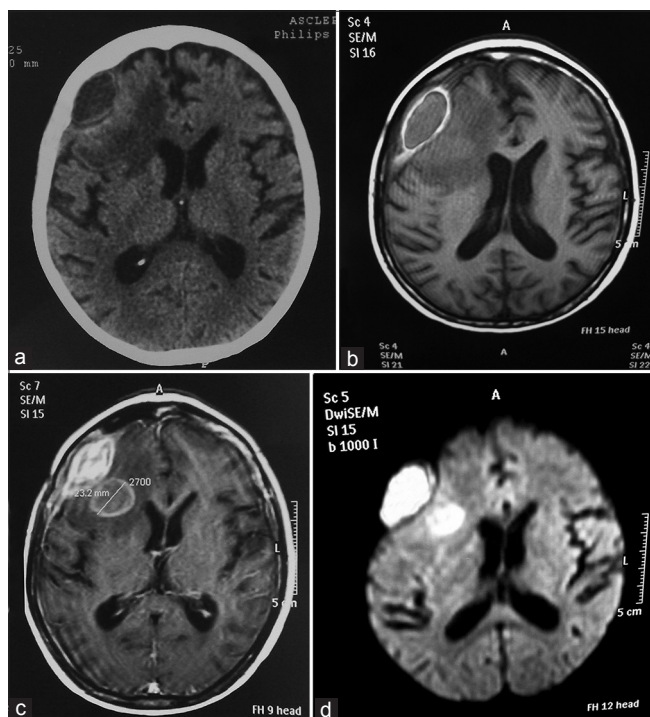


Figure 1: (a) Brain computed tomography scan without contrast, and (b) T1 – weighted postcontrast image reveals a hyperdense to cerebrospinal fluid right frontal subdural collection with clear capsule formation, and an adjacent intraparenchymal lesion of low signal with considerable edema. (c) Fluid-attenuated inversion recovery postcontrast sequence demonstrates a densely enhancing extraaxial lesion and a well-defined ring enhancing brain lesion. (d) On diffusion-weighted image, the core of the subdural and brain lesion has typically markedly hyperintense signal (restricted diffusion)

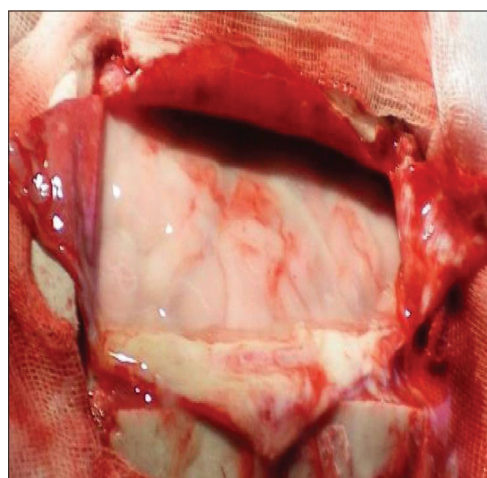


Figure 2: Purulent material into the subdural space after opening of the dura mater and the subdural empyema capsule

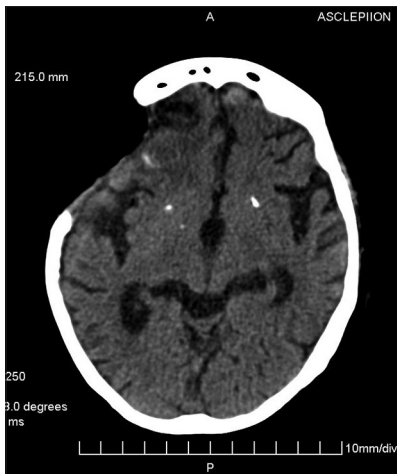

Figure 3: Postcontrast computed tomography scan 3 weeks after surgical procedure reveals the intracranial infections decreased

best of our knowledge is the first case that *Achromobacter xylosoxidans* implicated for an intracranial abscess formation in an adult patient who had not undergone any prior neurosurgical procedure.

Declaration of patient consent

The authors certify that they have obtained all appropriate patient consent forms. In the form the patient(s) has/have given his/her/their consent for his/her/their images and other clinical information to be reported in the journal. The patients understand that their names and initials will not be published and due efforts will be made to conceal their identity, but anonymity cannot be guaranteed.

Financial support and sponsorship

Nil.

Conflicts of interest

There are no conflicts of interest.

Aristedis Rovlias

Department of Neurosurgery, Asclepeion General Hospital of Athens, Voula, Athens, Greece

Address for correspondence:

Dr. Aristedis Rovlias,
Department of Neurosurgery, Asclepeion General Hospital of Athens,
1 Vasileos Pavlou Street, 16 673, Voula, Athens, Greece.
E-mail: arovlias@yahoo.com

References

1. Kastrup O, Wanke I, Maschke M. Neuroimaging of infections. *NeuroRx* 2005;2:324-32.
2. Shie SS, Huang CT, Leu HS. Characteristics of *Achromobacter xylosoxidans* bacteremia in Northern Taiwan. *J Microbiol Immunol Infect* 2005;38:277-82.
3. Aisenberg G, Rolston KV, Safdar A. Bacteremia caused by *Achromobacter* and *Alcaligenes* species in 46 patients with cancer (1989-2003). *Cancer* 2004;101:2134-40.

This is an open access journal, and articles are distributed under the terms of the Creative Commons Attribution-NonCommercial-ShareAlike 4.0 License, which allows others to remix, tweak, and build upon the work non-commercially, as long as appropriate credit is given and the new creations are licensed under the identical terms.

Access this article online	
Quick Response Code: 	Website: www.asianjns.org
	DOI: 10.4103/ajns.AJNS_373_19

How to cite this article: Rovlias A. A rare case of *Achromobacter* species subdural empyema and brain abscess in an adult patient with hematologic malignancy. *Asian J Neurosurg* 2020;15:245-6.
Submission: 29-12-2019 **Accepted:** 24-01-2020 **Published:** 25-02-2020
 © 2020 Asian Journal of Neurosurgery | Published by Wolters Kluwer - Medknow