

Customized Cost-Effective Polymethyl-Methacrylate Cranioplasty Implant Using Three-Dimensional Printer

Abstract

There is no doubt that many synthetic materials used in cranioplasty have given good result regarding patient's calvarial shape. However, the use of these materials is costly to the patient and requires complex intraoperative process. There has been a long history regarding the use of acrylic bone cement called as polymethyl-methacrylate (PMMA) as an implant due to its desirable properties. Here, we present three cases of simple, cost effective manually sculpted calvarial defect using three-dimensional (3D) printer. Sharing the achievement and challenges, we want to focus that the 3D customized implant of PMMA can be used as bone substitute.

Keywords: Bone cement, cranioplasty, polymethyl-methacrylate prosthesis, three-dimensional printing

Introduction

Regarding the use of new expensive armamentarium and prosthetic products, we still have to face a lot of challenges.^[1] Here, we just cannot be the only treating neurosurgeon, but in each step of our treatment we must be concerned about the financial burden that we may give to the family members and the patient.^[2]

After craniectomy, the bone flaps are commonly placed in the abdominal wall of the patients which requires additional surgery or they are preserved by deep-freezing, however they are often unusable at the moment of re-implantation, thus leading to the need for artificial bone substitutes.^[3] Cranioplasty technique using polymethyl-methacrylate (PMMA) is the common method of reconstructing lost cranial bone. In such situation, where patient specific implant is needed, the use bone cement made of three-dimensional (3D) printer customized implant. These implant would be cost-effective not compromising the quality needed for such implant. By using PMMA casting method, we obtained a cranial implant that fits well into the anatomical defect.^[4] With the use of 3D-based reconstruction of cranial defect it ensures better esthetic looks. This

preoperatively created bone prevents the chance of tissue necrosis due to exothermic hardening and this helps in reducing the intraoperative procedural time as it would take a much longer time if the surgeon had to manually prepare the missing bone in the operation theatre table and perfect fitting cannot be achieved.^[5]

Here, we present first three cases with initial experience and share the knowledge about the preparation of this implant. Operative and postoperative outcome, patient's satisfaction, and complications are also discussed.

Patient Selection and Preparation

Case 1

A 44-year-old male patient who underwent right fronto-temporal parietal decompressive craniotomy at other institute for acute subdural hematoma due to fall injury under influence of alcohol 7 months back presented to us for cranioplasty. The bone was cryopreserved. However the quality of bone was poor. The bone was foul smelling and greenish colored. The defect measured approximately 11 cm × 8 cm. Since the autologous cranioplasty was not possible, the defect needs to be reconstructed with implantable material. Hence, a 3D

**Sambardhan Dabadi,
Raju Raj Dhungel,
Upama Sharma¹,
Dinuj Shrestha¹,
Pritam Gurung¹,
Resha Shrestha¹,
Basant Pant¹**

Departments of Biomedical Engineering and ¹Neurosurgery, Annapurna Neurological Institute and Allied Sciences, Maitighar, Kathmandu, Nepal

Address for correspondence:
Dr. Upama Sharma,
Department of Neurosurgery,
Annapurna Neurological
Institute and Allied Sciences,
Maitighar, Kathmandu, Nepal.
E-mail: upama43@gmail.com

Access this article online

Website: www.asianjns.org

DOI: 10.4103/ajns.AJNS_441_20

Quick Response Code:



This is an open access journal, and articles are distributed under the terms of the Creative Commons Attribution-NonCommercial-ShareAlike 4.0 License, which allows others to remix, tweak, and build upon the work non-commercially, as long as appropriate credit is given and the new creations are licensed under the identical terms.

For reprints contact: WKHLRPMedknow_reprints@wolterskluwer.com

How to cite this article: Dabadi S, Dhungel RR, Sharma U, Shrestha D, Gurung P, Shrestha R, *et al.* Customized cost-effective polymethyl-methacrylate cranioplasty implant using three-dimensional printer. Asian J Neurosurg 2021;16:150-4.

Submitted: 18-Sep-2020 **Revised:** 11-Jan-2021

Accepted: 26-Jan-2021 **Published:** 20-Mar-2021

reconstruction of computed tomography (CT) image was used to create a PMMA implant of same size and contour with symmetrical opposite (left) side [Figure 1].

Case 2

A 65-year-old male presented with progressively increasing swelling in the right parietal region for 2 months. His CT head showed a well-defined space occupying lesion (SOL) in the right parietal bone with focal erosion involving both the outer and inner table having extra and intracranial extension and in extradural space collectively measuring 4.2 cm × 2.7 cm × 4.1 cm. Another similar character SOL in the extradural space at Right Fronto-Parietal area measuring 1.3 cm × 0.8 cm × 1.5 cm with focal erosion in the inner table but intact frontal outer table.

As the patient was planned to operate for the removal of this intra-osseous tumor and since his bone had multiple defects, an implantable bone covering both the lesion, of about 10 cm × 6 cm was predesigned with 3D reconstruction of the CT image [Figure 2].

Case 3

A 24-year-old female presented with the cranial defects at right parietal region. She was operated at other center 1 year back for right sided intracerebral hematoma but due to brain swelling, bone flap was not kept. The CT scan was performed and a 3D-reconciled image was acquired. The

defect measured approximately 8 cm anterior-posteriorly and 4 cm cranial-caudally so, implantable bone from bone cement was made [Figure 3].

Molding technique

The preparation of the implant was completed in two stages, first the 3D model of the missing surface was created, followed by molding the model to design a bone made of PMMA [Figure 4].

Image acquisition

Initially, a CT scan was done to acquire the 3D model of the patient. With a slice thickness of 1 mm and exposed at 130KV, the image from level upper jaw to the vertex was acquired. The acquired image was in Digital Imaging and Communications in Medicine (DICOM) format. The multi-planar image was then converted to 3D model by 3D volume rendering technique, which was assisted by the commercially available software “Radiant DICOM viewer.”

Prototyping the model

With the same software, the model was manipulated and the outline of the missing part was traced out, which was used to extract the same outline from the other half of the skull. Skull being bilaterally symmetrical, it was possible to achieve the exact missing surface. However the contour did not match our requirement. So, for this the model was mirrored with another software “Meshmixer”. Eventually,

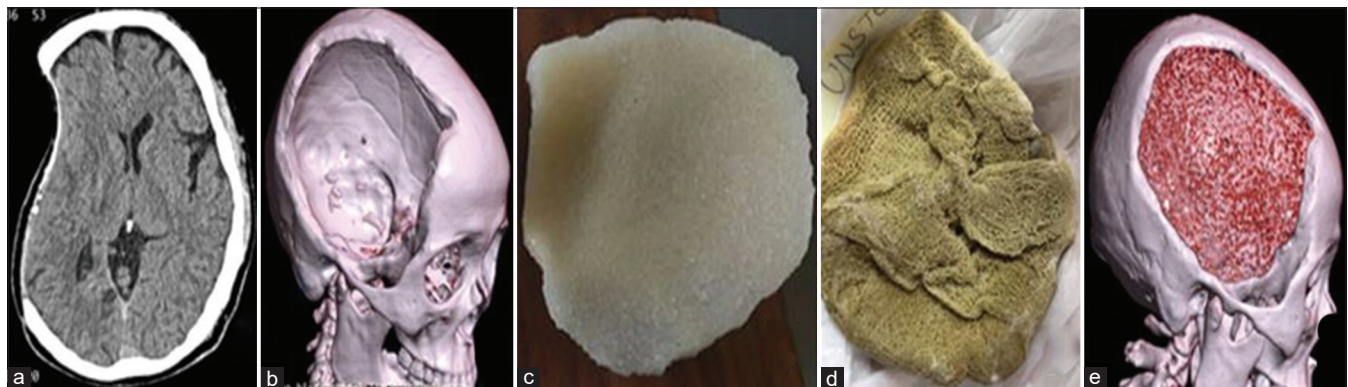


Figure 1: Preoperative axial 1-mm computed tomography data (a) being converted to three-dimensional image showing the cranial defect (b) with development of implant model (c). Infected autologous bone (d). Postoperative three-dimensional computed tomography with prosthesis placement (e)

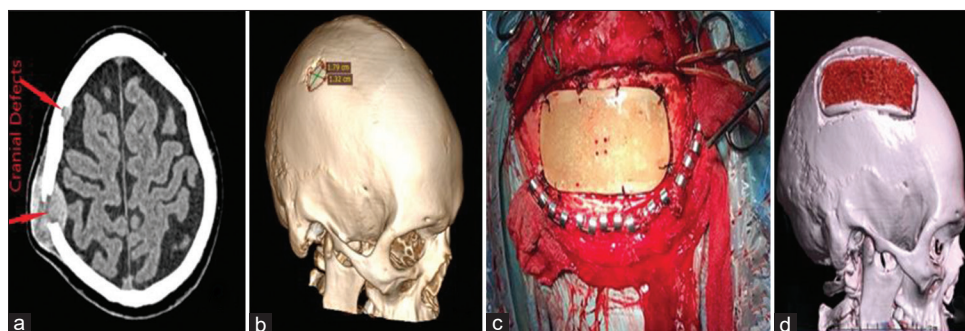


Figure 2: Preoperative axial (a) and three-dimensional image (b) showing the cranial defect due to parietal bony tumor but frontal one has intact outer table with intraoperative (c) and intraoperatively prosthesis placement (d) which fits the defect restoring the normal skull shape

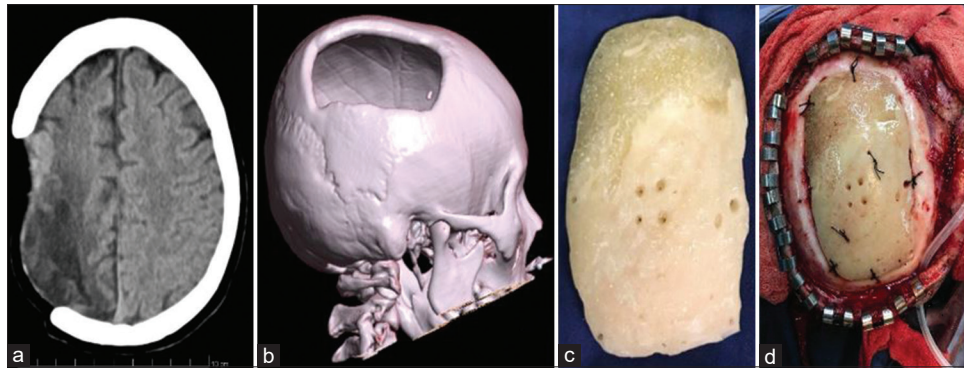


Figure 3: Preoperative computed tomography (a) showing cranial defect with three-dimensional printed (b) bone cement prosthesis (c) and well fitted intraoperatively (d)

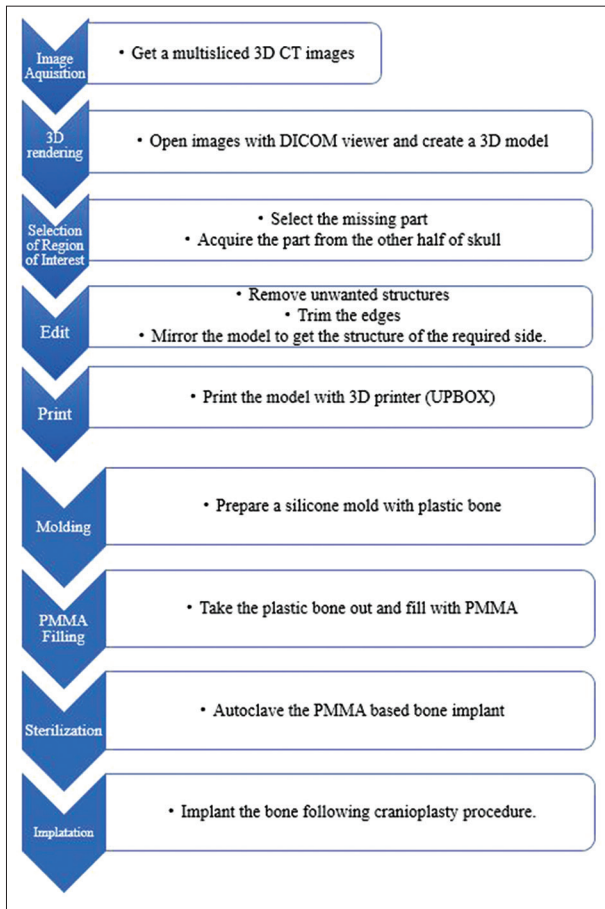


Figure 4: Steps in creating the three-dimensional model and molding

a structure with same surface as of missing region and contour symmetrical to other half was achieved. Finally, a stereolithographic model (STL) of the missing bone was designed [Figure 5].

Three-dimensional printing

Once a STL file was created, the model was reviewed for its accuracy of the dimension and edges. After ensuring the accuracy, the model was then printed using a UPBOX 3D printer. The bone structure made of acrylonitrile butadiene styrene (ABS) plastic was obtained [Figure 6].

Molding

As ABS plastic is not the material to be used as an implant. So, to create a bone made up of PMMA, it was required to mold the 3D printed bone. Silicone was used as mold material. Liquid silicone rubber was mixed with propionic acid, hardener for silicon, and stirred continuously to remove any air bubble trapped inside. Once the silicone started to harden, it was poured in a box keeping the 3D-printed bone at the center, silicon mold was created, which took almost 12 h to harden and produce a perfect mold as required.

Polymethyl-methacrylate filling

Once the mold was ready, it was cut into two halves and the plastic bone was removed. Now, the PMMA bone cement mixture was created. PMMA is available in powder and is required to mix with the hardening liquid, benzoyl peroxide and radio opacifier (contrast material), zirconium di-oxide (ZrO_2). The mixture was then added with gentamycin, an antibiotic to prevent any bacterial growth. Upon mixing the soft texture slowly converted to mud like semi-hardened texture. The semi-solid mixture was then poured into the silicone mold and left over for 15–20 min to harden. After 20 min, PMMA took the required shape.

The bone implant was taken out and few modification at the edges was carried out. Few holes were drilled so that it would be easier while fixing the implant with the cranial bone. Finally, the bone was autoclaved at $121^\circ C$ at 15 pascal per square inch (Psi) for 30 min. The autoclaved bone was ready to implant.

Surgical techniques

Under general anesthesia, attempts were made to reuse the same previous scar in two cases of cranioplasty and the tissue was detached, in an attempt to prepare a galeal flap to use to cover the alloplastic material. However, in the case of bony calvarial tumor, box flap made using navigation to make sure that our implant does fit to the defect we will be creating. Any unevenness in implant and bone was trimmed using bone cutter with margin

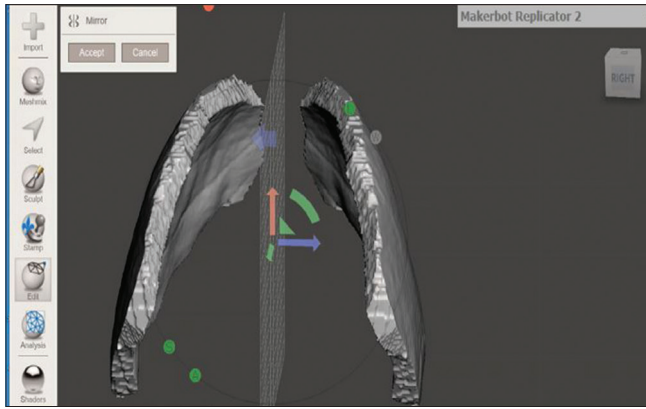


Figure 5: Creating the mirror of bone from the other side

smoothing. After the exposure of bone defect, these custom made implants were applied. The plates were then fixed with 1–0 silk sutures to the bony margins of the defect to provide stability. Subgaleal romo-vac drain kept in all the cases and then wound closed.

Results

These 3D-based PMMA bone implant was exact fit to the cranial defect, the implant also ensured almost symmetrical skull outline. Surgical complications like infection at the implant site or seroma formation was not reported, which too depicts the success of the surgery. Postoperative CT scan was taken on 10th postoperative day after suture removal to see the symmetry restored by the reconstruction. In our first case, there was noticeable fluid collection in postoperative CT scan between prosthesis and dura. However, no surgical intervention required and was spontaneously resolved. However, from this case dural hitch to implant was well secured in other two cases. All of the patients were satisfied with the result obtained. In postoperative 3D CT scan, implants have well covered the rim of defect with good contour. In terms of total hospital costs, there was low financial burden to the family members as compared using other company manufactured implants.

Discussion

Depending on the location of craniectomies, bony defect require coverage for protection of underlying brain, cosmetic, and overall patient satisfaction.^[6] The ideal artificial material for reconstruction of an osseous defect will be material with the same properties as bone. This material should be fully biocompatible, strong, inert, easy to work with, malleable, light weight, ideally relatively inexpensive and should allow an unhindered radiological evaluation after implantation.^[7]

The use of company manufactured cranioplasty implants such as titanium mesh, ceramics and polymers are costly for most of the patients belonging to middle and lower socio-economic groups.^[8] To minimize this challenge, in most of the cases who had been treated with decompressive




Figure 6: Three-dimensional printed bone made of acrylonitrile butadiene styrene

craniectomy for various reasons, the trend is to use the same bone for cranioplasty. Despite the simplicity of cranioplasty, there are number of complications including infection and aseptic bone resorption.^[9] In case of infected bone flap of any susceptibility of bone being infected, we store the bone flap in freezer as cryopreservative method. Furthermore, many patients, who were previously operated at other center and no subcutaneous pocket storage or availability of cryopreserved bone flap present to us. Also, it cannot always be used due to infection, fragmentation, bone resorption or other causes such as oncological resection.^[9] In such situations, for cranioplasty with expensive industrial prosthetic implant would be the option. However, many patients belonging to low socio-economic group rather prefer to live a life with cranial defect rather than getting treated with these expensive prosthetic implants.^[10]

Keeping in mind to solve this problem, we thought to utilize our own affordable and easily available resources. We have been using the PMMA extensively in post procedural cranial posterior fossa surgery and anterior cervical discectomy which gets remolded intraoperatively. However, in large cranial defect intra-op remolding of bone cement to the needed shape of defect is clumsy and results would not be that satisfying. On the other hand, preparing the bone intra-operatively can lead to local tissue necrosis during as the hardening of PMMA is exothermic.^[11] Therefore, in such situation, where patient specific implant is needed, we thought to use customized PMMA implant. These implant would be very cheaper to our patient but would not compromise the quality needed for such implant. By using PMMA casting method, we obtained a cranial implant that fit well into the anatomical defect. Besides, this PMMA based implant provides enough protection to the delicate brain tissues, with the impact strength of 5.27kJ/m², the PMMA implant mimics the impact strength of normal cranial bone.

The use of computed assisted design and 3D printing technology has gained popularity in manufacturing patient-tailored implants.^[7] But in context to Nepal, this technology has a limited access due to the cost factor and technical difficulty. The UP Box 3D printer which we are using costs approximately US \$2000-US \$3000 and the software is open source, with 48 h to produce implant.^[10]

To the best of our knowledge, there is no report of computer designed customized cranioplasty implants in here where there is high incidence of road traffic accident induced head injuries resulting in decompressive craniectomies. By sharing our experience, we would like to create the spirit among the neurosurgeons that patient tailored implants can be made at affordable price with satisfactory result.

Also, this technique can be one of the good and options for patient with facio-maxillary defects aesthetically and economically with a customized 3D-printed PMMA implant and in future we will be working on it.

Conclusion

Craniectomy remains an important neurosurgical strategy for various pathologies. Optimal coverage of cranial defect is important for brain protection and cosmesis. These 3D-printed patient specific implant made from PMMA is highly awarding. This has proven to provide a sophisticated solution until new economical methods are established and will continue to serve its purpose in everyday health care.

Declaration of patient consent

The authors certify that they have obtained all appropriate patient consent forms. In the form the patient(s) has/have given his/her/their consent for his/her/their images and other clinical information to be reported in the journal. The patients understand that their names and initials will not be published and due efforts will be made to conceal their identity, but anonymity cannot be guaranteed.

Financial support and sponsorship

Nil.

Conflicts of interest

There are no conflicts of interest.

References

1. Pant B. Delivery of primary neurosurgical care in developing countries – Scope for mutual cooperation. *Neurol Med Chir (Tokyo)* 1996;36:326-9.
2. Roka YB. Neurosurgery in Eastern Nepal: The past, present and future and a near decade of personal experience. *Nep J Neurosci* 2017;14:1-2.
3. Tan ET, Ling JM, Dinesh SK. The feasibility of producing patient-specific acrylic cranioplasty implants with a low-cost 3D printer. *Journal of Neurosurgery* 2016;124:1531-7.
4. Rotaru H, Stan H, Florian IS, Schumacher R, Park YT, Kim SG, *et al.* Cranioplasty with custom-made implants: Analyzing the cases of 10 patients. *J Oral and Maxillofac Surg* 2012;70:e169-76.
5. De La Peña A, De La Peña-Brambila J, Pérez-De La Torre J, Ochoa M, Gallardo GJ. Low-cost customized cranioplasty using a 3D digital printing model: A case report. *3D Print Med* 2018;4:4.
6. Marchac D, Greensmith A. Long-term experience with methylmethacrylate cranioplasty in craniofacial surgery. *J Plas Reconstr Aesthet Surg* 2008;61:744-52.
7. Binhammer A, Jakubowski J, Antonyshyn O, Binhammer P. Comparative cost-effectiveness of cranioplasty implants. *Plast Surg (Oakv)* 2020;28:29-39.
8. Kim BJ, Hong KS, Park KJ, Park DH, Chung YG, Kang SH. Customized cranioplasty implants using three-dimensional printers and polymethyl-methacrylate casting. *J Korean Neurosurg Soc* 2012;52:541-6.
9. Staffa G, Barbanera A, Faiola A, Fricia M, Limoni P, Mottaran R, *et al.* Custom made bioceramic implants in complex and large cranial reconstruction: A two-year follow-up. *J Craniomaxillofac Surg* 2012;40:e65-70.
10. Morales-Gómez JA, Garcia-Estrada E, Leos-Bortoni JE, Delgado-Brito M, Flores-Huerta LE, De La Cruz-Arriaga AA, *et al.* Cranioplasty with a low-cost customized polymethylmethacrylate implant using a desktop 3D printer. *J Neurosurg* 2019;130:1721-7.
11. Chamo D, Msallem B, Sharma N, Aghlmandi S, Kunz C, Thieringer FM. Accuracy assessment of molded, patient-specific polymethylmethacrylate craniofacial implants compared to their 3D printed originals. *Journal of Clinical Medicine* 2020;9:832.