

Asymptomatic Brain Abscess Following Decompressive Craniotomy for Stroke – A Report of Two Cases and Review of the Literature

Abstract

Stroke is a significant health problem in both developed and developing nations. The treatment strategies of stroke differ among various centers depending on the available expertise. Nevertheless, stroke contributes to a major economic burden for patients and health institutions. The recovery period after stroke is a critical period wherein various complications can develop in survivors. Among these multiple complications, the formation of brain abscess in the infarcted brain tissue is rare and less well described in the literature. Fever or signs of raised intracranial pressure are the usual manifestation of poststroke brain abscess. We present two unique cases of large brain abscess in patients who survived a malignant stroke. Both the patients were recuperating well after decompressive craniectomy for stroke without any signs of intracranial infection or raised intracranial pressure. Both the patients underwent open drainage of brain abscess, followed by delayed cranioplasty. There are only a few cases of brain abscess reported in the literature in patients who underwent decompressive craniectomy for stroke.

Keywords: Brain abscess, cerebral infarction, decompressive craniectomy

**Raja K. Kutty,
Sunilkumar
Balakrishnan
Sreemathyamma,
Jyothish Laila
Sivanandapanicker,
Abhishek Vijayan,
Prasanth Asher,
Anilkumar
Peethambaran**

*Department of Neurosurgery,
Government Medical College,
Thiruvananthapuram, Kerala,
India*

Introduction

Stroke is the second leading cause of mortality in the world after coronary artery disease. The global burden of stroke has risen substantially in the past two decades, especially in low and middle-income countries.^[1] The outcome of malignant stroke in general is poor. Due to the recent trend of decompressive craniectomy, there has been an increase in the number of survivors at the cost of higher morbidity.^[2] There have been many complications described as a sequela to stroke. Brain abscess is a rare complication which is less described among survivors of stroke. The usual presentation of brain abscess following stroke is due to symptoms of raised intracranial pressure. In this report, we describe two cases of malignant stroke in young patients who survived with decompressive hemispherectomy. They were found to have a large brain abscess at the site of the previously infarcted region, which was detected incidentally at the time of cranioplasty. We discuss the management strategies along with a brief review of the literature of brain abscess following decompressive craniectomy for stroke.

This is an open access journal, and articles are distributed under the terms of the Creative Commons Attribution-NonCommercial-ShareAlike 4.0 License, which allows others to remix, tweak, and build upon the work non-commercially, as long as appropriate credit is given and the new creations are licensed under the identical terms.

For reprints contact: WKHLRPMedknow_reprints@wolterskluwer.com

Case Reports

Case 1

A 35-year-old male presented to the emergency department with a history of sudden onset of headache and vomiting. His symptoms progressed the next day during which he noticed weakness of right side of the body and difficulty in speech. He was referred to our tertiary unit after 2 days of illness. His Glasgow Coma Scale (GCS) at admission was E4V1M5 with Grade 0 power in the right upper and lower limb along with brisk reflexes and a positive Babinski's sign. The National Institutes of Health Stroke Scale score was 25. An emergency computed tomography (CT) brain was done, which showed mild hypodensity in the region of the left middle cerebral artery territory. His routine investigations revealed that he had diabetes mellitus and also high packed cell volume values, possibly due to dehydration. A diagnosis of middle cerebral artery infarct was made after which he was started on heparin infusion. After 1 day, he deteriorated

How to cite this article: Kutty RK, Sreemathyamma SB, Sivanandapanicker JL, Vijayan A, Asher P, Peethambaran A. Asymptomatic brain abscess following decompressive craniotomy for stroke – A report of two cases and review of the literature. *Asian J Neurosurg* 2020;15:781-5.

Submitted: 09-Feb-2020 **Revised:** 07-Apr-2020
Accepted: 29-Apr-2020 **Published:** 28-Aug-2020

Address for correspondence:

*Dr. Raja K. Kutty,
Department of Neurosurgery,
Government Medical College,
Thiruvananthapuram - 695 011,
Kerala, India.
E-mail: drrajakutty@gmail.com*

Access this article online

Website: www.asianjns.org

DOI: 10.4103/ajns.AJNS_51_20

Quick Response Code:



in his consciousness with a GCS of E2V1M5 with mild pupillary asymmetry. A repeat CT scan showed that there was a large infarct in the area supplied by the left middle cerebral artery with a midline shift of 7 mm [Figure 1a]. A decision to do a decompressive hemicraniectomy was made at this point. A large fronto-temporo-parietal flap was raised, and the underlying bone was removed during the surgery. The dura was opened. We do not breach the pia for decompressive hemicraniectomy for stroke. A sizeable synthetic dural graft, G-Patch (Surgiwear Inc.) was placed over the brain, and skin was closed in layers. The resected large piece of the bone flap was placed in the subcutaneous pouch created in the abdomen.

Postoperative period and follow-up

The patient was mechanically ventilated and gradually extubated after 2 days. His consciousness improved to preoperative status. Postoperative CT showed an excellent decompression of the infarcted area and adequate room for the edematous brain [Figure 1b]. He had a moderate-to-severe chest infection complicating his recovery period for which he was treated with appropriate antibiotics. During the same period, he developed gradual swelling of his right lower limb. A Doppler study revealed deep vein thrombosis involving common femoral and popliteal veins. He was continued on heparin infusion along with warfarin. He recovered well over 1 month and at discharge with advice to continue with warfarin and insulin. At discharge, he was E4VAM5 with right hemiplegia.

Readmission and surgery

He reported to us for cranioplasty after 6 months. There was no history of fever during any time of follow-up. He was E4VAM5 with Grade 1 power in his right upper and lower limb. According to bystanders, he had improved well over the previous 6 months. A CT brain was taken before cranioplasty, which showed a large hypodense ring-enhancing lesion in the region of previous

infarct [Figure 2a and b]. A diagnosis of possible brain abscess was arrived at, and cranioplasty was deferred. All routine blood investigations including culture were sent to detect any signs of infection, but they were normal. His blood sugar values were within control as he was on insulin. He underwent open surgery for the draining of brain abscess. After skin incision the synthetic dura was excised completely. The abscess cavity was opened, and around 20 ml of pus was let out and send for cultures and bacteriology. The capsule of the brain abscess was excised as much as possible leaving a part of it on the medial side adjacent to the ventricle. This was done as we did not want to contaminate the ventricles. The abscess cavity was washed with gentamicin solution, and the brain was covered with a large fascia lata graft harvested from the left thigh and skin closed in layers.

Follow-up after the second surgery

The patient recovered well from the operation. The results of the culture of pus, as well as the dural prosthesis, were sterile. He was given intravenous imipenem and vancomycin for 4 weeks with advice to continue oral antibiotics for 2 weeks at home. He was advised to continue physiotherapy at home. He was on regular follow-up in the outpatient department. At 6 months, his power in the limbs had improved to Grade 3. At 1 year, CT scan was done, which showed resolution of abscess after which he underwent cranioplasty with autologous bone flap [Figure 3]. He is on regular follow-up for 2 years, and there are no signs of raised intracranial pressure or intracranial infections. He is fully conscious and has right hemiplegia and aphasia.

Case 2

A 26-year-old male had a sudden onset of headache and altered sensorium. He was brought into the emergency department and found to be delirious. On examination, he was febrile, and GCS was 10/15. Both pupils were bilateral sluggishly reacting. He had right hemiplegia. He was a known case of congenital heart disease, for

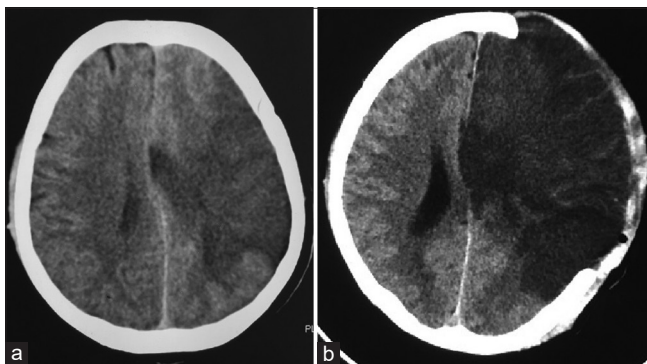


Figure 1: Computed tomography brain plain. (a) Large hypodensity in the left middle cerebral artery territory with mass effect on the lateral ventricle and midline shift to the right. (b) Postoperative image after decompressive craniectomy showing adequate decompression of the left cerebral hemisphere

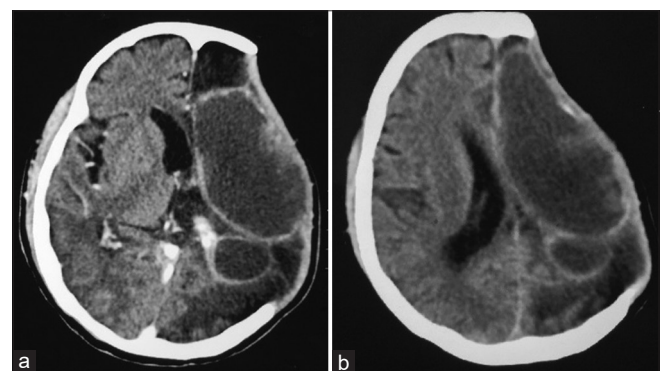


Figure 2: (a and b) Computed tomography brain plain showing ring-enhancing lesions in the left frontoparietal region with central hypodensity. Note the absence of any mass effect in spite of the large size of the lesion

which he had undergone surgery in childhood. All blood investigations including culture were sent. He tested positive for immunoglobulin M *Brucella* antibody suggesting brucellosis. However, blood culture did not grow any organism including *Brucella*. He was also found to have concomitant endocarditis. An emergent CT scan was taken, which showed a left-sided middle cerebral artery infarct with mass effect and midline shift of 10 mm [Figure 4a and b]. The need for emergency surgery was discussed with the bystanders, after which he underwent left fronto-temporo-parietal decompressive craniectomy. The bone flap was kept in the abdomen. Postoperatively, his consciousness improved. He recovered well but was aphasic and was discharged after 2 weeks with a GCS of E4VAM5. After 2 weeks, he turned up for a follow-up. He was fully conscious, had expressive aphasia, but was wheelchair-bound. He was asked to continue doxycycline for *Brucella*, as advised by the general medicine department.

After 4 months, he was readmitted to the neurosurgery department for cranioplasty. He had no worsening of consciousness or weakness of limbs during this period. He underwent a routine preoperative CT scan, which showed a large loculated hypodense collection in the infarcted area of the brain [Figure 5a and b]. After arriving at a diagnosis of postdecompressive craniectomy brain abscess, he underwent surgery for the excision of brain abscess. At surgery, the cavity was aspirated, which yielded around 25 ml of pus. The abscess, along with the fibrous capsule, was excised in toto. The pus which was sent for culture turned out to be sterile. He recovered well after the surgery. The postoperative CT scan showed the total excision of the abscess [Figure 6a and b]. Two months after the excision of brain abscess, he was called up for cranioplasty. He underwent a cranioplasty with the autologous bone flap 2 months after the second surgery. He recovered well after cranioplasty, and a postoperative CT scan was taken, which was uneventful [Figure 6c and d]. At the last follow-up, he had partial recovery of his speech and was fully conscious with a GCS of E4V4M6. A summary of both cases is detailed in Table 1.

Discussion

The occurrence of brain abscess following stroke was less well recognized until number of case reports surfaced in recent years in this regard. A thorough search on popular medical search engine PubMed and Google Scholar using the Boolean terms, “Stroke” AND “Complications” AND “Brain abscess” yielded only 19 case reports where a similar association was described.^[3-21] Among them, four reports were excluded in this review because only abstracts were available in English.^[3,4,14,17] Of the remaining 15 cases reported so far, only two patients had abscess following a decompressive craniectomy for stroke.^[13,18] In both reports, the patients were symptomatic

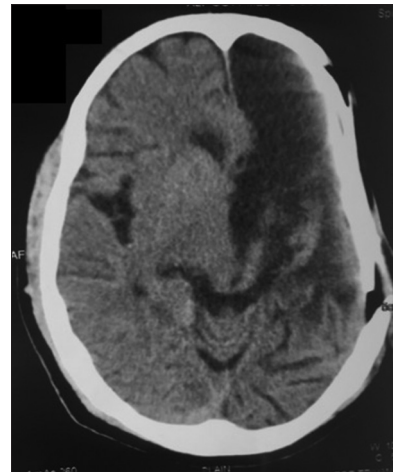


Figure 3: Computed tomography brain plain – Postcranioplasty after 1 year showing no residual abscess

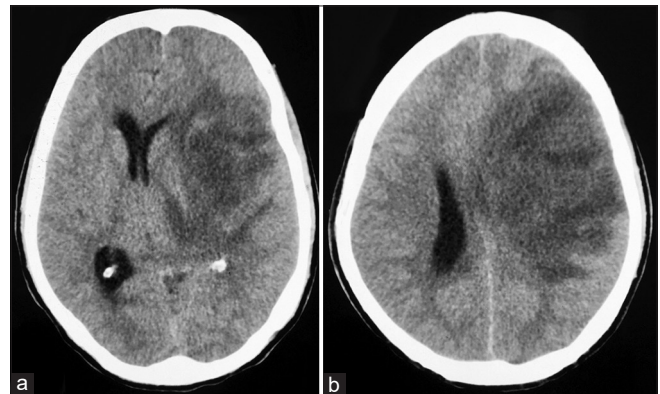


Figure 4: Computed tomography brain plain (a and b) – Acute infarct in the left frontal-temporal and parietal region with mass effect on the lateral ventricles and midline shift toward the right side

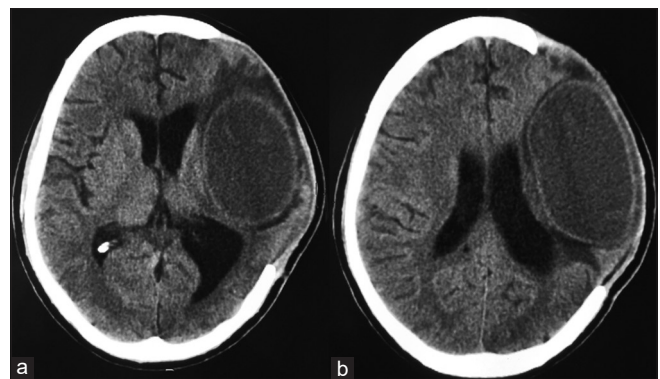


Figure 5: Computed tomography brain plain (a and b) – A well-defined oval-shaped hypodensity (suggestive of brain abscess). Occupying the left fronto-temporo-parietal region. The decompressive bone defect is also visualized

with respect to the secondary brain abscess, but in our case both the patients were relatively asymptomatic. The condition of both had very much improved over time from the initial surgery for stroke to the development of an abscess. Our report hence emphasizes the role of routine CT in the recovery period after decompressive

craniectomy following ischemic stroke. This can detect such silent abscesses and prompt early intervention. Following the universal dictum that abscess anywhere in the body has to be drained, we decided that the best option is to go ahead with surgery and drainage of the abscess. During surgery, we had instilled gentamycin solution to wash the abscess cavity. This was done to decrease the antibacterial load within the remaining abscess cavity. Such practices have been recommended by many authors in the literature.^[22-24] Furthermore, it was decided that the antibiotics needed to be stepped in view of high incidences of organisms not being discovered in routine cultures in our experience. Such sterile abscess form up to 40% of large series of brain abscess reported in the

literature.^[25] Brain abscess after stroke has been seen to occur mostly in the elderly population,^[3-6,9-12,15,18,21] with only a few cases reported in the younger age group.^[7,8,11,18] The combination of immunocompromised states such as surgery, diabetes, and advanced age may have played a role in the development of brain abscess in the setting of stroke. Although both our patients were young, the former was a diabetic. This, along with surgery, might have been a predisposing factor for developing an intracranial infection in him. Our second patient was a case of congenital heart disease and had *Brucella* meningitis and endocarditis. Neurobrucellosis has known to cause cerebral infarction^[26,27] as well as brain abscess.^[28-30] In addition, it has been reported that the central nervous system itself is an immunodepressive state after stroke which predisposes patients to various infection.^[31-33] The pathogen responsible for abscess after stroke has been mostly due to *Staphylococcus* spp. However, there have been instances where rare organisms^[5,9,18] or negative cultures^[6,11,12,18] have been reported.

The time for the development of brain abscess following stroke varies in the literature from as early as few weeks,^[6-8,11-13,18] months,^[9,15,18,21] or even an year.^[10] In our patients, the exact time for the development of abscess is not known since imaging was not repeated after initial discharge to the time of readmission for cranioplasty. Overall, the prognosis of the development of abscess following ischemic stroke is poor. Death or recovery with neurological deficit predominates the literature review of this condition. In the review by Ramesh *et al.* which included 19 cases of brain abscess following stroke, there were five deaths and four partial recoveries of neurological status.^[21] The early surgical intervention followed by appropriate antibiotics will decrease the mortality associated with this condition.

Conclusion

Brain abscess following DC for stroke is rare. The symptoms and signs are usually masked by the accommodative nature of the decompressed brain. A routine CT scan should be considered in all patients undergoing cranioplasty before

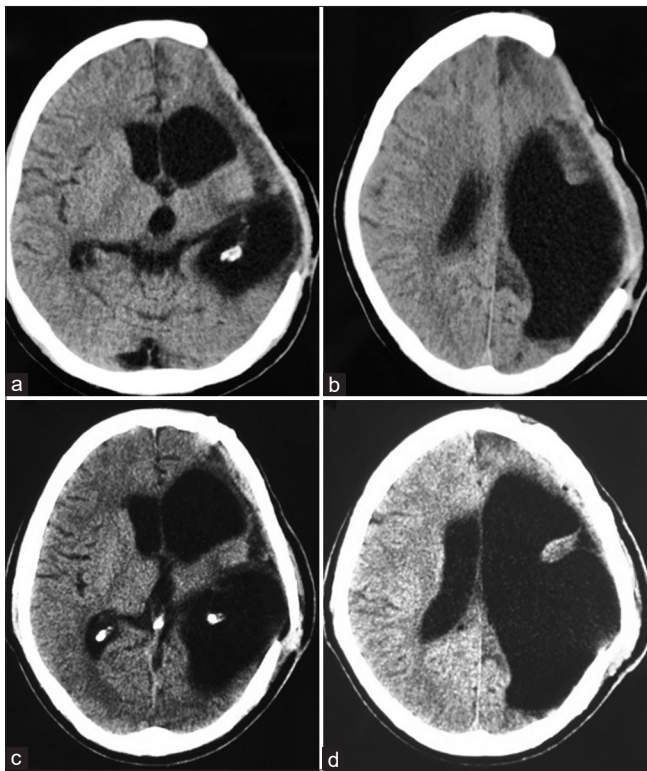


Figure 6: Computed tomography brain plain (a and b) – Postbrain abscess excision shows total excision of the abscess. There is *ex vacuo* dilatation of the ventricular system on the left side. (c and d) – Postcranioplasty computed tomography brain

Table 1: Summary of cases of brain abscess

Age (in years)	Sex	Past medical history	Stroke territory	Time to presentation of brain abscess (months)	Symptoms	Source of infection	Treatment	Pathogen	Outcome
35	Male	NIL	MCA infarct	6	Nil	Blood borne secondary to chest infection	Surgical excision + antibiotics	No growth obtained on Culture medium	Good
26	Male	Congenital heart disease	MCA infarct	4	Nil	<i>Brucella</i> endocarditis	Surgical excision + antibiotics	Possible <i>Brucella melitensis</i>	Good

MCA – Middle cerebral artery

the procedure. Surgical excision followed by interval cranioplasty should be done in all cases.

Declaration of patient consent

The authors certify that they have obtained all appropriate patient consent forms. In the form, the patients have given their consent for their images and other clinical information to be reported in the journal. The patients understand that their names and initials will not be published and due efforts will be made to conceal their identity, but anonymity cannot be guaranteed.

Financial support and sponsorship

Nil.

Conflicts of interest

There are no conflicts of interest.

References

- Kamalakkannan S, Gudlavaleti SV, Gudlavaleti MS, Goenka S, Kuper H. Incidence and prevalence of Stroke in India: A systemic review. *Indian J Med Res* 2017;146:175-85.
- Back L, Nagaraja V, Kapur A, Eslick GD. Role of decompressive hemicraniectomy in extensive middle cerebral artery strokes: A meta-analysis of randomised trials. *Intern Med J* 2015;45:711-7.
- Amonn F, Müller U. Brain abscess – A possible complication of cerebral infarction? *Schweiz Med Wochenschr* 1984;114:58-62.
- Ichimi K, Ishiguri H, Kida Y, Kinomoto T. Brain abscess following cerebral infarction: A case report. *No Shinkei Geka* 1989;17:381-5.
- Arentoft H, Schönheyder H, Schönemann NK. Cerebral *Salmonella typhimurium* abscess in a patient with a stroke. *Infection* 1993;21:251-3.
- Chen ST, Tang LM, Ro LS. Brain abscess as a complication of stroke. *Stroke* 1995;26:696-8.
- Davenport RJ, Gibson R, Mumford CJ, Will RG. Brain abscess complicating ischemic stroke. *Stroke* 1995;26:1501-3.
- Shintani S, Tsuruoka S, Koumo Y, Shiigai T. Sudden “stroke-like” onset of homonymous hemianopsia due to bacterial brain abscess. *J Neurol Sci* 1996;143:190-4.
- Beloosesky Y, Streifler JY, Eynan N, Grinblat J. Brain abscess complicating cerebral infarct. *Age Ageing* 2002;31:477-80.
- Miyazaki H, Ito S, Nitta Y, Iino N, Shiokawa Y. Brain abscess following cerebral infarction. *Acta Neurochir (Wien)* 2004;146:531-2.
- Kaplan M, Ozveren MF, Erol FS, Kaplan S, Bilge T. Brain abscess developing at the site of preceding Stroke – Report of three cases: Review of literature. *Neurosurg Q* 2005;15:17-20.
- Emmez H, Börcek AO, Dođulu F, Ceviker N. Ischemic stroke complicated by a brain abscess: A case report and review of the literature. *Turk Neurosurg* 2007;17:48-54.
- Kraemer JL, Worm PV, Faria MD, Maulaz A. Brain abscess following ischemic stroke with secondary haemorrhage. *Arq NeuroPsiquiatri* 2008;66:104-6.
- Jung SH. Brain abscess developed on the lesion site of previous ischemic stroke. *J Korean Neurol Assoc* 2010;28:33-5.
- Yamanaka K, Ishihara M, Nakajima S, Yamasaki M, Yoshimine T. Brain abscess following intra-arterial thrombolytic treatment for acute brain ischemia. *J Clin Neurosci* 2011;18:968-70.
- Albrecht P, Stettner M, Husseini L, Macht S, Jander S, Mackenzie C, *et al.* An emboligenic pulmonary abscess leading to ischemic stroke and secondary brain abscess. *BMC Neurol* 2012;12:133.
- García-Cid N, Pérez-Rodríguez MT, Argibay-Filgueira A, Martínez-Vázquez C. Absceso cerebral sobre infarto isquémico previo. *Enferm Infecc Microbiol Clin* 2014;32:60-1.
- Wang J, Fraser JF. An Intracranial Petri Dish? Formation of Abscess in Prior Large Stroke After Decompressive Hemicraniectomy. *World Neurosurg* 2015;84:1495.e5-9.
- Noro F, de Melo AS, dos Santos Marchiori E. Brain infarct and abscess – A very common disease and a rare association. *World Neurosurg* 2016;93:476.
- Guenego A, Rafiq M, Michelozzi C, Januel AC, Albuher JF, Sol JC, *et al.* Secondary cerebral abscess of an ischemic stroke treated by thrombectomy. *J Neuroradiol* 2017;44:403-6.
- Ramesh R, Wenderoth J, Katrak P. Intracerebral abscess as a delayed sequela of ischemic stroke: Case report and brief review of the literature. *J Neurol Disord Stroke* 2017;5:1118.
- Longatti P, Perin A, Ettorre F, Fiorindi A, Baratto V. Endoscopic treatment of brain abscesses. *Childs Nerv Syst* 2006;22:1447-50.
- Yu X, Liu R, Wang Y, Zhao H, Chen J, Zhang J, *et al.* CONSORT: May stereotactic intracavity administration of antibiotics shorten the course of systemic antibiotic therapy for brain abscesses? *Medicine (Baltimore)* 2017;96:e6359.
- Hellwig D, Bauer BL, Dauch WA. Endoscopic stereotactic treatment of brain abscesses. *Acta Neurochir Suppl* 1994;61:102-5.
- Menon S, Bharadwaj R, Chowdhary A, Kaundinya DV, Palande DA. Current epidemiology of intracranial abscesses: A prospective 5 year study. *J Med Microbiol* 2008;57:1259-68.
- Ay S, Tur BS, Kutlay S. Cerebral infarct due to meningovascular neurobrucellosis: A case report. *Int J Infect Dis* 2010;14 Suppl 3:e202-4.
- Gul HC, Erdem H, Bek S. Overview of neurobrucellosis: A pooled analysis of 187 cases. *Int J Infect Dis* 2009;13:e339-43.
- Gündeş S, Erdenliđ S, Meriç M, Koç K, Willke A. A case of intracranial abscess due to *Brucella melitensis* [4]. *Int J Infect Dis* 2004;8:379-81.
- Rajchanuwong C, Baiocchi P, Berardelli A, Venditti M, Pietro M. A case of brain abscess due to *bruceila melitensis*. *Clin Infect Dis* 1994;19:977-8.
- Demirođlu YZ, Turunç T, Karaca S, Arlier Z, Alışkan H, Colakođlu S, *et al.* Neurological involvement in brucellosis: clinical classification, treatment and results. *Mikrobiyol Bul.* 2011;45:401-10.
- Chamorro A, Urra X, Planas AM. Infection after acute ischemic stroke: A manifestation of brain-induced immunodepression. *Stroke* 2007;38:1097-103.
- Kamel H, Iadecola C. Brain-immune interactions and ischemic stroke: Clinical implications. *Arch Neurol* 2012;69:576-81.
- Shim R, Wong CH. Ischemia, immunosuppression and infection – Tackling the predicaments of post-stroke complications. *Int J Mol Sci* 2016;17. pii: E64.