

Intradural Disc a Diagnostic Dilemma: Case Series and Review of Literature

Abstract

Introduction: We present a case series of six cases of intradural disc herniation at L4–L5 level diagnosed on the basis of intraoperative findings. **Result:** All our cases, on preoperative magnetic resonance imaging (MRI) were reported as having diffuse annular bulge with large posterocentral extrusion. Our study comprised patients in age group of 30–60 years. Four cases out of six presented with cauda equina syndrome. In three cases, cauda equina was associated with sudden deterioration in the power of lower limb muscle groups. **Discussion:** We suspect that intradural herniation of disc was synchronous with cauda equina syndrome in these cases, which was very well documented in one of the cases. On retrospective analysis, MRI findings of mass effect in the form of displacement of the traversing nerve roots due to large central disc with crumble disc sign were suggestive of early evidence of intradural disc herniation. Y sign in ventral dura due to splitting of ventral dura and arachnoid mater by disc material was a good diagnostic sign to suspect intradural extra-arachnoid disc. The presence of hypointense structure inside the dura with no continuity with the adjacent intervertebral disc on MRI was highly suggestive of an intradural disc. **Conclusion:** Intradural disc prolapse remains a diagnostic dilemma as it is very difficult to diagnose all the cases preoperatively. The presence of above-mentioned radiological signs on MRI in patients having the large central disc on MRI, especially at L4–L5 levels, should raise suspicion of intradural herniation of disc.

Keywords: *Cauda equina, intradural disc, lumbar herniated disc*

Introduction

Intradural disc is a rare presentation of intervertebral disc herniation with an incidence of 0.26%–0.30% of all herniated discs. The majority of the intradural disc have been reported in the lumbar spine (92%) and most common level reported is L4–L5 disc space.^[1,2] Intradural disc clinically present with high incidence of neurological deficit and cauda equina syndrome compared to extradural disc herniation.^[3] Pathology of intradural disc is still elusive but studies suggest that probably due to firm anatomic adhesions between the anterior wall of the dural sac and the posterior longitudinal ligament (PLL), at the L4–L5 level in cases of dural perforation, the herniated disc perforates the annulus fibrosis, PLL, and the dura mater simultaneously at this level.^[4] Magnetic resonance imaging (MRI) is the most common diagnostic tool in management of disc prolapse. Various MRI signs have been described in literature to suspect intradural disc-like “hawk-beak”

sign in axial T2 image, which is seen as a sharp compressing lesion with a beak-like appearance to the dural sac on T2-weighted axial images and Y sign in which division of dura and arachnoid appears as “Y” seen in intradural extra-arachnoid disc herniation as the arachnoid is peeled off from the dura by the disc herniation.^[5-7] Most of these findings are nonspecific and may not be observed in all cases. Contrast-enhanced MRI may be useful to diagnose intradural disc, but is not a part of routine investigation in diagnosis of lumbar disc pathology.^[8,9] Hence, in spite of advancement in diagnostic technique intradural disc remains a diagnostic dilemma and most of them are diagnosed intraoperatively. The aim of our study was to look for preoperative clinical and radiological features suggestive of intradural disc.

Case Report

We present six cases of intradural disc which were reported on preoperative MRI as diffuse annular bulge with large posterocentral extrusion at L4–L5 compressing over the intrathecal nerve

**Ayush Sharma,
Vijay Singh,
Gururaj
Sangondimath¹,
Prashant Kamble²**

*Department of Orthopedic and Spine Surgery,
Dr B R Ambedkar Central Railway Hospital, ²Department of Orthopedic, King Edward Memorial Hospital, Mumbai, ¹Indian Spinal Injuries Center, New Delhi, India*

Address for correspondence:

*Dr. Ayush Sharma,
Doctor's Quarter No 6,
Dr B R Ambedkar Central Railway Hospital, Byculla East, Mumbai, Maharashtra, India.
E-mail: drayush@gmail.com*

Video Available on:
www.asianjns.org

Access this article online

Website: www.asianjns.org

DOI: 10.4103/ajns.AJNS_55_17

Quick Response Code:



How to cite this article: Sharma A, Singh V, Sangondimath G, Kamble P. Intradural disc a diagnostic dilemma: Case series and review of literature. *Asian J Neurosurg* 2018;13:1033-6.

This is an open access journal, and articles are distributed under the terms of the Creative Commons Attribution-NonCommercial-ShareAlike 4.0 License, which allows others to remix, tweak, and build upon the work non-commercially, as long as appropriate credit is given and the new creations are licensed under the identical terms.

For reprints contact: reprints@medknow.com

roots with their relevant clinical, intraoperative findings, and MRI analysis. The patients have given the necessary consent for the case reports to be published. No Institutional Review Board approval was required for the study.

Case 1–51 years male presented with pain in the region of lumbar spine with bilateral lower limb radiculopathy for 1 month. On clinical examination, he had weakness and sensory deficit in muscles supplied by L5, S1 dermatomes with power 4/5. MRI was reported as diffuse annular bulge with large posterocentral extrusion at L4–L5. Patient was planned for discectomy but patient refused consent for surgical intervention. Patient revisited hospital after 2 days complaining of severe back pain. On examination, motor power had deteriorated to 1/5 with saddle anesthesia and bladder and bowel involvement, which was documented as loss of perianal sensation and voluntary anal contraction. Patient was planned for L4–L5 discectomy on an emergency basis and intraoperative three disc fragments measuring 2 cm × 1.5 cm, 2 cm × 1 cm and 3 cm × 1 cm were found inside dura without much intradural adhesions. Postoperatively, patient had complete recovery of bladder and bowel controls at 1-month follow-up and his motor power improved to 4/5 after 3 months. Retrospectively, the MRI was carefully reanalyzed, and we observed focal discontinuity of the PLL and the anterior thecal sac at the level of the superior end plate of the L5 vertebral body. With the presence of early signs of intradural herniation of the L4–L5 disc, which was causing mass effect in the form of displacement of the traversing nerve roots. Typical crumble appearance of disc documented as “crumble disc sign” was also observed in the herniated disc [Figure 1a-c].

Case 2–49 years male presented with low back pain for 1 month with sudden worsening of pain for 2 days. On

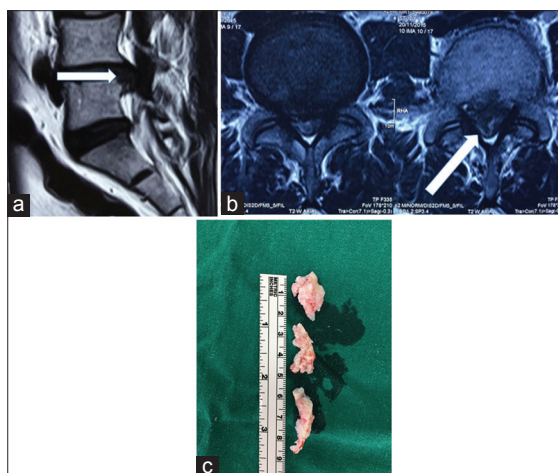


Figure 1: (a) Magnetic resonance imaging sagittal T2-weighted image showing focal discontinuity of the posterior longitudinal ligament and the anterior thecal sac at the level of the superior end plate of the L5 vertebral body. (b) Magnetic resonance imaging axial image showing herniation of the L4–L5 disc causing mass effect in the form of displacement of the traversing nerve roots. The herniated disc exhibits the typical “crumble disc sign.” (c) Three large disc fragments removed after discectomy of L4–5 dura

clinical examination, patient had weakness with power 3/5 bilateral L5 myotomes with cauda equina syndrome. MRI was reported as diffuse annular bulge with large posterocentral extrusion at L4–L5. Patient was planned for L4–L5 discectomy on an emergency basis and intraoperatively a single large disc fragment was removed from the dura. No intradural adhesions were observed around the disc. Postoperatively, patient had immediate relief of symptoms and complete recovery of motor power at 1-month follow-up. Retrospectively, MRI analysis only revealed a large central disc at L4–L5, which was seen effacing the anterior thecal sac, indenting the traversing nerve roots as in this case the MRI was performed 23 days before surgery.

Case 3–33 years male presented with back pain for 15 days, with difficulty in walking for 2 days. Clinical examination revealed bilateral foot drop with saddle anesthesia and bladder and bowel involvement. MRI was reported as diffuse annular bulge with large posterocentral extrusion at L4–L5. Patient was planned for L4–L5 discectomy. Intraoperatively, L4–L5 disc herniation was documented and part of the disc was found to be intradural. Postoperatively, patient had good pain relief and recovery of bladder and bowel symptoms at 1-month follow-up but his foot drop did not improve even at 6 months. Retrospective MRI reanalysis suggested L4–L5 disc prolapse with partial extension of prolapsed disc into the intradural space.

Case 4–45 years male presented with back pain and left lower limb radiculopathy for 2 months. Clinical examination revealed motor weakness 4/5 in L5 and S1 myotomes in left lower limb. MRI was reported as diffuse annular bulge at L4–L5 compressing right more than left L5 nerve root. Patient was planned for L4–L5 discectomy. Intraoperative intradural disc was found firmly adherent to anterior thecal sac and nerve roots with no continuity noted with adjacent L4–L5 intervertebral disc. Multiple small disc fragments were carefully dissected with the largest one measuring 0.7 cm × 0.5 cm. Postoperatively, patient had significant relief of symptoms and complete neurological recovery at 1-month follow-up. Retrospective reanalysis of MRI confirmed presence of well-defined, intradural disc causing secondary soft tissue spinal canal stenosis and displacing the adjacent traversing nerve roots [Figure 2a-c].

Case 5–30-year-old female presented with radicular pain in both lower limbs for 2 years with increased symptoms for 2 months associated with urinary incontinence. Clinical examination revealed motor weakness 4/5 in L5 and S1 myotomes in bilateral lower limb with perianal hypoesthesia. MRI was reported as diffuse annular bulge with large posterocentral extrusion at L4–L5. Patient was planned for L4–L5 discectomy. Intraoperative adherent intradural disc material was carefully dissected from adjacent rootlets and dura. Postoperatively, patient had improvement in her symptoms but motor strength and

urinary incontinence did not improve. On retrospective reanalysis of MRI abnormal hypointense intradural structure was noted at level of L5 [Figure 3].

Case 6–59 years male presented with bilateral lower limb radiculopathy for 3 months. Clinical examination revealed only sensory deficit in bilateral L5 dermatomes with no associated motor deficit. MRI was reported as diffuse annular bulge at L4–L5. Patient was planned for L4–L5 discectomy. Intraoperatively, extruded disc fragments were carefully dissected from L4–L5 intradural space and no continuity were noted with adjacent L4–L5 intervertebral disc. Postoperatively, patient had complete recovery in his symptoms and was able to return to his routine daily activity at 1-month follow-up. Retrospective reanalysis of MRI suggested well-defined round intradural extra-arachnoid disc on axial images. A hypointense structure was observed at L5 vertebral level splitting the ventral dura and arachnoid mater (Y sign) confirming an intradural extra-arachnoid disc [Figure 4].

Surgical technique

In all the cases, similar surgical procedure was performed after failure to identify the disc prolapse following a conventional microdiscectomy approach. An image intensifier was used to reconfirm the level of surgery. Once the level was reconfirmed partial L4–L5 laminectomy was done which revealed a highly tense dura. Gentle palpation on dura revealed a firm intradural structure. Under microscopic magnification posterior durectomy was done, nerve rootlets were carefully dissected from the intradural structure. All disc fragments were carefully dissected and removed [Video 1, Figure 5a-c]. Meticulous closure of posterior durectomy incision was achieved at the end of decompression. No postoperative cerebrospinal

fluid leaks were documented in our series. All intradural material obtained were sent to histological confirmation after surgery.

Discussion

We present six cases of intradural disc herniation at L4–L5 diagnosed on the basis of perioperative findings. All the cases in our series were in age group of 30–60 years. Among various case reports in literature intradural disc appears to be most commonly associated with this age group. D'Andrea *et al.*, in his series suggested higher mean patient's age of intradural disc when compared with extradural disc pathology.^[9] More than half of the intradural disc has been reported at L4–L5 level.^[9] While none of cases in our series had a history of previous spinal surgery or trauma, intradural herniation has been associated with previous surgery, and traumatic disk rupture.^[10] Four out of six cases in our series presented with cauda equina syndrome. Other case series have also reported high incidence cauda equina syndrome in cases of intradural disc.^[2] Three out of four cases of cauda equina in our series were associated with sudden deterioration in the power of lower limb muscle groups. We suspect that intradural herniation of disc was synchronous with cauda equina syndrome in these cases, which was very well documented in Case 1. In these patients, intraoperative finding of large and intact disc fragment in dura [Figure 1c], without any significant adhesion between disc and rootlets suggested acute nature of pathology. This could be the possible reason for cauda equine syndrome in these cases. Two cases that presented without cauda equina had longer duration of symptoms without any acute exaggeration of symptom or neurological deficit, which suggests slow and gradual migration of disc inside dura. Even the intradural disc material obtained in these cases were small and fragmented [Figure 2c] and had to be carefully dissected from rootlets due to adhesions suggesting chronic nature of pathology.

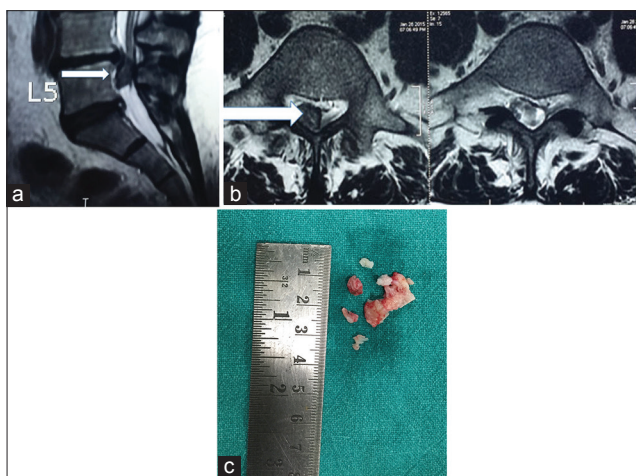


Figure 2: (a) Magnetic resonance imaging sagittal image - showing well defined, intradural, T2-weighted hypointense structure at the L4–L5 level with no continuity noted with the adjacent L4–L5 intervertebral disc. (b) Magnetic resonance imaging axial image showing well defined, intradural, T2-weighted hypointense structure at the L4–L5 level with no continuity noted with the adjacent L4–L5 intervertebral disc. (c) Multiple small disc fragments removed after durectomy of L4–5 dura

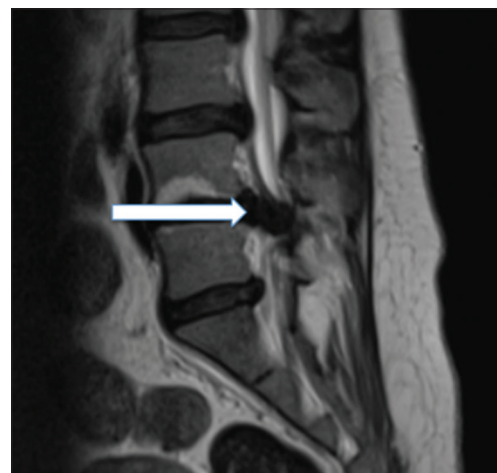

Figure 3: Magnetic resonance imaging showing abnormal hypointense intradural structure at level of L5

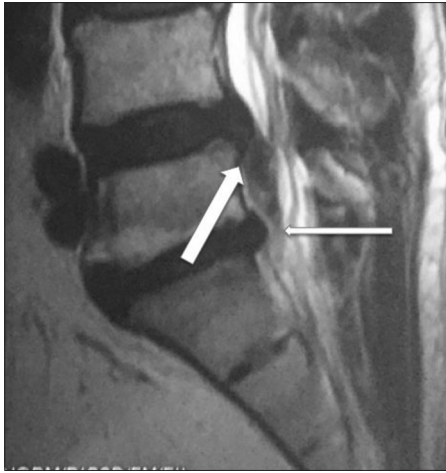

Figure 4: Magnetic resonance imaging sagittal image - showing hypointense structure at the L5 level seen splitting the ventral dura and the arachnoid mater (Y sign). It is seen indenting and displacing the adjacent traversing nerve roots causing significant secondary soft tissue spinal canal stenosis. There is no continuity noted with the adjacent L4-L5 intervertebral disc

Although none of the MRI findings were reported as intradural disc disease but on careful retrospective analysis of MRI records, we found evidence suggesting intradural nature of disc in five out of six cases. Only in Case 2, MRI showed effacement of the anterior thecal sac by a large voluminous L4–L5 disc. We suspect that to be the earliest evidence of a possible intradural disc herniation. MRI findings of mass effect in the form of displacement of the traversing nerve roots due to large central disc with crumble disc sign are early signs of intradural disc herniation as evident in Case 1. Y sign in ventral dura due to splitting of ventral dura and arachnoid mater by disc material is a good diagnostic sign to suspect intradural extra-arachnoid disc^[7] as documented in Case 5. A hypointense structure inside the dura with no continuity with the adjacent intervertebral disc on MRI is highly suggestive of intradural disc (Cases 4 and 5).

Conclusion

Intradural disc disease remains a diagnostic dilemma as it is very difficult to diagnose all the cases preoperatively. Sudden deterioration in the power of lower limb muscle groups with cauda equina syndrome in patients having large central disc on MRI, especially at L4–L5 levels, should raise the clinical suspicion of intradural herniation of disc. MRI findings of mass effect in the form of displacement of the traversing nerve roots due to large central disc with crumble disc sign suggest early evidence of intradural disc herniation. Hypointense structure inside the dura with no continuity with the adjacent intervertebral disc on MRI is highly suggestive of an intradural disc. Y sign in ventral dura due to splitting of ventral dura and arachnoid mater by disc material is a good diagnostic sign to suspect intradural extra-arachnoid disc. More cases of intradural disc herniation need to be

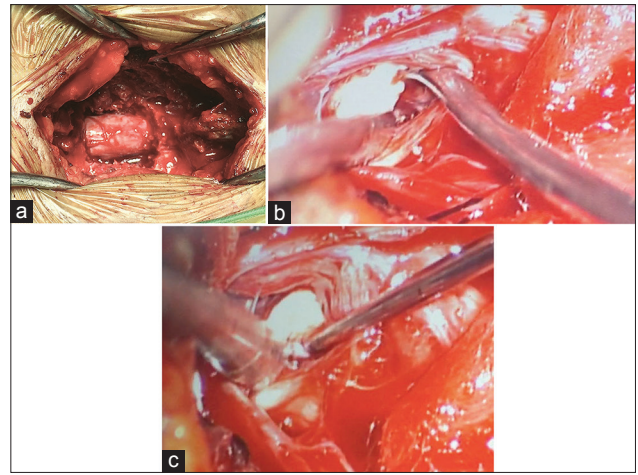


Figure 5: (a) Highly tense dura observed after an L4–L5 laminectomy. (b) Intraoperative images after posterior durectomy showing intradural disc under microscopic magnification. (c) Intraoperative images after posterior durectomy showing intradural disc under microscopic magnification

reported to document all the diagnostic features to solve this dilemma.

Financial support and sponsorship

Nil.

Conflicts of interest

There are no conflicts of interest.

References

- Negovetic L, Cerina V, Sajko T, Glavic Z. Intradural disc herniation at the T1-T2 level. *Croat Med J* 2001;42:193-5.
- Ducati LG, Silva MV, Brandão MM, Romero FR, Zanini MA. Intradural lumbar disc herniation: Report of five cases with literature review. *Eur Spine J* 2013;22:1436.
- Lee JS, Suh KT. Intradural disc herniation at L5-S1 mimicking an intradural extramedullary spinal tumor: A case report. *J Korean Med Sci* 2006;21:778-80.
- Yildizhan A, Pasaoglu A, Okten T, Ekinci N, Aycan K, Aral O. Intradural disc herniations pathogenesis, clinical picture, diagnosis and treatment. *Acta Neurochir (Wien)* 1991;110:160-5.
- Liu CC, Huang CT, Lin CM, Liu KN. Intradural disc herniation at L5 level mimicking an intradural spinal tumor. *Eur Spine J* 2011;20 Suppl 2:S326-9.
- Arrigo RT, Kalanithi P, Boakye M. Is cauda equina syndrome being treated within the recommended time frame? *Neurosurgery* 2011;68:1520-6.
- Sasaji T, Horaguchi K, Yamada N, Iwai K. The specific sagittal magnetic resonance imaging of intradural extra-arachnoid lumbar disc herniation. *Case Rep Med* 2012;2012:383451.
- Whittaker CK, Bernhardt M. Magnetic resonance imaging shows gadolinium enhancement of intradural herniated disc. *Spine Phila Pa* 1976 1994;19:1505-7.
- D'Andrea G, Trillò G, Roperto R, Celli P, Orlando ER, Ferrante L. Intradural lumbar disc herniations: The role of MRI in preoperative diagnosis and review of the literature. *Neurosurg Rev* 2004;27:75-80.
- Orakcioglu B, Dao Trong HP, Jungk C, Unterberg A. Against the odds: Massive lumbar intradural disk herniation in the elderly. *Global Spine J* 2015;5:e84-7.